

PVNS or pseudo aneurysm: MRI-problem solving or misleading?

Bhagya Sannanjanja, Hardik Uresh Shah, Varun Laxman¹, Chinmay Nagesh

Departments of Radiology, Shri Harilal Bhagwati Municipal Corporation Hospital, ¹Bharatratna Dr. Babasaheb Ambedkar Hospital, Mumbai, India

Correspondence: Dr.Bhagya Sannanjanja, Department of Radiology, Shri Harilal Bhagwati Municipal Corporation Hospital, Mumbai, India.
E-mail: drbhagyasanjanjappa@gmail.com

Abstract

Pigmented villonodular synovitis (PVNS) is a benign neoplastic process affecting the synovium. Magnetic resonance imaging (MRI) is considered as the imaging modality of choice, where PVNS is seen as a soft tissue lesion affecting the synovium with characteristic hypointense signal on T2-weighted images (T2WI) and typically blooming on gradient echo (GRE) sequences. MRI can sometimes be misleading, with many non-neoplastic pathologies having a tendency of recurrent bleeding closely mimicking PVNS. We report a case of pseudoaneurysm from posterior circumflex humeral artery, a branch of axillary artery, secondary to recurrent shoulder dislocation mimicking PVNS on MRI.

Key words: Dislocation; magnetic resonance imaging; pigmented villonodular synovitis; pseudoaneurysm

Introduction

Pigmented villonodular synovitis (PVNS) is a benign neoplastic condition characterized by either diffuse or focal proliferation of synovium in the joint, bursae, or tendon sheaths. MRI is considered as the investigative modality of choice. On MRI, the intraarticular variety of diffuse PVNS is seen as a soft tissue lesion of low signal intensity on T1-andT2-weighted sequences^[1]and typically blooming on gradient sequences due to hemosiderin deposition in them. Extrinsic bony erosions can be seen in joints with tight capsule.^[2]Hemophilic arthritis, synovial chondromatosis, synovial hemangioma, and amyloid arthropathy are a few conditions that mimic PVNS on imaging. We report an interesting case of posterior circumflex artery pseudoaneurysm secondary to recurrent shoulder dislocation, mimicking as shoulder joint PVNS on MRI.

Case Report

A 70-year-old male presented with slowly progressive pain in the right shoulder since 6 months. It began with an episode of shoulder dislocation after overhead weightlifting. The dislocation was treated by a local practitioner, following which the pain partially subsided. This was followed by two more episodes of dislocation, the last episode of which occurred 2 months back. Since 2 months, the pain was progressive even after reduction of dislocation. He also complained of swelling in the shoulder with restriction in the range of motion. On examination, there was tenderness and mild crepitus; the range of shoulder movement was restricted with abduction 60°, flexion 40°, extension 40°, and adduction 30°. Internal and external rotations were restricted and painful.

Frontal radiograph of the right shoulder joint showed soft tissue swelling around the joint with multiple well-defined erosions in the head and neck of the humerus.

MRI right shoulder (Philips Achieva 1.5 T A-series, DA Best, The Netherlands) showed lobulated soft tissue lesion around the shoulder joint with diffuse synovial proliferation. The soft tissue lesion and proliferated synovium had predominantly low signal intensity on T1-andT2-weighted spin echo (SE) sequences [Figure 1]. On proton density (PD) and short tau

Access this article online

Quick Response Code:



Website:
www.ijri.org

DOI:
10.4103/0971-3026.150152

inversion recovery (STIR) sequence, the signal intensity was intermediate to high. Few T1- and T2-hyperintense foci were also observed amidst this diffuse low signal. The lesions showed mild enhancement on the post-contrast T1-weighted fat-saturated sequences. Extrinsic erosions were seen in the head and neck of humerus with moderate joint effusion. Hill-Sachs lesion present on the posterolateral aspect of head of humerus was consistent with recurrent anterior dislocation. The patient was posted for arthroscopy with a provisional diagnosis of diffuse intraarticular PVNS.

Due to technical difficulty during anesthesia, patient was referred for USG-guided biopsy. On B mode, the synovium was markedly thickened and hypoechoic. There was moderate joint effusion with low-level internal echoes. A heterogeneous lobulated soft tissue lesion with a $1.8 \times 2\text{ cm}$ anechoic focus was seen in the inferior axillary pouch. Color Doppler (Toshiba™ 200, Tokyo, Japan) showed turbulent bidirectional flow within this anechoic focus suggestive of a pseudoaneurysm [Figure 2], which was communicating with a branch of axillary artery.

Computed tomography (CT) angiography (Toshiba Asteion

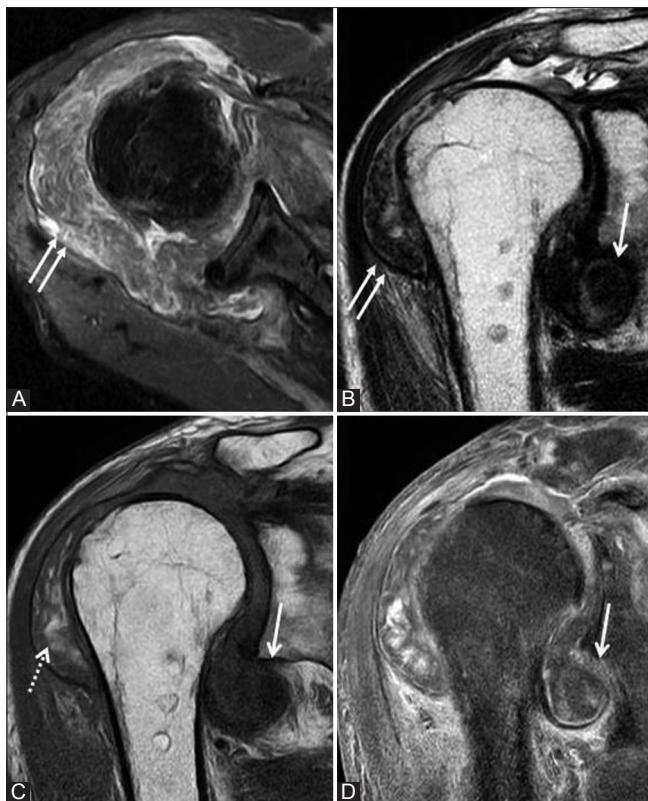

Figure 1 (A-D): (A) PD images show hyperintense signal in the thickened synovium (paired arrows). (B) T2WI spin echo coronal image shows hypointense and thickened synovium (paired arrows) with moderate joint effusion. (C) On T1WI, few foci of T1 shortening (interrupted arrow) are seen in the diffusely thickened synovium. (D) Post-contrast fat-saturated T1WI shows moderate enhancement in the soft tissue around the shoulder joint. The arrow points to signal void due to flow in patent aneurysmal sac which was misinterpreted initially

4 slice CT scanner, Tokyo, Japan). Showed communication of the pseudoaneurysm with the posterior circumflex branch of axillary artery [Figure 2]. A large hyperdense (80-110 HU) soft tissue lesion surrounded the patent aneurysmal sac (arrow in Figure 2). Diffuse synovial thickening was seen with moderate joint effusion. Extrinsic erosions were seen on the head and neck of humerus.

The patient was treated by endovascular coiling of the aneurysm. There was remarkable improvement in the patient's symptoms after the procedure. Follow-up MRI done after 3 months showed near-complete resolution in the synovial thickening and signal changes. The patient is under follow-up.

Discussion

About 2% cases of pseudoaneurysms are reported to be secondary to musculoskeletal trauma.^[3] Pseudoaneurysm secondary to anterior dislocation of the shoulder has been reported to have a prevalence of 0.3%.^[4] Literature review shows that pseudoaneurysms following blunt injury to shoulder tend to occur in the third part of axillary artery as it is the least mobile portion due to its relative fixation in this region by circumflex humeral and subcapsular arteries.^[4,5] Mobilization after dislocation can tear these vessels resulting in pseudoaneurysm formation.^[4,5] PVNS, on the other hand, is considered as a neoplastic process. Even though previously various hypotheses were proposed for the etiology of PVNS, such as recurrent intraarticular hemorrhage and unknown

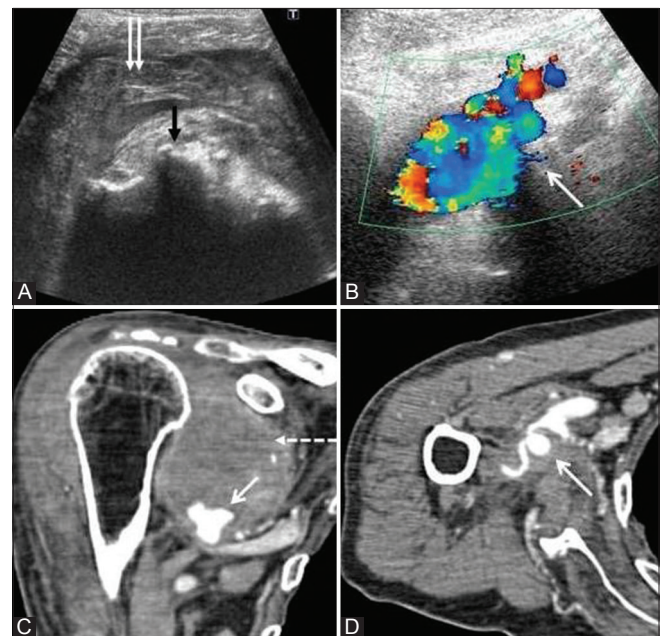


Figure 2 (A-D): (A) B mode ultrasound shows thickened and hypoechoic synovium (paired arrows). Extrinsic erosions (black arrow) are seen in the humeral head with moderate joint effusion. (B) The pseudoaneurysm in the inferior axillary region shows bidirectional flow (arrow) on color Doppler study. (C-D) CT angiography shows pseudoaneurysm (arrow) communicating with axillary artery. The thrombosed portion of aneurysm (interrupted arrow) is appearing as hyperdense soft tissue lesion around the contrast-filled patent aneurysmal sac (arrow)

chronic inflammation, a recent theory states that PVNS, because of its autonomous growth potential, reports of malignant transformation, and consistent identification of cytogenetic alteration is a neoplastic process.^[7]

In our case, the patient had recurrent episodes of shoulder dislocation treated by a local practitioner, which might have resulted in the formation of pseudoaneurysm in the posterior circumflex humeral artery, a branch from the third part of axillary artery.

Though initially the lesion was interpreted as PVNS, when we retrospectively analyzed MRI images after color Doppler and CT angiography, the following observations were evident.

- The characteristic signal void from the patent portion of pseudoaneurysm (arrow in Figure 1) was misinterpreted for low signal intensity lobulated soft tissue lesion of PVNS on MRI
- Hyperplastic changes (hemosiderotic synovitis) in synovium secondary to intraarticular hemorrhage from the pseudoaneurysm and its thrombosed portion were seen as diffuse synovial thickening and lobulated soft tissue in the axillary pouch, respectively. Both had low signal intensity on T1- and T2-W sequences secondary to deposition of hemosiderin
- The extrinsic erosions seen on the head and neck of humerus secondary to hemiarthrosis and synovial proliferation were again due to hemosiderotic synovitis similar to those in hemophilic arthritis^[6], but were misinterpreted here as secondary to PVNS
- Foci of T1 and T2 high signal intensity could be seen in PVNS^[7]. They likely indicate a late subacute stage of blood products, most likely extracellular methemoglobin, indicating bleeding of recent origin (subacute hemorrhage) due to trauma.

All these imaging findings mimicked PVNS so closely on MRI that before Doppler study, it was labeled as a case of PVNS affecting the right shoulder joint. Patient's age (PVNS would be unusual at this age and other causes of hemiarthrosis or complex synovitis should have been considered) and history of shoulder dislocation were completely ignored during the initial MRI interpretation. Follow-up MRI done 3 months post coiling showed resolution of the synovial changes [Figure 3] seen previously, which also supports that the synovial changes were in fact reactive rather than a true neoplastic process. This report intends to highlight the fact that pseudoaneurysms should also be considered in the imaging differential whenever there is history of trauma and imaging findings are suggestive of PVNS.

Conclusion

Even though MRI is the investigation of choice in most of the musculoskeletal afflictions, use of other modalities

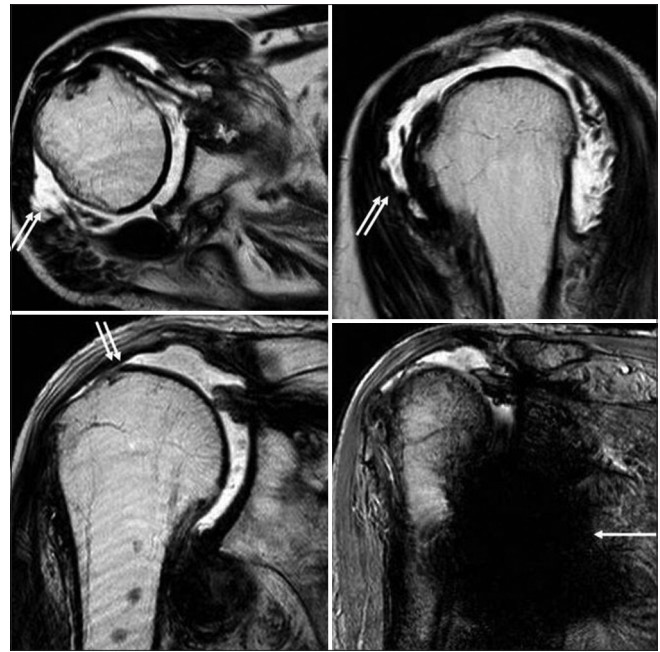


Figure 3 (A-D): (A-C) axial, coronal and sagittal T2WI show marked resolution of the synovial thickening (paired arrows, compare with Figure 1) (D) magnetic susceptibility artifacts (arrow) secondary to coiling of the aneurysm are seen as hypointense signal in the gradient-weighted sequence. Moderate joint effusion is still observed

like USG, Doppler, or CT angiography in appropriate clinical setting can avoid the catastrophe of an inadvertent arthroscopy and biopsy, and to the author's knowledge, there are no previous reports of pseudoaneurysms in the shoulder region mimicking a PVNS.

References

1. Dorwart RH, Genant HK, Johnston WH, Morris JM. Pigmented villonodular synovitis of synovial joints: Clinical, pathologic, and radiologic features. *AJR Am J Roentgenol* 1984;143:877-85.
2. Sheldon PJ, Forrester DM, Learch TJ. Imaging of intraarticular masses. *Radiographics* 2005;25:105-19.
3. Stahnke M, Duddy M. Endovascular repair of a traumatic axillary pseudoaneurysm following anterior shoulder dislocation. *Cardiovasc Intervent Radiol* 2006;29:298-301.
4. Bertrand JC, Maestro M, Péquignot JP, Mouiel J. Vascular complications of simple anterior dislocations of the shoulder. Three cases. *Ann Chir* 1982;36:329-33.
5. Syed AA, Williams HR. Shoulder disarticulation: A sequel of vascular injury secondary to a proximal humeral fracture. *Injury* 2002;33:771-4.
6. Weiss SW, Goldblum JR, Folpe AL. Benign tumors and tumor like lesions of synovial tissue. In: Weiss SW, Goldblum JR, editors. *Enzinger and Weiss's Soft Tissue Tumors*. 5th ed. Philadelphia: Elsevier Health Sciences; 2007. p. 784-7.
7. Murphey MD, Rhee JH, Lewis RB, Fanburg-Smith JC, Flemming DJ, Walker EA. Pigmented villonodular synovitis: Radiologic-pathologic correlation. *Radiographics* 2008;28:1493-518.

Cite this article as: Sannanjanja B, Shah HU, Laxman V, Nagesh C. PVNS or pseudo aneurysm: MRI-problem solving or misleading?. *Indian J Radiol Imaging* 2015;25:60-2.

Source of Support: Nil, **Conflict of Interest:** None declared.