

# Morphometric analysis of diameter and relationship of vertebral artery with respect to transverse foramen in Indian population

Binit Sureka, Mahesh Kumar Mittal, Aliza Mittal<sup>1</sup>, Mukul Sinha Kanhaiya Agarwal, Narendra Kumar Bhambri, Brij Bhushan Thukral

Departments of Radiodiagnosis and <sup>1</sup>Pediatrics, Vardhman Mahavir Medical College and Safdarjung Hospital, New Delhi, India

**Correspondence:** Prof. Mahesh Kumar Mittal, Department of Radiodiagnosis and Imaging, VMMC and Safdarjung Hospital, D-II/222, West Kidwai Nagar, New Delhi - 110 023, India. Email: drmkmittal@rediffmail.com

## Abstract

**Purpose:** To study the location, origin, size and relationship of the vertebral artery and the transverse foramina in the lower cervical spine by computed tomographic angiography (CTA) measurements in the Indian population. **Materials and Methods:** A retrospective review of multi-detector CT (MDCT) cerebral angiography scans was done between June 2011 and February 2014. A total of 120 patients were evaluated. The diameter of the vertebral artery (AL) and the shortest distance between the vertebral artery and the medial (M), lateral (L), anterior (A), and posterior (P) borders of transverse foramen were studied. In addition, the shortest distance between the vertebral artery and pedicle (h) was also analyzed. **Statistical Analysis:** The means and their standard deviations (SD) were calculated in both the sexes. The *t*-tests were performed to look for significant sexual difference. **Results:** The largest vertebral artery diameter (AL) was at level C7 on the right side ( $3.5 \pm 0.8$ ) and at the level of C5 on the left side ( $3.7 \pm 0.4$ ). Statistically significant difference between males and females were seen at levels C4, C5, and C7. The diameter of the vertebral artery was smaller in females than males. The L value was greater than other parameters (M, A, P) at the same level in all the measurements. The h value was greatest at C6 level and shortest at C5. **Conclusion:** CTA is necessary before pedicle screw fixation due to variation in measurements at all levels. The highest potential risk of vertebral artery injury during cervical pedicle screw implantation may be at C5, then at C4, and the safest is at C7.

**Key words:** Angiography, cervical spine, pedicle, vertebral artery

## Introduction

Spine trauma is a devastating event with a high morbidity and mortality and many additional medical, psychological, social, and financial consequences for patients, their families and society. Spinal fractures represent 3-6% of all skeletal

injuries.<sup>[1]</sup> Fractures of cervical spine are most common at C1-C2 level and then at C5-C7 level.

One of the methods of fixation of the cervical spine is by transpedicular screw fixation. This technique is a one-stage procedure with dramatic results.<sup>[2]</sup> The most dreaded complication of these techniques is injury to the vertebral artery. So, before surgery, preoperative imaging with computed tomographic angiography (CTA) should be reviewed to assess the vertebral artery course, its relationship in transverse foramen, and also the pedicle dimensions.<sup>[3]</sup>

Studies have been undertaken by various authors regarding the assessment and for improving the accuracy of screw

### Access this article online

#### Quick Response Code:



**Website:**  
www.ijri.org

**DOI:**  
10.4103/0971-3026.155868

fixation in order to avoid vascular injury. Karaikovic *et al.* in their study identified the lateral vertebral notch, inferior articular process, and the transverse process of C7 as markers for cervical pedicle entrance localization.<sup>[4]</sup> Zhao *et al.* concluded that vertebral artery is in the medial part of transverse foramen and there is abundant space for vertebral artery in the transverse foramen. The highest potential risk of vertebral artery injury during cervical pedicle screw implantation may be at C3, then at C6, the safest is at C7 level.<sup>[3]</sup>

No data is available in the Indian population regarding the vertebral artery diameter, its relationship with the transverse foramen, relative risk, and safety margins for the screw fixation. The aim of this study is to provide nomogram and baseline quantitative data for the location and size of the vertebral artery in relation to transverse foramen of the lower cervical spine.

## Materials And Methods

A total of 120 patients were evaluated. The study population comprised 81 males and 39 females. Mean age of the study group was 41.63 years (range 19-81 years). A retrospective study was done wherein data of patients who had cerebral angiography done for various reasons were collected and analyzed. We excluded patients who had severe deformity of the cervical spine, tortuous and anomalous course of the vertebral artery, and with evidence of infectious, neoplastic, or congenital spine anomalies. Ethical clearance was not required due to retrospective nature of the study.

### CT examination protocol

The patients were placed supine on the table and the neck kept at a neutral position. Multi-detector computed tomography (MDCT) angiography was performed [Philips Brilliance 40-slice-CT-scan machine] after injecting 120 ml of nonionic iodinated contrast material (iodine concentration, 370 mg/ml) through an 18-20 gauge antecubital intravenous cannula at a rate of 5 ml/s. Scanning parameters: thickness 1mm, pitch 0.938, distance 0.5mm, tube tension 120 kV, and electric current 250 mA.

### Image interpretation

The raw data collected from the study was studied after processing in axial sections using appropriate window settings by three radiologists - Radiologist 1 (B. S.) with 6 years of experience, Radiologist 2 (M. S.) with 21 years of experience, and Radiologist 3 (M. K. M.) with 25 years of experience in interpreting CT scans. A standard axial image of the cervical spine (from C3 to C7) where the transverse foramen and vertebral artery were clearly visible was selected for measurement. After selecting the best axial images of the transverse foramen and vertebral artery,

various measurements were taken. Parameters used in the study were as follows: diameter of vertebral artery as the medio-lateral or transverse diameter (AL), the shortest distance between the vertebral artery and the medial (M), lateral (L), anterior (A), and posterior (P) borders of transverse foramen, and the shortest distance between the vertebral artery and pedicle (h) [Figures 1 and 2].

### Statistical analysis

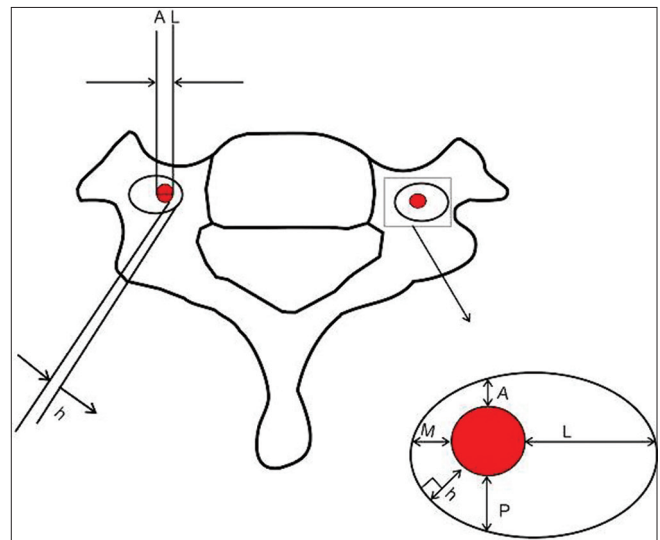
We used SPSS 10.0 for statistical analysis. The means and their standard deviations (SD) were calculated in all males, females, and males and females combined. The *t*-tests were performed to compare the data between males and females and between the different vertebrae. Significant difference was indicated when  $P < 0.05$ .

## Results

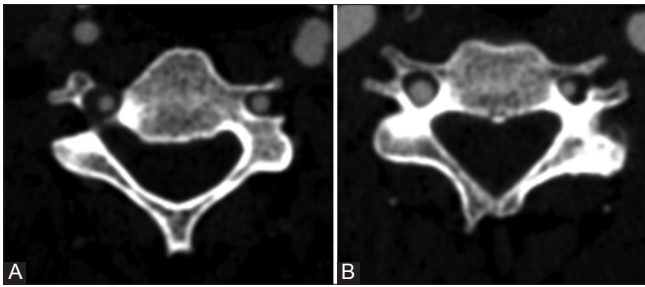
A total of 120 patients were evaluated. The study population comprised 81 males and 39 females. Mean age of the study group was 41.63 years (range 19-81). Age-wise and sex-wise distribution of data is given in Table 1.

### Measurements of vertebral artery

The largest vertebral artery diameter (AL) from C3 to C7 was at level C7 on the right side ( $3.5 \pm 0.8$ ) and at the level of C5 on the left side ( $3.7 \pm 0.4$ ). Statistically significant differences between males and females were seen at levels C4, C5, and C7 [Table 2]. The diameter of the vertebral artery was different at other levels also, but not statistically significant. The diameter of the vertebral artery was smaller in females than males at all levels on both sides except at C7 level on the left side. At C4 level on the left side, the



**Figure 1:** Line diagram showing different measurements used in the study (AL: Diameter of vertebral artery; M, L, A, P: The shortest distance between the vertebral artery and the medial, lateral, anterior, and posterior borders of transverse foramen, respectively; h: The shortest distance between the vertebral artery and cervical pedicle)



**Figure 2:** (a) CTA showing vertebral artery located in the medial part of transverse foramen bilaterally with left-side dominance at C6 (b) CTA showing vertebral artery located in the postero-medial part on the right side with right-side dominance and in the antero-medial part on the left side in a different patient at C4

**Table 1: Age-wise and sex-wise distribution of data**

Age (years)	Male (n=81)	Female (n=39)	Total (%)
19-28	3	2	5 (4.1)
29-38	8	7	15 (12.5)
39-48	18	10	28 (23.3)
49-58	22	15	37 (30.8)
59-68	25	5	30 (25)
69-78	3	0	3 (2.5)
79-88	2	0	2 (1.6)

**Table 2: Vertebral artery measurements of the lower cervical spine**

Spine level	AL right (mm)	AL left (mm)
<b>C3</b>		
Male	3.6±0.7	3.5±0.6
Female	3.0±0.6	3.4±0.6
Total	3.3±0.6	3.4±0.6
<b>C4*</b>		
Male	3.5±0.7	3.4±0.7
Female	3.1±0.5	3.4±0.7
Total	3.3±0.6	3.4±0.7
<b>C5*</b>		
Male	3.6±0.8	4.0±0.3
Female	3.2±0.6	3.4±0.6
Total	3.4±0.7	3.7±0.4
<b>C6</b>		
Male	3.7±0.7	3.5±0.7
Female	3.3±0.6	3.3±0.5
Total	3.5±0.6	3.4±0.6
<b>C7*</b>		
Male	3.8±0.9	3.5±0.8
Female	3.2±0.8	3.5±0.6
Total	3.5±0.8	3.5±0.7

\*Significant sexual difference, AL=Diameter of the vertebral artery

diameter of the vertebral artery was equal in both males and females.

**Location of the vertebral artery in relation to transverse**

**foramen**

The mean shortest distance from vertebral artery to lateral border of transverse foramen (L) was greater than the other parameters (M, A, P) at the same level in all the measurements. At the level of C7, vertebral artery went anterior to transverse process rather than in transverse foramen, so the M, L, A, and P have not been recorded at level C7 in our study.

The mean shortest distance from vertebral artery to posterior border of transverse foramen (P) was greater than the mean shortest distance from vertebral artery to anterior border of transverse foramen (A) at all levels except at C6 on the left side. The greatest M was at C3 and the smallest M was at C6. The greatest L was at C6 and the smallest L was at C4 (right) and C3 (left). The greatest A was at C6 and the smallest A was at C3. Significant difference between males and females was seen at C3 on the right side with respect to L [Table 3]. Age-wise correlation of data in males and females is shown in Table 4.

The mean shortest distance from vertebral artery to cervical pedicle (h) was greatest at C6 level and shortest at C5. There was a drastic change in pattern at C7, where there was a significant increase in h from that of the previous levels.

**Discussion**

The vertebral artery arises as a first branch of the subclavian artery, one on each side of the body. It has four segments. The first segment (V1) is extraosseous and extends from arch to C6. The second segment (V2) is foraminal segment extending from C6 to C1. The third segment is extraspinal (V3) extending from C1 to foramen magnum, and the fourth segment (V4) is the intradural segment which is intracranial. Ectasia, tortuosity, off-midline course, variations in configuration and branching patterns are common. The left vertebral artery is usually larger (dominant) and carries more blood in 45% of the cases. In 30% of the cases, there is right side dominance and in 25%, there is co-dominance. Variation in origin may be the aortic arch origin of left vertebral artery in 5% of the cases. It may be the second branch of the subclavian artery instead of the first branch.

According to a study done by Zhao, *et al.*, M was shorter than L at all measurements. A was shorter than P at C3, C4, and C5, and a little bit longer than P at C6 on the contrary. The shortest distance between vertebral artery and pedicle (h) varied from C3 to C7; the shortest was at C3 (0.5 ± 0.2 mm) and the longest at C7 (7.3 ± 2.7 mm).[3] In our study, similar results were encountered with respect to relation of the vertebral artery. The shortest distance (h) was at level C5 (0.6 ± 0.5) and longest at C7.

**Table 3: Location of the vertebral artery in relation to the transverse foramen in lower cervical spine**

Spine level	M (mm)		L (mm)		A (mm)		P (mm)		h (mm)	
	Right	Left	Right	Left	Right	Left	Right	Left	Right	Left
<b>C3</b>										
Male	1.2±0.7	1.2±0.7	1.3±0.7*	1.5±0.8	0.6±0.5	0.7±0.4	0.9±0.6	0.8±0.5	0.9±0.4	0.8±0.6
Female	1.2±0.7	1.1±0.6	1.9±1.3	1.3±0.6	0.5±0.3	0.8±0.4	1.0±0.5	0.8±0.4	0.7±0.5	0.7±0.4
Total	1.2±0.7	1.1±0.6	1.6±1	1.4±0.7	0.5±0.4	0.7±0.4	0.9±0.5	0.8±0.4	0.8±0.4	0.7±0.5
<b>C4</b>										
Male	0.8±0.6	0.9±0.7	1.5±0.7	1.9±0.6	0.8±0.6	0.8±0.7	0.9±0.7	0.7±0.6	0.7±0.3	0.6±0.5
Female	0.8±0.5	0.8±0.5	1.3±0.8	1.4±0.8	0.8±0.4	0.7±0.5	1.0±0.5	1.0±0.7	0.7±0.5	0.6±0.5
Total	0.8±0.5	0.8±0.6	1.4±0.7	1.6±0.7	0.8±0.5	0.7±0.6	0.9±0.6	0.8±0.6	0.7±0.4	0.6±0.5
<b>C5</b>										
Male	0.8±0.6	0.9±0.6	1.3±0.9	1.8±0.9	0.8±0.7	0.7±0.4	1.0±0.7	1.0±0.9	0.5±0.4	0.7±0.4
Female	0.7±0.6	0.7±0.5	1.7±0.7	1.4±0.8	0.7±0.5	0.5±0.3	1.2±0.6	0.8±0.6	0.7±0.6	0.6±0.4
Total	0.7±0.6	0.8±0.5	1.5±0.8	1.6±0.8	0.7±0.6	0.6±0.6	1.1±0.6	0.9±0.7	0.6±0.5	0.6±0.4
<b>C6</b>										
Male	0.9±0.9	0.6±0.4	1.6±0.8	1.9±1.1	0.6±0.4	0.9±0.7	1.1±0.7	0.9±0.7	1.7±1.0	2.5±1.2
Female	0.5±0.6	0.7±0.5	2.1±0.9	1.5±0.6	1.2±0.9	1.0±0.7	1.0±0.7	0.6±0.2	1.5±0.7	2.9±1.3
Total	0.7±0.7	0.6±0.4	1.8±0.8	1.7±0.8	0.9±0.6	0.9±0.7	1.0±0.7	0.7±0.4	1.6±0.8	2.7±1.2
<b>C7</b>										
Male	-	-	-	-	-	-	-	-	10.5±3.9	10.6±3.7
Female	-	-	-	-	-	-	-	-	11.2±2.4	9.6±3.9
Total									10.8±3.1	10.1±3.8

\*Significant sexual difference, M=Medial, L=Lateral, A=Anterior, P=Posterior, h=Shortest distance between vertebral artery and cervical pedicle

**Table 4: Age-wise and sex-wise correlation of data in males and females**

Sex	Spine level	Variables	Pearson correlation coefficient	P value (significance)
Males (n=81)	C3	L-right	0.211	0.041
		L-left	0.235	0.023
		A-right	-0.350	0.001
		P-left	0.260	0.012
	C4	M-left	0.281	0.006
		A-right	-0.245	0.019
		P-left	0.297	0.004
C5	A-right	0.313	0.002	
Females (n=39)	C4	P-right	0.404	0.012
		h-left	0.423	0.008
	C6	M-right	-0.345	0.034
		L-right	0.398	0.013
		P-left	0.521	0.002
	C7	h-right	0.363	0.025
		h-left	0.448	0.005
		AL-right	0.375	0.020
		h-left	0.471	0.003

The largest vertebral artery diameter (AL) from C3 to C7 was at level C7 on the right side (3.5 ± 0.8) and at the level of C5 on the left side (3.7 ± 0.4). Statistically significant differences between males and females were seen at the levels C4, C5, and C7. The diameter of the vertebral artery

was smaller in females than males at all levels on both sides except at C7 level on the left side. At C4 level on the left side, the diameter of the vertebral artery was equal in both males and females. In our study, right-sided dominance was seen in 33 (27.5%) cases. Co-dominance was seen in 9 (7.5%) cases. Left vertebral artery arising from aortic arch was seen in 11 (9.1%) cases. In 10 (8.3%) cases, left vertebral artery was extraosseous, i.e. anterior to transverse foramen at C6, and in 3 cases, it was extraosseous on the right side at C6.

Transpedicular screw fixation is a one-stage procedure for posterior stabilization of the lower cervical spine. The entry point to the pedicle is 1-2 mm inferior to the caudal edge of the inferior articular process and 2-3 mm lateral to the midline or 2-3 mm medial to the lateral edge of the lateral mass.<sup>[5]</sup> Screws of size 3.5 or 4 mm are generally used, based on preoperative imaging of pedicle dimensions. Small pedicle diameters may require a 2.7-mm screw. The length of the screw ranges from 18 to 26 mm, depending on the length of the pedicle as determined on preoperative CT scans. The screw should be inserted to a depth no longer than two-thirds of the anteroposterior width of the vertebral body, as confirmed on the lateral fluoroscopy image. Since the C7 pedicle is longer, a screw up to 30 mm can usually be inserted at this level. One of complications of these techniques is vertebral artery injury.<sup>[5]</sup>

Various authors have reported cases of vertebral artery injury during screw fixation leading to catastrophic



complications like brain stem infarction, with or without neurologic complications.<sup>[6,7]</sup>

Research done by Yukawa, *et al.*<sup>[8]</sup> has shown that of the 419 cervical pedicle screws, 43 (10.3%) were of the screw exposure type (<50% of the screw outside the pedicle) and 17 (4.0%) were of the pedicle perforation type (>50% of the screw outside the pedicle boundaries). There was only one penetration of a probe into the vertebral artery in their experience. Studies by Yoshimoto, *et al.*, Kast, *et al.*, and Neo, *et al.* have shown that not all violations of the transverse foramen have caused injury to the vertebral artery in the lower cervical spine.<sup>[9-11]</sup> Ludwig, *et al.*<sup>[12]</sup> concluded that if the pedicle diameter was greater than 5.0 mm, 79% of pedicle screws were in, 19% had non-critical breaches, and only 2% had critical breaches. Thus, if the 3.5-mm pedicular screw is to be inserted into the cervical pedicle, the minimum transverse diameter desired is 5.0 mm to allow at least 0.75-mm bony bridge medially and laterally to avoid injury to the adjacent vital structures. A study done by Patwardhan, *et al.*<sup>[13]</sup> found that the transverse pedicle diameter of cervical pedicles in the Indian subjects is smaller as compared to the Western population. As an option, 2.7-mm screws can be devised for the Indian population giving a wider safety margin.

Our study reveals that the mean value of L was greater than that of other parameters (M, A, P) at the same level. The mean shortest distance from the vertebral artery to the posterior border of transverse foramen (P) was greater than the mean shortest distance from the vertebral artery to the anterior border of transverse foramen (A) at all levels (C3-C7) except at C6 on the left side. The greatest M was at C3 and the smallest M was at C6. The greatest L was at C6 and the smallest L was at C4 (right) and C3 (left). The greatest A was at C6 and the smallest A was at C3. Significant difference between males and females was seen at C3 on the right side with respect to L.

It means that the vertebral artery is in the medial part of transverse foramen at C3-C6. There is a relative "opulent space" for vertebral artery in the transverse foramen, which may be one of the reasons for the vertebral artery to remain patent even after critical breach of the pedicle in various studies.

The mean shortest distance from the vertebral artery to the cervical pedicle (h) was greatest at C6 level and shortest at C5, followed by C4 and then at C3. There was a drastic change in pattern at C7, where there was a significant increase in h from that of the previous levels. This result in our population was different from that obtained in the study of Zhao, *et al.* The shortest distance from the vertebral artery to the cervical pedicle observed in our study was 0.1 mm at the C5 level in 10 patients. According to our study, the highest risk of vertebral artery injury during pedicle screw

fixation in lower cervical spine was at level C5, followed by C4 and then at C3. The safest site was at C7 level.

Various factors should be taken into consideration for the measurements of vertebral artery and its relationship with the transverse foramen - aplasia and hypoplasia of the vertebral arteries, age of the patient as tortuosity increases as the age increases, and loop in the vertebral artery which can result in the far lateral or far medial location of the artery in the foramen. A vertebral artery loop pointing medially under a transverse foramen is considered to be a risk factor during surgery. In our study, we observed the loop of vertebral artery extending into the neural foramina in nine patients at various levels. Tortuous course of vertebral artery was seen in 31% cases and this was more commonly seen in patients above the age of 50. Tortuous course was seen in V1 segment of the vertebral artery with convexity toward the medial side in majority of the patients.

The present study had some limitations. In our study, we did not do dynamic imaging with various motions of spine to see if these motions could have an impact on the relationship of vertebral artery in transverse foramen. Further, we excluded patients with deformity of the cervical spine and vertebral artery. Also, the study included patients of wide age group distribution and an unequal number of males and females. The study was done on patients who had diseased arterial walls. So, this data may not be standardized to the general healthy population.

This study tries to comprehensively describe the relationship of vertebral artery in transverse foramen, relative risk during pedicle screw fixation surgery, and vertebral artery diameter in the Indian population. Age, tortuosity, and anatomic variations of vertebral artery have an impact on the "safety margins" and relative risk during surgery. While evaluating non-contrast CT spine in trauma patients, one should carefully look at the transverse foramen diameter at the level of unstable segment; and if required, patients can be subjected to dedicated CTA study of the vertebral arteries prior to surgery. The study concludes that preoperative imaging workup would be complementary in most of the cases for detailed information regarding the course of vertebral artery in transverse foramen.

## Acknowledgement

We express our sincere gratitude to Drs. Richa Talwar and Varun (PSM Department) for statistical calculations.

## References

1. Greenspan A. Orthopedic Radiology: A Practical Approach. Philadelphia: Lippincott-Raven; 2000.
2. Abumi K, Ito H, Taneichi H, Kaneda K. Transpedicular screw

- fixation for traumatic lesions of the middle and lower cervical spine: Description of the techniques and preliminary report. *J Spinal Disord* 1994;7:19-28.
3. Zhao L, Xu R, Hu T, Ma W, Xia H, Wang G. Quantitative evaluation of the location of the vertebral artery in relation to the transverse foramen in the lower cervical spine. *Spine (Phila Pa 1976)* 2008;33:373-8.
  4. Karaikovic EE, Kunakornsawat S, Daubs MD, Madsen TW, Gaines RW Jr. Surgical anatomy of the cervical pedicles: Landmarks for posterior cervical pedicle entrance localization. *J Spinal Disord* 2000;13:63-72.
  5. Wiesel SW. Pedicle screw fixation of the cervical spine [Internet]. Wolters Kluwer; Available from: <https://www.inkling.com/read/operative-techniques-orthopaedic-surgery-vol-4-1st/chapter-sp-10/technique-pedicle-screw>. [Last accessed on 2014 Mar 10].
  6. Cho KH, Shin YS, Yoon SH, Kim SH, Ahn YH, Cho KG. Poor surgical technique in cervical plating leading to vertebral artery injury and brain stem infarction--case report. *Surg Neurol* 2005;64:221-5.
  7. Abumi K, Shono Y, Ito M, Taneichi H, Kotani Y, Kaneda K. Complication of pedicle screw fixation in reconstructive surgery of the cervical spine. *Spine (Phila Pa 1976)* 2000;25:962-9.
  8. Yukawa Y, Kato F, Yoshihara H, Yanase M, Ito K. Cervical pedicle screw fixation in 100 cases of unstable cervical injuries: Pedicle axis views obtained using fluoroscopy. *J Neurosurg Spine* 2006;5:488-93.
  9. Yoshimoto H, Sato S, Hyakumachi T, Yanagibashi Y, Masuda T. Spinal reconstruction using a cervical pedicle screw system. *Clin Orthop Relat Res* 2005;111-9.
  10. Kast E, Mohr K, Richter HP, Börm W. Complications of transpedicular screw fixation in the cervical spine. *Eur Spine J* 2006;15:327-34.
  11. Neo M, Sakamoto T, Fujibayashi S, Nakamura T. The clinical risk of vertebral artery injury from cervical pedicle screws inserted in degenerative vertebrae. *Spine (Phila Pa 1976)* 2005;30:2800-5.
  12. Ludwig SC, Kowalski JM, Edwards CC 2<sup>nd</sup>, Heller JG. Cervical pedicle screws: Comparative accuracy of two insertion techniques. *Spine (Phila Pa 1976)* 2000;25:2675-81.
  13. Patwardhan AR, Nemade PS, Bhosale SK, Srivastava SK. Computed tomography-based morphometric analysis of cervical pedicles in Indian population: A pilot study to assess feasibility of transpedicular screw fixation. *J Postgrad Med* 2012;58:119-22.

**Cite this article as:** Sureka B, Mittal MK, Mittal A, Kanhaiya Agarwal MS, Bhabri NK, Thukral BB. Morphometric analysis of diameter and relationship of vertebral artery with respect to transverse foramen in Indian population. *Indian J Radiol Imaging* 2015;25:167-72.

**Source of Support:** Nil, **Conflict of Interest:** None declared.