Article published online: 2021-07-30

Osmotic myelinolysis: Does extrapontine myelinolysis precede central pontine myelinolysis? Report of two cases and review of literature

Sabale Avinash Babanrao, Anil Prahladan, Kalirajan Kalidos, Krishnankutty Ramachandran
Department of Imageology, Regional Cancer Centre, Trivandrum, Kerala, India

Correspondence: Dr. Sabale Avinash Babanrao, Room No 26 PACS Room, Department of Imageology, Regional Cancer Centre, Medical College Campus, Trivandrum - 695 011, Kerala, India. E-mail: drsabaleavinash@yahoo.co.in

Abstract

Osmotic myelinolysis is an acute, rare, demyelinating process. After the initial description of the condition by Adam and colleagues in 1959, many case series have been published describing the central and extrapontine myelinolysis. Imaging has a definitive role in establishing the diagnosis of osmotic myelinolysis *in vivo* and diffusion-weighted imaging reveals earliest changes in affected brain parenchyma. We report two cases of patients with proven malignancy who developed extrapontine myelinolysis after treatment for hyponatremia and progressed to central pontine myelinolysis within a week. This was confirmed with magnetic resonance (MR) imaging and clinical assessment. This temporal progression of MR features, especially on diffusion-weighted imaging, from extrapontine to central pontine myelinolysis in osmotic injury has not been described in literature to the best of our knowledge. An early MRI of the brain in suspected/high-risk cases of osmotic myelinolysis may show features of extrapontine myelinolysis in the form of restricted diffusion in bilateral basal ganglia and may serve as a guide for predicting progression, prognosticating and deciding further treatment of pontine myelinolysis. We propose that in a significant number of cases, central pontine myelinolysis may be predicted by doing an early MRI of the brain with diffusion-weighted imaging, when extrapontine symptoms start to develop. This can potentially increase the window period and possibilities for therapeutic intervention and may even help in prevention.

Key words: Central pontine myelinolysis; diffusion weighted magnetic resonance imaging; extrapontine myelinolysis; osmotic myelinolysis

Introduction

Osmotic myelinolysis is an acute, rare, demyelinating process. Central pontine myelinolysis (CPM) was first described by Adams and colleagues in 1959 as a disease affecting alcoholics and the malnourished.[1] However, in 1962, it was found that similar lesions can occur outside the pons, the so-called extrapontine myelinolysis (EPM).

Access this article online	
Quick Response Code:	Website: www.ijri.org
	DOI: 10.4103/0971-3026.155870

In 1982, it was established that these disorders are associated with rapid correction of sodium in hyponatremic patients.[2,3] When osmotic demyelination occurs, it is usually irreversible and has no definitive management. Thus, prevention is more important. It is recommended that the rate of increase of serum sodium should not be more than 0.5 mmol/l/h and should not exceed 10 mmol/l during the first 24 h.[4]

Role of MRI in diagnosis of osmotic myelinolysis is also well established. Diffusion-weighted imaging is particularly important in the early detection of the osmotic myelinolysis.[4,5]

We report two cases of patients who developed EPM after treatment of hyponatremia and progressed to CPM within a week. This was confirmed with MRI and clinical

assessment. Both patients had proven malignancy and were undergoing systemic chemotherapy.

Case Reports

Case 1

A 58-year-old female, a known case of carcinoma ovary on neoadjuvant chemotherapy with paclitaxel and cisplatin, developed severe headache and nausea and vomiting after her second cycle of chemotherapy. She was admitted in a local hospital and found to have severe hyponatremia with a serum sodium level of 97 mmol/l. She was administered 3% hypertonic saline and subsequently serum sodium level rose to 132 mmol/l within 48 h. She was referred to our hospital after her neurological status deteriorated. At presentation, the patient was disoriented and dysarthric, but able to complain of headache. On clinical examination, her pulse rate was 98/min and blood pressure was normal (130/80 mmHg). Blood O2 saturation was 98%. Her blood parameters and renal and liver function tests (RFT and LFT, respectively) were within normal limits. Serum sodium was 133 mmol/l. Power was normal in all four limbs. Touch and pain sensation was normal. However, on walking, she had a tendency to sway to one side. MRI brain was advised at this stage.

1st MRI (3 days after correction of hyponatremia)

MRI brain (GE Signa HDxt 1.5 T, GE healthcare United States) revealed T2 and fluid-attenuated inversion recovery (FLAIR) hyperintensity involving caudate nucleus and putamen with sparing of the globus pallidus, internal capsule, and thalami. The lesions were hypointense on T1-weighted (T1W) images and showed moderate restricted diffusion with corresponding low apparent diffusion coefficient (ADC) values. There were no other altered signal intensity lesions or enhancement in the cerebral or cerebellar parenchyma. Brainstem structures were normal [Figure 1]. Possibility of EPM was suggested considering the history of rapid correction of hyponatremia and typical MR findings.

The patient deteriorated over the next 4 days and developed seizures with spastic quadriplegia. She was stuporous.

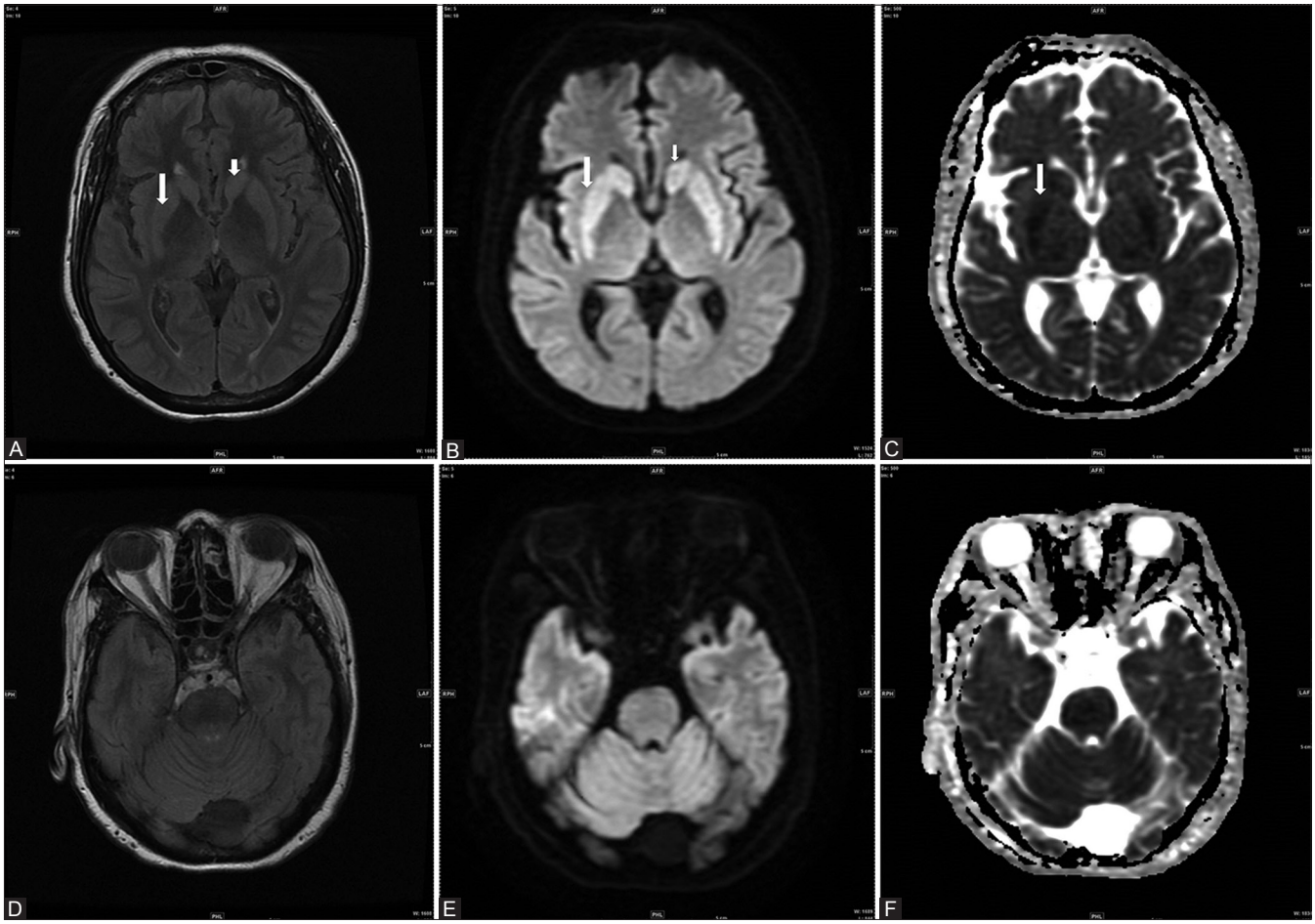

Figure 1: Case 1 (1st MRI - 3 days after correction of hyponatremia) (A) Axial FLAIR section at the level of basal ganglia shows subtle hyperintense signal in both the caudate nuclei and putamina (B) Axial DWI section at the level of basal ganglia shows hyperintense signal in both caudate heads and putamina suggestive of diffusion restriction (C) Axial ADC map at the level of basal ganglia shows low ADC values in both caudate heads and putamina suggestive of extrapontine myelinolysis (D) Axial FLAIR section at the level of pons shows no significant signal change (E) Axial DWI section at the level of pons shows no diffusion restriction (F) Axial ADC map at the level of pons shows no diffusion restriction

Plantar reflexes were upgoing. She had tachycardia (100/min) and her blood pressure was elevated (160/94 mmHg). Blood parameters, RFT, LFT, and serum electrolyte levels were normal.

A repeat MRI brain was advised.

2nd MRI (7 days after correction of hyponatremia)

MRI brain revealed T2 and FLAIR hyperintensity involving caudate nucleus and putamen selectively with sparing of the globus pallidus and internal capsule. The hyperintense signal had increased in size and magnitude compared to previous MRI. The thalami now showed hyperintense signals. On T1W images, the lesions were hypointense. The involved caudate, putamen, and thalami showed high signal on diffusion-weighted images; however, corresponding ADC values were high, suggestive of facilitated diffusion/T2 shine-through. T1-hypointense and T2 and FLAIR-hyperintense signals were seen in the central region of pons with strong diffusion restriction (not seen on the earlier scan). There were no other altered signal intensity lesions or enhancement in cerebral or cerebellar parenchyma [Figure 2]. MRI diagnosis of CPM was made.

Electroencephalography (EEG) study was done which revealed moderate degree of persistent electrophysiological disturbance with triphasic waves suggestive of metabolic or endocrine encephalopathy.

Patient was managed symptomatically and given methyl prednisolone, thiamine, and pramipexole. She had multiple episodes of seizures during her stay in the hospital. After nearly a month, she regained consciousness and started taking oral feeds. However, she had residual quadriparesis and her higher mental functions were impaired.

Case 2

A 63-year-old lady, a known case of Hodgkin's lymphoma (mixed cellularity stage IVB), was on ABVD (Adriamycin, Bleomycin, Vinblastine, Dacarbazine) regimen. Following her 1A cycle, she developed nausea, vomiting, severe headache and disorientation. On admission, her pulse was 86/min, BP was

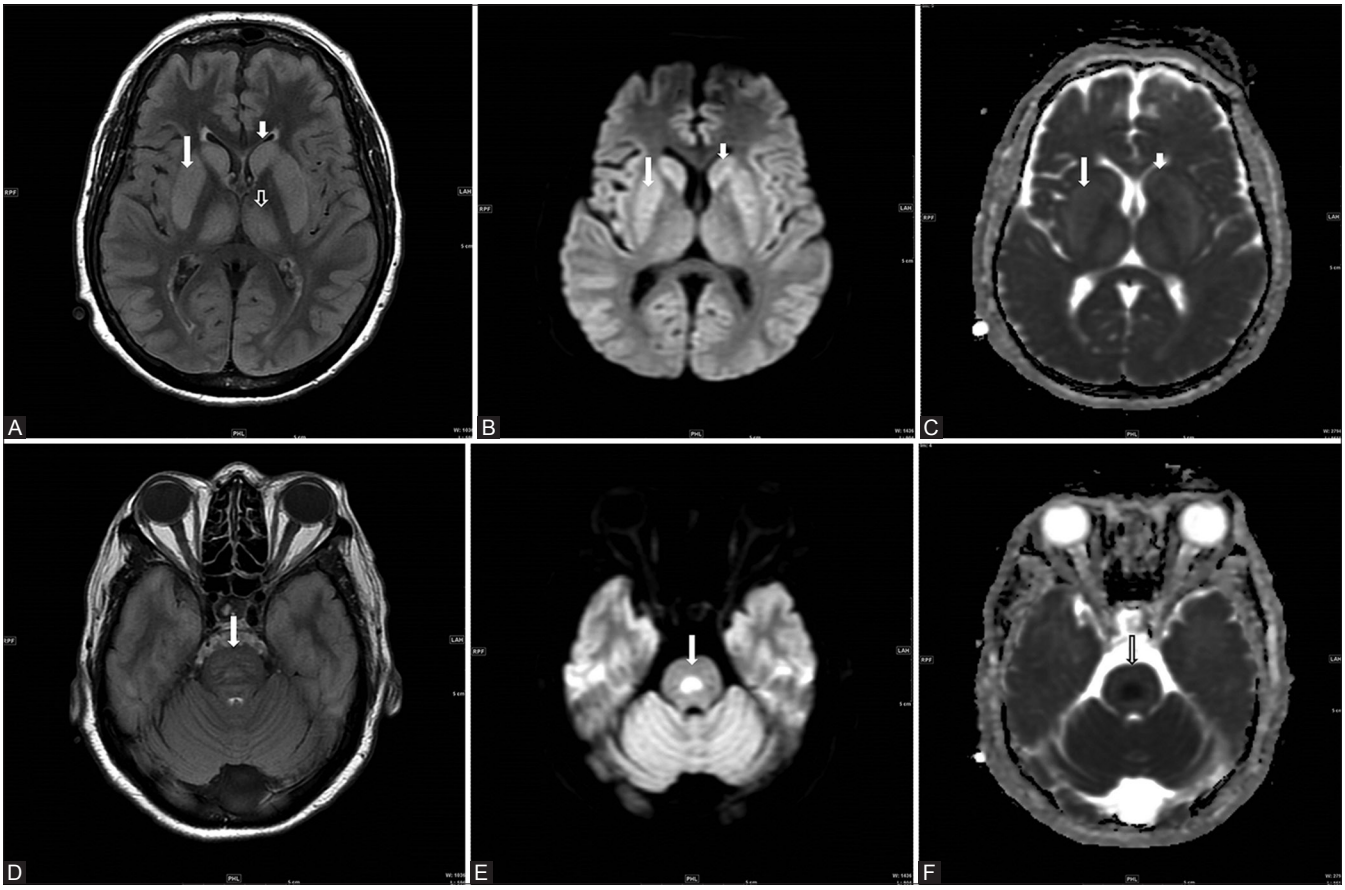

Figure 2: Case 1 (2nd MRI - 7days after correction of hyponatremia) (A) Axial FLAIR section at the level of basal ganglia shows hyperintense signal in both caudate heads and putamina as well as in thalami (B) Axial DWI section at the level of basal ganglia shows hyperintense signal in basal ganglia i.e. both caudate heads and putamina as well as in thalami (C) Axial ADC map at the level of basal ganglia shows high ADC values suggestive of decreased diffusion restriction and T2 shine through effect (D) Axial FLAIR section at the level of pons shows hyperintense signal in the central pons. (E) Axial DWI section at the level of pons shows diffusion restriction within central pons (F) Axial ADC map at the level of pons shows low ADC values in central pons suggestive of strong diffusion restriction (central pontine myelinolysis)

120/84 mmHg, and respiratory rate was 16/min. There was no sensory motor deficit. Plantars were flexor. On routine blood examination, serum sodium levels were found to be 98 mmol/l. She was started on 3% hypertonic saline with meticulous monitoring of serum electrolyte levels. Over the next 5 days, the serum sodium levels were corrected from 98 to 132 mmol/l (not more than 8 mmol/l/day). However, after 2 days of correction, the patient became restless and agitated. She developed delusions and hallucinations. She progressively deteriorated and became stuporous with decreased responsiveness. On examination, there was no sensory or motor deficit. Also, there was no rigidity in either of the limbs. Plantar was flexor on the right side and extensor on the left. Eye movements were sluggish.

MRI brain was advised at this stage.

1st MRI study (4 days after correction of hyponatremia)

MRI brain revealed T2 and FLAIR hyperintensity involving caudate nucleus and putamen, sparing the globus pallidus, internal capsule, and thalami. On T1W imaging, the lesions were hypointense. The involved caudate and putamen showed moderate diffusion restriction and low corresponding ADC values. There were no other altered signal intensity lesions or enhancing foci in cerebral or cerebellar parenchyma. Brainstem structures-midbrain, pons, and medulla-were normal [Figure 3]. Possibility of EPM was suggested.

Patient progressively deteriorated over the next 4 days and developed spastic quadriplegia and became comatose. Her vital and laboratory parameters were normal. A repeat MRI brain was advised.

2nd MRI (9 days after correction of hyponatremia)

The hyperintense signals had increased in size and intensity in comparison to previous MRI. The thalami were now involved. On T1W imaging, the lesions were hypointense. The entire altered signal intensity area showed no evidence of restricted diffusion. New lesions showing strong diffusion restriction were seen in the pons, showing trident or bat wing appearance. Rest of the cerebral or cerebellar parenchyma was normal [Figure 4]. MRI diagnosis of CPM was given.

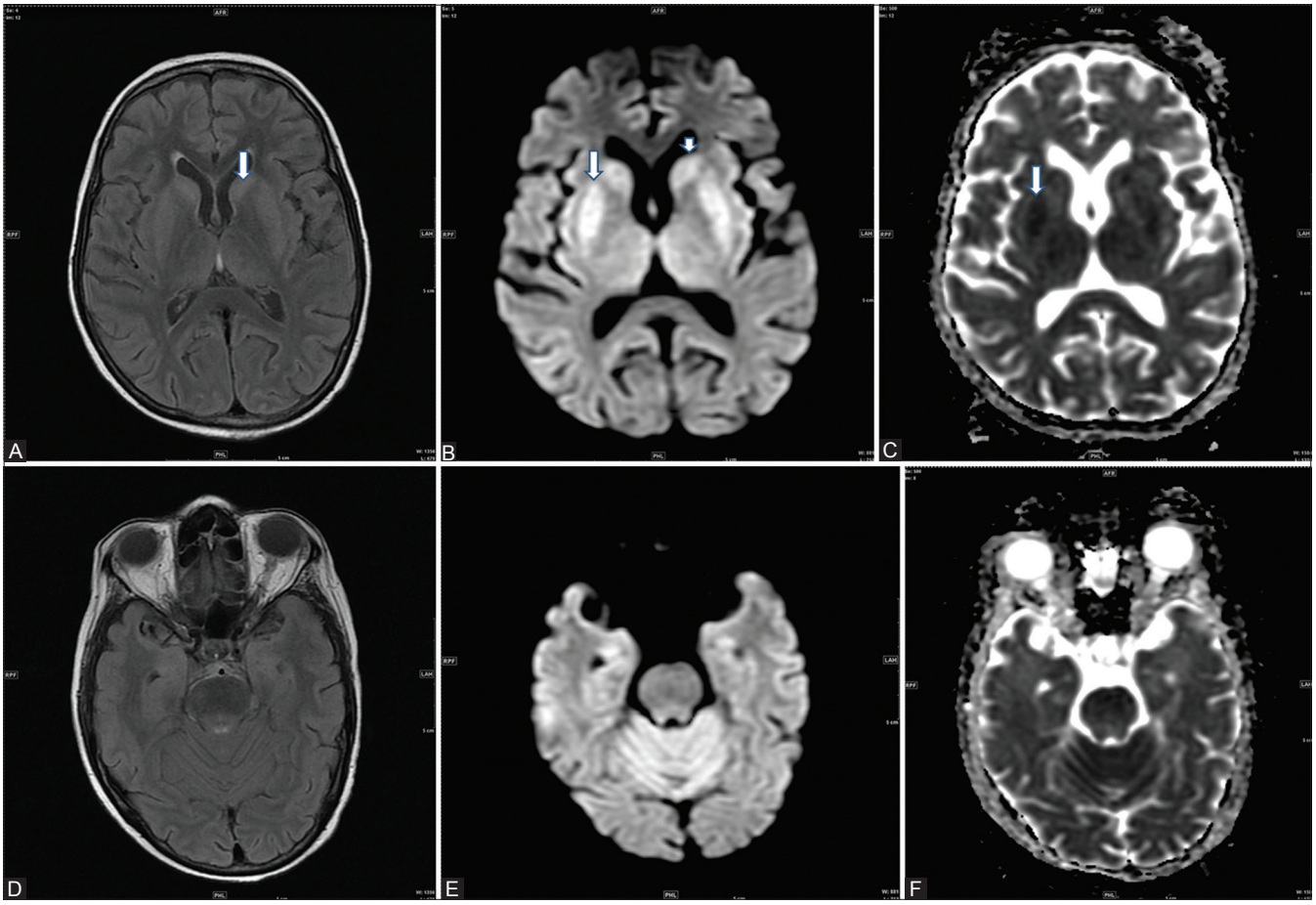

Figure 3: Case 2 (1st MRI - 4 days after correction of hyponatremia) (A) Axial FLAIR section at the level of basal ganglia shows subtle hyperintense signal in both the caudate nuclei and putamina (B) Axial DWI section at the level of basal ganglia shows hyperintense signal in both caudate heads and putamina suggestive of diffusion restriction (C) Axial ADC map at the level of basal ganglia shows low ADC values in both caudate heads and putamina suggestive of extrapontine myelinolysis (D) Axial FLAIR section at the level of pons shows no significant signal change (E) Axial DWI section at the level of pons shows no diffusion restriction (F) Axial ADC map at the level of pons shows no diffusion restriction

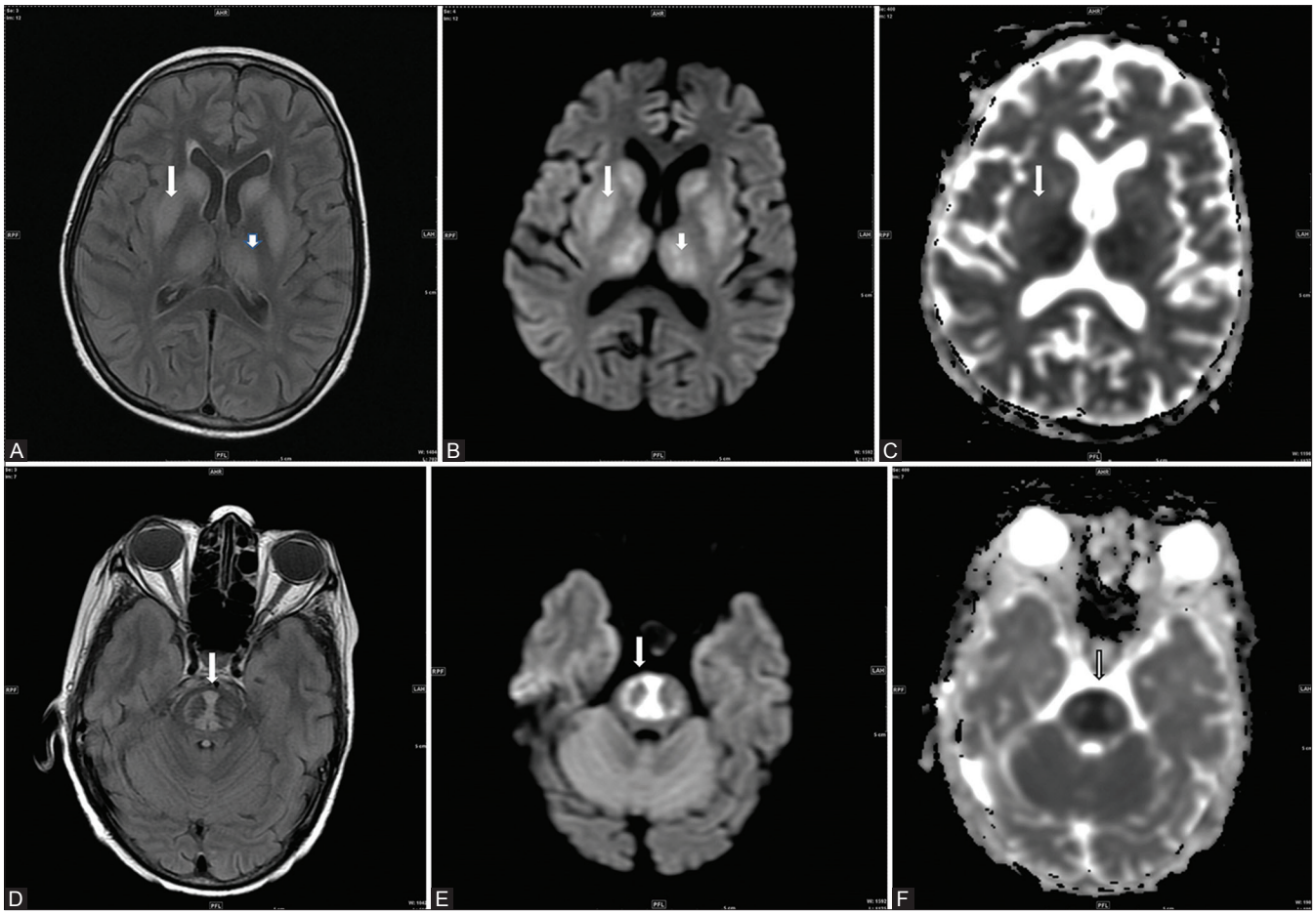

Figure 4: Case 2 (2nd MRI - 9 days after correction of hyponatremia) (A) Axial FLAIR section at the level of basal ganglia shows hyperintense signal in both caudate heads and putamina as well as in thalami (B) Axial DWI section at the level of basal ganglia shows hyperintense signal in both caudate heads and putamina as well as in thalami (C) Axial ADC map at the level of basal ganglia shows high ADC values suggestive of decreased diffusion restriction and T2 shine through effect (D) Axial FLAIR section at the level of pons shows trident-shaped hyperintensity within central pons (E) Axial DWI section at the level of pons shows strong diffusion restriction in pons (trident-shaped) (F) Axial ADC map at the level of pons shows low ADC values suggestive of strong diffusion restriction (central pontine myelinolysis)

EEG study was done which revealed severe degree of persistent electrophysiological disturbance with triphasic waves suggestive of metabolic or endocrine encephalopathy. Patient was managed with methyl prednisolone, thiamine, and pramipexole. At the time of writing this report, the patient was still in stupor and having spastic quadriplegia.

Discussion and Literature Review

Pontine myelinolysis was first described by Adams *et al.* in 1959 and it was proven to be associated with either rapid or over-correction of hyponatremia in animal models by Laureno (in dogs)[2] and Kleinschmidt-DeMasters and Norenberg (in rats)[3] in 1982.

In a hypotonic environment, the cell volume tends to increase, which can lead to cell death. However, *in vivo*, in hyponatremic state, the cell volume is maintained by regulatory volume decrease. In the brain, the first protective mechanism is forcing interstitial sodium-rich fluid into cerebrospinal fluid (CSF). Over the next few hours, potassium is lost and this reaches a peak after 24 h. Other substances, like organic osmoles (such as myoinisotol, taurine, and glutamate), are also lost over a few days, rendering the cell isotonic to the extracellular fluid and maintaining the cell volume.[6]

On correction of hyponatremia, the reaccumulation of electrolytes lost in response to a hypertonic environment is not the same process "in reverse." Once inorganic ion (Na and K) shifts in interstitial and intracellular compartment have been exhausted, the rate of rise of tonicity is faster than the rate at which organic osmoles can be synthesized and/or transported into the cell. As a result, the cell shrinks. It appears that oligodendrocytes are especially vulnerable to death, from volume loss, which leads to myelinolysis. The pons is considered to be the most susceptible organ for osmotic myelinolysis because the anatomically gray matter and white matter are intermixed in pons.[7]

The risk of CPM is believed to be associated with a rapid (>10 mmol/l/day) correction or overcorrection of the serum sodium concentration. However, there is no accepted safe rate of correction.[7] In the second case we have reported, of EPM + PM, the rate or serum sodium level correction did not exceed >8 mmol/l, affirming the above statement. Osmotic myelinolysis typically causes trident-shaped signal change within the pons on T2WI.[8] There is sparing of the cortico-spinal tracts and the tegmentum. This radiological appearance may persist despite clinical improvement.[9] Extrapontine changes have been described in the basal ganglia, white matter, and cerebellum with typical pallidal sparing.[9]

Literature describes that the symptoms and classical radiographic changes typically occur between 7 and 14 days after acute osmotic shift.[10] MRI appears to be the most sensitive modality. The pathophysiology behind this temporal delay after the initial insult is poorly understood.

A report by Kimberly *et al*. was among the most initial ones to demonstrate diffusion restriction in central pons as the first imaging manifestation of central pontine (osmotic) myelinolysis. Their report describes positive diffusion restriction in central pons within 24 h of the onset of quadriplegia with no significant signal changes on conventional MR images. Follow-up MRI, performed 5 days later, showed that the restricted diffusion within the pons had increased in magnitude and area of involvement, along with signal changes on T1W, T2W, and FLAIR images.[5]

Restricted diffusion has been reported by Cramer *et al.* in two patients with CPM who underwent MRI at day 6 and 7, respectively, following the onset of tetraplegia.[11]

EPM also show similar MRI features with bilateral basal ganglia hyperintensity on T2W and FLAIR images and diffusion restriction with typical pallidal sparing. Differential diagnosis of the basal ganglia hyperintensity with diffusion restriction includes hypoglycemia and hypoxic ischemic encephalopathy (HIE). Hypoglycemia can be ruled out by blood sugar level monitoring and hypoxia by history. Acute exposure to respiratory chain metabolic toxins like carbon monoxide poisoning and hyperammonemia are among other causes of bilateral basal ganglia hyperintensity with diffusion restriction and can be easily ruled out by history alone. Wernicke encephalopathy usually has more patchy and asymmetrical distribution; moreover, it shows the clinical features of vitamin B1 deficiency. Creutzfeldt–Jakob disease is usually seen with immunocompromised patients and can be differentiated from other causes by T1 hyperintensity of involved regions and cortical involvement. Deep cerebral venous thrombosis can be ruled out by contrast-enhanced MRI and susceptibility-weighted imaging. Flavivirus encephalitis like Japanese encephalitis can be ruled out with a history of fever or clinical features of encephalitis.

Although initially described in alcoholics and terminally ill patients, hyponatremia and osmotic myelinolysis were found to be associated with specific clinical scenarios. In oncology practice, chemotherapy drugs like cisplatin, paclitaxel, cyclophosphamide, and vincristine can cause hyponatremia.[12] Correction of hyponatremia in these cases is a clinical challenge and complications like myelinolysis are not uncommon.

In both our cases, the clinical presentation and MR features were suggestive of EPM at presentation (3-4 days after the history of hyponatremia correction). Both cases progressed symptomatically to spastic quadriplegia and a second MRI study done after 7-8 days of hyponatremia correction showed CPM in the form of diffusion restriction in central pons. The magnitude of restricted diffusion at extrapontine sites decreased in one case, while it remained the same or status quo was maintained in the other. T2 and FLAIR hyperintensity increased in area and intensity in both cases.

This temporal progression of MR features, especially on diffusion-weighted imaging, from extrapontine to CPM in osmotic injury has not been described in literature to the best of our knowledge. And we suspect that a significant number of the reported cases of pontine myelinolysis might have had the condition preceded by EPM which then probably resolved. The clinical features of pontine myelinolysis like spastic quadriplegia, which typically sets in after a week of hyponatremia correction, mask the symptoms of EPM. The diffusion restriction in EPM appears more transient and wears off by the second week. Features of pontine myelinolysis dominate in the second week in the form of trident-shaped diffusion restriction in the pons within 24 h of onset of quadriplegia followed by signal changes on T2 and FLAIR afterward.

Further studies are needed to confirm the progression of diffusion imaging changes from extrapontine to pontine region. Although no specific treatment has been formulated for the management of osmotic myelinolysis, recently, survival rates have increased. In the most recent large series of 34 cases, only two deaths were reported. Ten survived, but were left dependent; 11 had some deficits, but were independent; and 11 recovered completely.[13] Newer treatment strategies are being tested like IV desmopressin and 5% dextrose in suspected/high-risk cases of osmotic myelinolysis.[14,15] Although previous studies have described the clinical symptoms of EPM preceding CPM, the symptoms of EPM are highly nonspecific and cannot serve as a guide to therapy. However, MRI with diffusion-weighted imaging in such suspected/high-risk cases of osmotic myelinolysis can establish the diagnosis of EPM early and can increase the therapeutic window period before CPM occurs. It would potentially allow for earlier intervention with the current therapies, as well as with the new therapies as they arise. It might also be

used as part of eligibility criteria for testing new agents for treatment. In summary, it may serve as a guide for predicting progression, prognosticating and deciding further treatment of CPM.

Still it is worthy to note that as the pathophysiology of development and progression of osmotic myelinolysis is still poorly understood, more detailed molecular imaging research is necessary to make MR or other imaging [like positron emission tomography (PET) scan] modalities a truly monitoring/therapy-modifying tool.

Conclusion

The two cases discussed in our report demonstrated progression of clinical and imaging manifestations of extrapontine osmotic myelinolysis that had been detected early with diffusion-weighted imaging to CPM. We hereby propose that in a significant number of cases, CPM may be predicted by doing an early MRI of the brain with diffusion, when extrapontine symptoms start to develop. This can potentially increase the window period and possibilities for therapeutic intervention, and may even help in prevention.

References

1. Adams RD, Victor M, Mancall EL. Central pontine myelinolysis: A hitherto undescribed disease occurring in alcoholic and malnourished patients. AMA Arch Neurol Psychiatry 1959;81:154-72.
2. Karp BI, Laureno R. Central pontine and extrapontine myelinolysis after correction of hyponatraemia. Neurologist 2000;6:255-66.
3. Kleinschmidt-DeMasters BK, Norenberg MD. Rapid correction of hyponatremia causes demyelinization: Relation to central pontine myelinolysis. Science 1981;211:1068-70.
4. Ruzek KA, Campeau NG, Miller GM. Early diagnosis of central pontine myelinolysis with diffusion-weighted imaging. AJNR Am J Neuroradiol 2004;25:210-3.
5. Chu K, Kang DW, Ko SB, Kim M. Diffusion-weighted MR findings of central pontine and extrapontine myelinolysis. Acta Neurol Scand 2001;104:385-8.
6. Martin RJ. Central pontine and extrapontine myelinolysis: The osmotic demyelination syndromes. J Neurol Neurosurg Psychiatry 2004;75(Suppl 3):iii22-8.
7. Adrogué HJ, Madias NE. Hyponatremia. N Engl J Med 2000;342:1581-9.
8. Miller GM, Baker HL Jr, Okazaki H, Whisnsnt JP. Central pontine myelinolysis and its imitators: MR findings. Radiology 1988;168:795-802.
9. Ho VB, Fitz CR, Yoder CC, Geyer CA. Resolving MR features in osmotic Myelinolysis (Central pontine and extrapontine myelinolysis). AJNR Am J Neuroradiol 1993;14:163-7.
10. Chu K, Kang DW, Ko SB, Kim M. Diffusion-weighted MR findings of central pontine and extrapontine myelinolysis. Acta Neurol Scand 2001;104:385-8.
11. Cramer SC, Stegbauer KC, Schneider A, Mukai J, Maravilla KR. Decreased diffusion in central pontine myelinolysis. AJNR Am J Neuroradiol 2001;22:1476-9.
12. Upadhyay A, Jaber BL, Madias NE. Epidemiology of hyponatremia. Semin Nephrol 2009;29:227-38
13. Menger H, Jörg J. Outcome of central pontine and extrapontine myelinolysis (n = 44). J Neurol 1999;246:700-5.
14. Oya S, Tsutsumi K, Ueki K, Kirino T. Reinduction of hyponatremia to treat central pontine myelinolysis. Neurology 2001;57:1931-2.
15. Perianayagam A, Sterns RH, Silver SM, Grieff M, Mayo R, Hix J, *et al*. DDAVP is effective in preventing and reversing inadvertent overcorrection of hyponatremia. Clin J Am Soc Nephrol 2008;3:331-6.

Cite this article as: Babanrao SA, Prahladan A, Kalidos K, Ramachandran K. Osmotic myelinolysis: Does extrapontine myelinolysis precede central pontine myelinolysis? Report of two cases and review of literature. Indian J Radiol Imaging 2015;25:177-83.

Source of Support: Nil, **Conflict of Interest:** None declared.