

# USG-guided needle-directed pulse-spray pharmaco-mechanical thrombolysis of hemodialysis grafts/fistula: A novel technique

Amitha Vikrama KS, Srivalli N<sup>1</sup>, Venkataramana Raju S<sup>2</sup>

Department of Interventional Radiology, Sakra World Hospital, <sup>1</sup>Departments of Radiology, and <sup>2</sup>Nephrology, Apollo Hospitals, Bangalore, Karnataka, India

**Correspondence:** Dr. KS Amitha Vikrama, Sakra World Hospital, 52/2 and 52/3, Devarabeesanahalli, Varthur Hobli, Bangalore - 560 103, Karnataka, India. E-mail: amithavikrama@gmail.com

## Abstract

The incidence of end-stage renal disease is significantly increasing and most patients who require renal transplantation are undergoing hemodialysis through tunneled/non-tunneled dialysis catheters and arteriovenous fistulas. The greatest disadvantage of the hemodialysis access is the limited durability of the arteriovenous fistulas and grafts, which, on average, remain patent for <3 years, but are the lifeline for hemodialysis patients. Catheter-directed interventions are successful in re-establishing flow in more than 80% of thrombosed hemodialysis fistulas and have become the treatment of choice for failing or thrombosed accesses. However, these interventions are expensive and require a tertiary center with well-equipped labs. The novel technique of needle-directed thrombolysis is less expensive and can be done on an OPD basis in any primary healthcare setup. To the extent we have searched, no such technique has been published so far in the English literature.

**Key words:** Hemodialysis fistula; thrombolysis; USG-guided procedure

## Introduction

Percutaneous thrombolysis of hemodialysis fistulas became a well-established and promising technique after the development of the pharmaco-mechanical technique of pulse-spray thrombolysis.<sup>[1,2]</sup> All these years, the catheter-directed interventions have been widely used for thrombolysis. They require patient admission, preliminary investigations, and fluoroscopic guidance. Thrombolysis is done using infusion catheters placed inside the grafts/thrombosed vein, followed by balloon

angioplasty or stenting if required. This new technique of needle-directed thrombolysis can be done as an OPD procedure/bedside with USG guidance. It does not require the use of fluoroscopy or the infusion catheters and wires, thereby significantly reducing the cost of the procedure and hospital stay.

## Procedure

After the initial USG examination (GE Logiq e, USA) of the thrombosed segment, 5000 units of heparin was injected intravenously. Under aseptic precautions and USG guidance, multiple 26 G needles were inserted into the thrombosed vein or graft and were connected to three-way stop cocks with short connectors [Figure 1]. The thrombolytic solution was prepared by dissolving 2.5 lakh units of Urokinase (U Frag, Bharat serum and vaccines Ltd, India) in 10 ml of heparinized saline (1000 U heparin) as described by Valji *et al.*<sup>[3]</sup> Manual pulse injections of 0.2-0.3 ml aliquots were applied to each needle about every

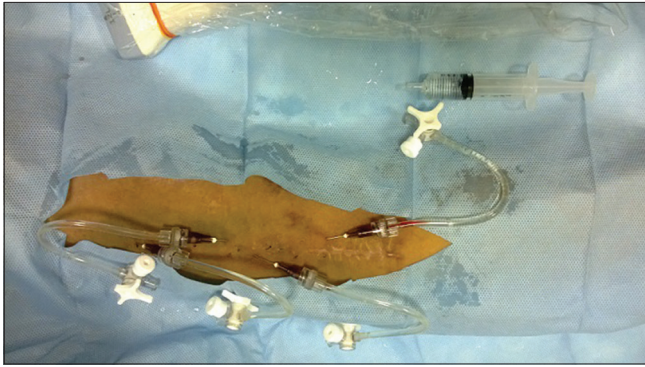
### Access this article online

#### Quick Response Code:

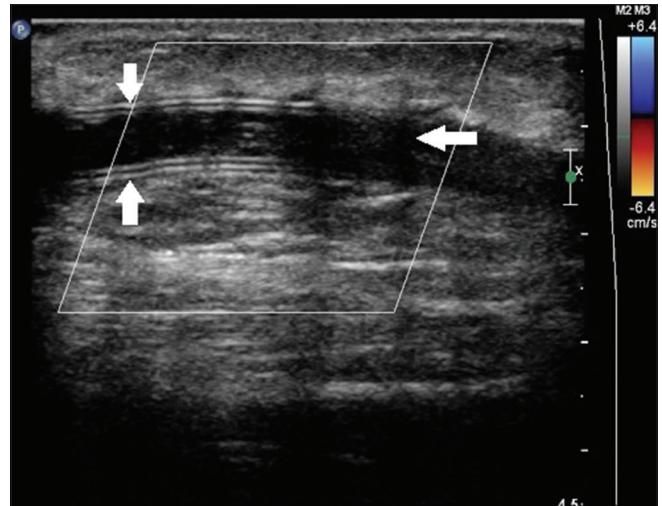


**Website:**  
www.ijri.org

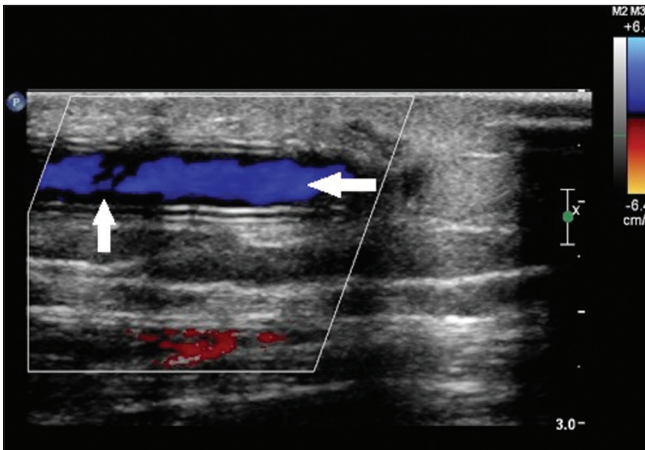
**DOI:**  
10.4103/0971-3026.161442



**Figure 1:** Photograph showing multiple 26 G needles inserted into the arteriovenous fistula (AVF) graft in the arm. Three-way stop cocks with connectors are connected to the needles



**Figure 2:** Doppler image showing hypoechoic thrombus (horizontal arrow) within the AVF graft (vertical arrows). No colour flow seen within the graft



**Figure 3:** Post procedure doppler showing restored flow (horizontal arrow) within the arteriovenous fistula graft with few residual clots (vertical arrow) in the periphery

30 s with a 1 ml syringe. Forceful and rapid injections were essential to adequately penetrate the thrombus and to achieve uniform thrombolysis. Care was taken to keep air bubbles out of the system. Intermittent USG screening was done to assess the progress of the thrombolysis [Figures 2 and 3]. If the flow was not restored at the end of the injections, another 2.5 L Urokinase was prepared and used. After recanalization, low-molecular-weight (LMW) heparin was administered for the next 2-3 days to prevent re-thrombosis due to the residual clot burden and also to manage the small risk of pulmonary embolism. The arteriovenous (AV) fistula/graft was ready to be used for dialysis almost on the same day.

## Conclusion

USG-guided needle-directed thrombolysis of AV fistula/grafts is a promising alternative to the catheter-directed thrombolysis. It can be done as an OPD procedure. A proper study is required to prove its safety and cost-effectiveness.

## References

1. Cooper SG. Original report. Pulse-spray thrombolysis of thrombosed hemodialysis grafts with tissue plasminogen activator. *AJR Am J Roentgenol* 2003;180:1063-6.
2. Bookstein JJ, Fellmeth B, Roberts A, Valji K, Davis G, Machado T. Pulsed-spray pharmacomechanical thrombolysis: Preliminary clinical results. *AJR Am J Roentgenol* 1989;152:1097-100.
3. Valji K, Bookstein JJ, Roberts AC, Oglevie SB, Pittman C, O'Neill MP. Pulse-spray pharmacomechanical thrombolysis of thrombosed hemodialysis access grafts: Long-term experience and comparison of original and current techniques. *AJR Am J Roentgenol* 1995;164:1495-503.

**Cite this article as:** Vikrama KA, Srivalli N, Venkataramana RS. USG-guided needle-directed pulse-spray pharmaco-mechanical thrombolysis of hemodialysis grafts/fistula: A novel technique. *Indian J Radiol Imaging* 2015;25:244-5.

**Source of Support:** Nil, **Conflict of Interest:** None declared.