

# Clinical outcomes of endovascularly managed iatrogenic renal hemorrhages

George Koshy Chiramel, Shyamkumar Nidugala Keshava, Vinu Moses, Nitin Kekre<sup>1</sup>, V Tamilarasi<sup>2</sup>, Anthony Devasia<sup>1</sup>

Departments of Radiology, <sup>1</sup>Urology, and <sup>2</sup>Nephrology, Christian Medical College, Vellore, Tamil Nadu, India

**Correspondence:** Dr. George Koshy Chiramel, Department of Radiology, Christian Medical College, Vellore - 632 004, Tamil Nadu, India. E-mail: gkchiramel@gmail.com

## Abstract

**Objective:** To evaluate the effectiveness of endovascular management in iatrogenic renal injuries with regard to clinical status on follow-up and requirements for repeat angiography and embolization. **Materials and Methods:** This retrospective study included patients who were referred for endovascular management of significant hemorrhage following an iatrogenic injury. Data was recorded from the Picture Archiving and Communication system (PACS) and electronic medical records. The site and type of iatrogenic injury, imaging findings, treatment, angiography findings, embolization performed, clinical status on follow-up, and requirement for repeat embolization were recorded. The outcomes were clinical resolution, nephrectomy, or death. Clinical findings were recorded on follow-up visits to the clinic. Statistical analysis was performed using descriptive statistics. **Results:** Seventy patients were included in this study between January 2000 and June 2012. A bleeding lesion (a pseudoaneurysm or arteriovenous fistula) was detected during the first angiogram in 55 patients (78.6%) and was selectively embolized. Fifteen required a second angiography as there was no clinical improvement and five required a third angiography. Overall, 66 patients (94.3%) showed complete resolution and 4 patients (5.7%) died. Three patients (4.3%) underwent nephrectomy for clinical stabilization even after embolization. There were no major complications. The two minor complications resolved spontaneously. **Conclusions:** Angiography and embolization is the treatment of choice in iatrogenic renal hemorrhage. Upto 20% of initial angiograms may not reveal the bleed and repeat angiography is required to identify a recurrent or unidentified bleed. The presence of multiple punctate bleeders on angiography suggests an enlarging subcapsular hematoma and requires preoperative embolization and nephrectomy.

**Key words:** Bleeding; embolization; endovascular management; iatrogenic renal hemorrhages; iatrogenic renal vascular injuries

## Introduction

Fifty percent of renal injuries are iatrogenic in etiology.<sup>[1,2]</sup> and 15% of all invasive procedures, either surgical or percutaneous, would result in a vascular injury.<sup>[3-5]</sup> Patients develop a significant drop in hematocrit, persistent hematuria, or an enlarging perirenal bleed causing loin pain. Some could develop altered renal function, urinary obstruction, hypertension, or cardiac failure.<sup>[6]</sup> Also, 70-90% of vascular injuries resolve spontaneously,<sup>[7]</sup> and treatment is

indicated for a massive bleed, deteriorating renal function, or renal hemorrhage which persists for more than 72 h.<sup>[7,8]</sup> The treatment of choice is endovascular, with angiography and selective embolization expected to minimize the loss of renal tissue.<sup>[9-17]</sup>

## Materials and Methods

This was a retrospective study that included patients referred

This is an open access article distributed under the terms of the Creative Commons Attribution-NonCommercial-ShareAlike 3.0 License, which allows others to remix, tweak, and build upon the work non-commercially, as long as the author is credited and the new creations are licensed under the identical terms.

**For reprints contact:** reprints@medknow.com

**Cite this article as:** Chiramel GK, Keshava SN, Moses V, Kekre N, Tamilarasi V, Devasia A. Clinical outcomes of endovascularly managed iatrogenic renal hemorrhages. *Indian J Radiol Imaging* 2015;25:380-90.

### Access this article online

#### Quick Response Code:



**Website:**  
www.ijri.org

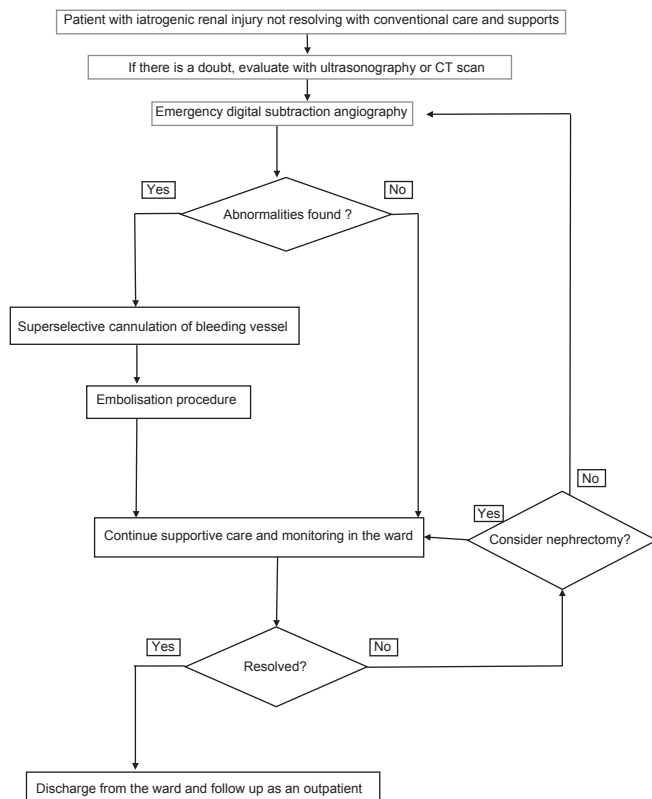
**DOI:**  
10.4103/0971-3026.169454

for endovascular management of severe hemorrhage following an invasive renal procedure. Institutional ethics committee clearance was obtained, and informed consent taken from all patients for the procedure. Data was retrieved from the Picture Archiving and Communication System (PACS), patients' charts, and electronic medical records. The information collected included the findings of angiography and embolization, technical details, clinical status, and findings on subsequent angiography, if performed. Technical success of embolization was defined as the complete occlusion of the target vessel with no residual bleed on angiography. Resolution was defined as clinical improvement with a stable hematocrit and no recurrence of bleed for at least 30 days. Adverse outcomes were nephrectomy and death. The clinical status and serum creatinine values were evaluated using the electronic health records of the patients, as they were followed up in the outpatient clinic. Statistical analysis was performed using descriptive statistics to calculate the means, proportions, and percentages.

#### Protocol followed for management of renal hemorrhage

The clinical algorithm for managing these patients is shown in Figure 1. Digital subtraction angiography was performed on an emergency basis in all patients (Multistar DSA; Siemens, Erlangen, Germany). The contrast agent in patients with a normal serum creatinine value was Iohexol (Omnipaque; GE Amersham Health, Princeton,

NJ, USA). If the serum creatinine level was between 1.5 and 3 mg%, Iodixanol (Visipaque; GE Amersham) was used. Carbon dioxide was used as the contrast agent in one patient who had a serum creatinine higher than 3.5 mg%. Computed tomography (CT) angiography was not performed routinely prior to endovascular treatment. A contrast-enhanced CT of the abdomen was also not part of the routine protocol, but was performed in a few patients if their condition did not resolve after embolization. An initial aortogram was performed to study the renovascular anatomy, identify anatomic variations, and detect a bleed from an intercostal or lumbar artery. Anteroposterior projections were used as a standard during the initial angiogram. An oblique projection was used if there was a doubt regarding the origin of the vessel leading to the bleeding lesion. Selective renal angiography of the suspected side of bleed was performed with a 4F hydrophilic cobra catheter (Terumo; Target Therapeutics, San Francisco, CA, USA). Additional selective angiography of the adjacent lumbar or lower intercostal arteries was also performed if an intrarenal bleed was not identified. If a bleeding vessel was identified, embolization was performed in the same session. The vessel was superselectively cannulated as close as possible to the site of bleed using a coaxially placed 2.7F microcatheter (Progreat; Terumo, Target Therapeutics, San Francisco, CA, USA). Embolization with coils (0.035") was performed through the cobra catheter itself in a few cases, if it was placed very close to the site of bleed. The embolization agents used depended on the site and characteristics of the bleeding lesion. Either 0.035" embolization coils (Cook, Bloomington, IN, USA) or 0.018" coils (Fibred microcoils, Target therapeutics, USA) were used. Polyvinyl alcohol particles (Contour; Boston Scientific, Marlborough, MA, USA) or gelfoam were used as adjuvants along with embolization coils in a few cases to reduce the blood flow through the vessel. If an arteriovenous fistula was visualized, *n*-butyl cyanoacrylate glue (Histoacryl; Bbraun, Tuttlingen, Germany) was the embolization material of choice [Table 1]. The management of these patients and the decisions were based on the clinical status and the clinical management protocol. During emergency angiography, if no obvious cause for the bleeding was identified and the patient remained hemodynamically unstable despite good supportive care, empirical embolization was performed at the iatrogenic trauma. If the patient was hemodynamically stable, supportive care with close monitoring was continued without empirical embolization.



**Figure 1:** Protocol followed for the management of iatrogenic renal injuries

#### Results

Over a period of 12 years, 70 patients (51 males and 19 females) were referred for endovascular management of a severe bleed secondary to an iatrogenic injury during various procedures. There were 18 percutaneous biopsies, 50 percutaneous nephrolithotomies, and 2 surgeries (a surgical renal biopsy and a partial nephrectomy) [Table 2]. These

**Table 1: Different types of bleeds and the preferred embolic agent for management**

Angiographic finding suggesting type of bleed	Preferred embolic agent
Pseudoaneurysm	Embolisation coils
Pseudoaneurysm with active extravasation	Coils and/or histoacryl glue
Multiple punctate bleeding vessels over the whole kidney	PVA particles
Arteriovenous or arteriovenous fistula	Histoacryl glue

PVA: Polyvinyl alcohol

**Table 2: The number and type of cases with iatrogenic injury in this study requiring angiography for embolization**

Gender	Cause of of iatrogenic injury			Total
	Biopsy	PCNL	Surgery	
Male	10	39	2	51
Female	8	11	0	19
Total	18	50	2	70

PCNL: Percutaneous nephrolithotomy

procedures were on the native kidney in 67 patients and on an allograft kidney in 3 patients. The average age was 41 years, the youngest being 7 months and the oldest being 70 years [Table 3]. The results of the angiography procedures and embolization are described as flowcharts [Figure 2a-c]. The first angiogram revealed an abnormality in 55 patients (78.6%). Embolization could not be performed in two as the segmental branch developed spasm during superselective cannulation. The spasm was persistent and the branch vessel became thrombosed. Both patients showed complete clinical resolution. Embolization was performed in the rest of the 53 patients of which 38 (71.7%) showed clinical resolution. Two patients died immediately after angiography before further treatment could be done. The angiograms in both these patients had shown multiple punctate bleeding vessels overlying the whole affected kidney for which the main renal artery was embolized with polyvinyl alcohol particles to reduce the bleeding. Thirteen patients (24.5%) who did not resolve hemodynamically after the first angiogram underwent a second angiogram the following day. One patient showed no abnormality and resolved spontaneously. Another showed a bleeding capsular artery but could not be selectively cannulated, and the patient expired before further treatment could be initiated. A second embolization procedure was carried out in 11 patients, of which 6 (54.5%) resolved. The condition of the remaining five did not resolve even though nephrectomy was performed in two patients. Also, all five patients underwent a third angiography. In the two post-nephrectomy patients, there were no abnormalities in both patients. One resolved spontaneously, while the other stabilized after empirical embolization of the overlying intercostal and lumbar arteries but expired in a month. Of the other three patients who underwent a third angiogram, one showed no abnormality and recovered

completely while another patient developed persistent spasm of the segmental vessel during superselective cannulation, but recovered completely. In the third patient, as the bleeding vessel could not be superselectively cannulated, nephrectomy was done after embolizing the renal artery with Histoacryl glue. This patient recovered completely after nephrectomy. Overall, no abnormality was revealed in the first angiogram in 15 (21.4%) patients. Of these, 12 (80%) recovered with conservative management. One patient underwent a second angiogram which revealed a pseudoaneurysm, and the condition resolved after selective embolization of the vessel. In two patients, empirical embolization with polyvinyl alcohol particles of the segmental branch leading to the site of injury was performed and both recovered completely. Follow-up was in the outpatient clinic. There was no recurrence of bleed on follow-up and no significant rise in serum creatinine levels. Overall, 66 (94.3%) out of 70 patients in this study showed complete resolution. Three (4.3%) underwent nephrectomy and four (5.7%) died. There were two minor complications - a subintimal dissection of a segmental branch and migration of a coil, both of which spontaneously resolved. There were no major complications.

## Discussion

A prior knowledge of the suspected site of renal injury helps to plan the imaging and treatment. The presence of hematuria indicates an intrarenal bleed with calyceal communication. In a patient with no hematuria, the bleed may be either within or outside the kidney. USG and color Doppler can demonstrate the presence of active bleeding into a perinephric hematoma and can be used as follow-up. The use of microcatheters for superselective cannulation and embolization of bleeding vessels helps to minimize the loss of renal tissue.<sup>[9-17]</sup> A bleed can sometimes be detected on the initial aortogram itself [Figure 3]. It may be visualized as an active extravasation of contrast, a pseudoaneurysm [Figure 4], or an arteriovenous or arteriovenous fistula [Figure 5]. Oblique projections and selective renal angiography can help identify the specific arterial branch [Figure 6] and rule out other lesions. Selective cannulation can help detect even subtle lesions. A limited amount of contrast agent is used as the renal function may already be compromised. An iso-osmolar contrast agent is preferred in a patient with raised serum creatinine. Other studies that have evaluated the efficacy of endovascular embolization in iatrogenic renal injuries have included fewer patients and describe only one angiography session, except one study that reports a 67% resolution rate with two angiography sessions.<sup>[13,18]</sup> The rate of resolution ranges from 85 to 98%.<sup>[19-21]</sup> Though none of these studies have described clinical outcomes on long-term follow-up or included patients who required a third angiography, their results were comparable to the 94.3% resolution achieved in our patient population. The

**Table 3: Details of all the patients included in this study who presented with an iatrogenic injury requiring angiography for potential embolization**

Patient details	Iatrogenic injury	Underlying disease/coagulopathy	Clinical presentation	Angiography findings	Embolisation material	Results	Further course in hospital	Final outcome
57/M	Biopsy	Renal failure	Hypotension and drop in hematocrit on the same day	Pseudoaneurysm	PVA particles and coils	Embolised	Improved	Stable on follow up
59/F	Biopsy	Renal failure	Hematuria for ten days	AVF	Coils	Embolised	Improved	Stable on follow up
20/M	Biopsy	Renal failure	Hematuria for five days	AVF	PVA particles and coils	Embolised	Improved	Stable on follow up
51/M	Biopsy	Renal failure	Hematuria for two days	Pseudoaneurysm and an AVF	Coils	Embolised	Improved	Stable on follow up
47/M	Biopsy	Renal failure and diabetes	Dropping hematocrit for three days	AVF	Histoacryl glue	Embolised	Improved	Stable on follow up
29/M	Biopsy	Renal failure and diabetes	Dropping hematocrit on the same day	No extravasation seen. Suspected pseudoaneurysm from an interpolar branch	PVA particles	Embolised but continued dropping hematocrit	Repeat angiogram did not show any abnormality	Improved after a day and stable on follow up
57/M	Biopsy	Renal failure	Dropping hematocrit on the same day	Pseudoaneurysm	PVA particles and coils	Embolised	Improved Nephrectomy done	Stable on follow up
30/M	Biopsy	Renal failure	Dropping hematocrit for a day	Pseudoaneurysm	Histoacryl glue	Embolised but bleeding continued. Two more embolisations of overlying intercostal and lumbar vessels with PVA particles and glue	Nephrectomy done and hematocrit stabilised	Developed DIC and aspiration pneumonia. Died after a month
58/M	Biopsy	Renal failure	Dropping hematocrit for six days	Multiple punctate subcapsular bleeders. Suspected extravasation	PVA particles	Embolised but significant bleed on same day	Developed seizures	Died
21/F	Biopsy	Renal failure and polyarteritis nodosa	Dropping hematocrit on the same day	Pseudoaneurysm	PVA particles and coils	Persistent bleed. Embolised overlying lumbar and capsular arteries with PVA and Histoacryl glue	Improved after second embolisation session	Stable on follow up
17/M	Biopsy	Renal failure	Dropping hematocrit for one day	Pseudoaneurysm from a capsular branch	Histoacryl glue	Did not improve. Second angiogram showed persistent bleed Could not cannulate	Planned for nephrectomy on the same day but developed DIC	Died
41/F	Biopsy of graft kidney	Protocol biopsy	Dropping hematocrit. Enlarging swelling on anterior abdominal wall for a day	AVF in the lower pole of the graft. Pseudoaneurysm from inferior epigastric artery	Coils, PVA, Histoacryl glue	Embolised circumflex iliac artery. But persistent bleed	Second angiography to embolised superior epigastric artery. Then stabilised	Stable on follow up
47/F	Biopsy	Renal failure	Dropping hematocrit on the same day	No bleeders found	None	No embolisation done	Stabilised spontaneously	Stable on follow up
23/F	Biopsy	Renal failure	Dropping hematocrit on the same day	AVF	None	Vasospasm on selective cannulation	Spontaneously thrombosed	Stable on follow up
36/M	Biopsy of graft	Protocol	Dropping hematocrit for a week	Pseudoaneurysm	PVA, coils	Embolised	Stabilised	Stable on follow up

*Contd...*

**Table 3: Contd...**

Patient details	Iatrogenic injury	Underlying disease/coagulopathy	Clinical presentation	Angiography findings	Embolisation material	Results	Further course in hospital	Final outcome
52/F	Biopsy	Renal failure	Dropping hematocrit on the same day	Pseudoaneurysm	PVA particles and coils	Embolised	Stabilised	Stable on follow up
53/F	Biopsy	Renal failure	Dropping hematocrit for one day	No bleeders found	PVA particles into lower pole	Embolised	Stabilised after a few days	Stable on follow up
50/M	Biopsy of graft	Protocol	Dropping hematocrit for one day	No bleeders found	None	No embolisation done	Stabilised	Stable on follow up
42/F	PCNL	Nephrolithiasis	Hematuria and dropping hematocrit for two days	Pseudoaneurysm from a lower pole branch	PVA particles and coils	Embolised	Stabilised after a few days	Stable on follow up
37/M	PCNL	Nephrolithiasis	Hematuria and dropping hematocrit for two days	No bleeders seen	None	No embolisation done	Stabilised	Stable on follow up
50/F	PCNL	Nephrolithiasis	Hematuria and dropping hematocrit for a day	No bleeders seen	None	No embolisation done	Stabilised	Stable on follow up
41/F	PCNL	Nephrolithiasis	Hematuria and dropping hematocrit on the same day	Pseudoaneurysm from a lower pole branch	Gelfoam and coils but did not stabilise	Second embolisation with PVA and coils. Third angiography showed spasm of intrarenal vessels and bleed from cortical branches	Stabilised after a few days	Stable on follow up
44/F	PCNL	Nephrolithiasis	Hematuria on the same day	No bleeders seen	None	No embolisation done	Stabilised	Stable on follow up
28/M	PCNL	Nephrolithiasis	Hematuria for sixteen days	Pseudoaneurysm from a segmental artery	Coils	Embolised	Stabilised	Stable on follow up
55/M	PCNL	Nephrolithiasis	Hematuria for fifteen days	First angiogram did not show any bleeders. Second angiogram showed a pseudoaneurysm	Coils	Embolised in second angiography session	Stabilised	Stable on follow up
48/M	PCNL	Nephrolithiasis	Hematuria for three days	Pseudoaneurysm from an interlobar artery	Coils	Embolised	Stabilised	Stable on follow up
41/M	PCNL	Nephrolithiasis	Hematuria for four days	Pseudoaneurysm from an interlobar artery	Gelfoam and coils	Embolised	Stabilised	Stable on follow up
26/F	PCNL	Nephrolithiasis	Dropping hematocrit for one day	Pseudoaneurysm and an AVF	Coils	Did not stabilise. Second angiography showed a pseudoaneurysm from another intrarenal artery. This was embolised with coils	Stabilised	Stable on follow up
38/M	PCNL	Nephrolithiasis	Hematuria on the same day	Pseudoaneurysm	Coils, PVA, Histoacryl glue	Embolised	Stabilised	Stable on follow up
49/M	PCNL	Nephrolithiasis	Dropping hematocrit for two days	Pseudoaneurysm and an AVF	Gelfoam and coils	Embolised	Stabilised	Stable on follow up
43/M	PCNL	Nephrolithiasis	Hematuria for seven days	Pseudoaneurysm	Coils	Embolised	Stabilised	Stable on follow up
53/M	PCNL	Nephrolithiasis	Bleeding from nephrostomy tube for four days	Pseudoaneurysm	Gelfoam and coils	Embolised	Stabilised	Stable on follow up

*Contd...*



**Table 3: Contd...**

Patient details	Iatrogenic injury	Underlying disease/coagulopathy	Clinical presentation	Angiography findings	Embolisation material	Results	Further course in hospital	Final outcome
60/M	PCNL	Nephrolithiasis	Dropping hematocrit for four days	First angiogram did not show any bleeders. Second angiogram showed a pseudoaneurysm and an AVF from an interlobar artery	Coils	Embolised on second angiography	Stabilised	Stable on follow up
31/M	PCNL	Nephrolithiasis	Hematuria for sixteen days	First angiogram showed a pseudoaneurysm from an interlobar branch	Gelfoam and coils	Did not stabilise. Second angiogram showed bleeding from another branch. Embolised with coils	Third angiogram did not show further bleeding. Stabilised	Stable on follow up
38/M	PCNL	Nephrolithiasis	Hematuria for a month	Pseudoaneurysm from a lower pole branch	Coils	Embolised	Stabilised	Stable on follow up
62/M	PCNL	Nephrolithiasis	Hematuria for eleven days	Pseudoaneurysm from an interpole branch	Coils	Embolised	Stabilised	Stable on follow up
26/M	PCNL	Nephrolithiasis	Bleeding for three days	Pseudoaneurysm from an interpole branch	Coils	Embolised	Stabilised	Stable on follow up
21/M	PCNL	Nephrolithiasis	Dropping hematocrit for two days	AVF from the T12 intercostal artery	Gelfoam and coils	Embolised	Stabilised	Stable on follow up
39/F	PCNL	Nephrolithiasis	Bleeding from nephrostomy tube for a day	Pseudoaneurysm from a lower pole branch	Coils	Embolised	Stabilised	Stable on follow up
48/M	PCNL	Nephrolithiasis	Bleeding from nephrostomy tube for two days	Pseudoaneurysm from a lower pole branch	Gelfoam and coils	Embolised	Stabilised	Stable on follow up
40/M	PCNL	Nephrolithiasis	Hematuria for seven days	Pseudoaneurysm from a lower pole branch	Gelfoam and coils	Embolised	Stabilised	Stable on follow up
17/M	PCNL	Nephrolithiasis	Bleeding for six days	Pseudoaneurysm from an interpole branch	Gelfoam and coils in two angiography sessions.	Third angiography to embolised the main renal artery with glue prior to nephrectomy	Stabilised	Stable on follow up
36/M	PCNL	Nephrolithiasis	Bleeding for a day	Extravasation seen from a lower pole branch	Coils and glue	Embolised	Stabilised	Stable on follow up
28/M	PCNL	Nephrolithiasis	Bleeding	Pseudoaneurysm and AVF seen in a lower segmental branch	Coils	Spasm and thrombosis of the subsegmental artery	Stabilised	Stable on follow up
47/M	PCNL	Nephrolithiasis	Bleeding for ten days	Pseudoaneurysm and AVF seen in a lower segmental branch	Coils	Embolised	Stabilised	Stable on follow up
61/M	PCNL	Nephrolithiasis	Bleeding for twenty days	Pseudoaneurysm and AVF seen in a lower segmental branch	Coils	Embolised	Stabilised	Stable on follow up
40/M	PCNL	Nephrolithiasis	Bleeding with drop in hematocrit for three days	Pseudoaneurysm seen in first angiogram	Embolised with PVA and coils	Second angiography showed an adjacent pseudoaneurysm and AVF. Embolised with Histoacryl glue	Stabilised after second embolisation	Stable on follow up
58/M	PCNL	Nephrolithiasis	Bleeding for twenty four days	Extravasation from a lower pole segmental branch	PVA and coils	Embolised	Stabilised	Stable on follow up
16/M	PCNL	Nephrolithiasis	Bleeding with drop in hematocrit for one day	Pseudoaneurysm seen from a lower pole branch	Glue	Embolised	Stabilised	Stable on follow up

*Contd...*

**Table 3: Contd...**

Patient details	Iatrogenic injury	Underlying disease/coagulopathy	Clinical presentation	Angiography findings	Embolisation material	Results	Further course in hospital	Final outcome
51/F	PCNL	Nephrolithiasis	Bleeding with drop in hematocrit for one day	No bleeders seen	None	No embolisation done	Stabilised	Stable on follow up
52/F	PCNL	Nephrolithiasis	Bleeding with drop in hematocrit for one day	Extravasation from a lower pole branch. Multiple punctate bleeders over the whole kidney	PVA	Embolisation of all the branches of the renal artery	Disseminated intravascular coagulopathy, urosepsis	Died
70/M	PCNL	Nephrolithiasis	Bleeding with drop in hematocrit for seven days	Three pseudoaneurysms seen from a lower pole branch	PVA and coils	Embolised	Stabilised	Stable on follow up
45/M	PCNL	Nephrolithiasis	Bleeding with drop in hematocrit on the same day	No bleeders seen	None	No embolisation done	Stabilised	Stable on follow up
55/M	PCNL	Grade 2 to 3 renal parenchymal changes	Bleeding for eleven days	Pseudoaneurysm and active bleed from a lower pole branch	PVA particles and coils	Embolised	Stabilised	Stable on follow up
56/F	PCNL	Diabetic nephropathy with a staghorn calculus	Bleeding with drop in hematocrit for nine days	Two pseudoaneurysms in two lower pole branches	Coils	Embolised	Stabilised	Stable on follow up
24/M	PCNL	Hemophilia	Bleeding with drop in hematocrit for one day	Pseudoaneurysm	Histoacryl glue	Embolised with 25% glue	Stabilised	Stable on follow up
46/M	PCNL	Large staghorn calculus	Bleeding with drop in hematocrit on the same day	No bleeders seen	None	No embolisation done	Stabilised	Stable on follow up
46/F	PCNL	Nephrolithiasis	Bleeding with drop in hematocrit for one day	No bleeders seen	None	No embolisation done	Stabilised	Stable on follow up
51/M	PCNL	Nephrolithiasis	Bleeding with drop in hematocrit for 64 days	No bleeders seen	None	No embolisation done	Stabilised	Stable on follow up
56/M	PCNL	Partial staghorn calculus	Bleeding with drop in hematocrit for 19 days	One pseudoaneurysm from a lower pole branch	Coils	Embolised	Stabilised	Stable on follow up
35/M	PCNL	Hemophilia B with bilateral nephrolithiasis and renal failure	Bleeding with drop in hematocrit for 8 days	CO2 angiography. Pseudoaneurysms in both kidneys	Embolised both pseudoaneurysms using gelfoam and coils in two sessions.	Third angiography did not show any bleeder. Single sided nephrectomy done	Stabilised after nephrectomy	Stable on follow up
33/M	PCNL	Nephrolithiasis	Bleeding for five days	Pseudoaneurysm	Coils	Embolised	Stabilised	Stable on follow up
40/M	PCNL	Nephrolithiasis	Bleeding for two days	Pseudoaneurysm and extravasation from a subsegmental artery	PVA and coils	Embolised	Stabilised	Stable on follow up
38/M	PCNL	Nephrolithiasis	Bleeding and dropping hematocrit for ten days	Pseudoaneurysm from an intersegmental branch	Gelfoam and 20% Histoacryl glue	Embolised	Stabilised	Stable on follow up
26/M	PCNL	Nephrolithiasis	Dropping hematocrit over two days	No bleeders seen	None	No embolisation done	Stabilised	Stable on follow up
32/M	PCNL	Nephrolithiasis	Dropping hematocrit over two days	Pseudoaneurysm and arteriovenous fistula seen from a lower pole branch	Branch developed spasm and thrombosed	No embolisation done	Stabilised	Stable on follow up

Contd...

Table 3: Contd...

Patient details	Iatrogenic injury	Underlying disease/disease/coagulopathy	Clinical presentation	Angiography findings	Embolisation material	Results	Further course in hospital	Final outcome
57/M	PCNL	Nephrolithiasis	Bleeding for two days	Pseudoaneurysm and arteriovenous fistula from a lower pole branch	Coils	Embolised	Stabilised	Stable on follow up
42/F	PCNL	Nephrolithiasis	Bleeding for two days	No bleeders seen	None	No embolisation done	Stabilised	Stable on follow up
25/M	Partial nephrectomy	Renal cyst with enhancing solid components	Bleeding and dropping hematocrit for eight days	No bleeders seen	None	No embolisation done	Stabilised	Stable on follow up
0.7/M	Surgical biopsy	Nephroblastoma	Bleeding and dropping hematocrit for one day	No bleeders seen. Only enhancing tumour	PVA particles and glue	Embolised the artery supplying the tumour	Stabilised	Stable on follow up

DIC: Disseminated intravascular coagulation, PVA: Polyvinyl alcohol, AVF: Arteriovenous fistula, PCNL: Percutaneous nephrolithotomy, M: Male, F: Female

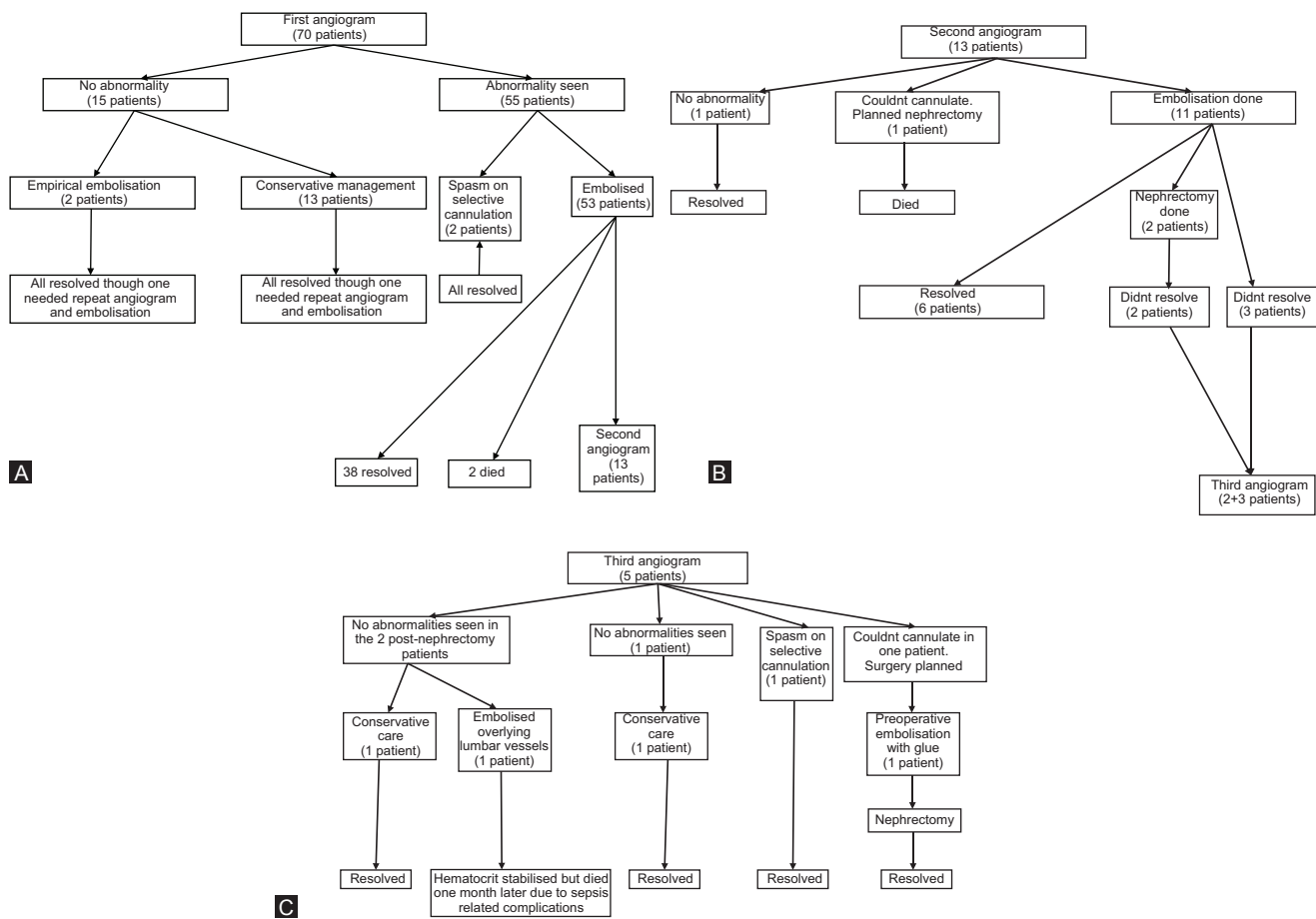


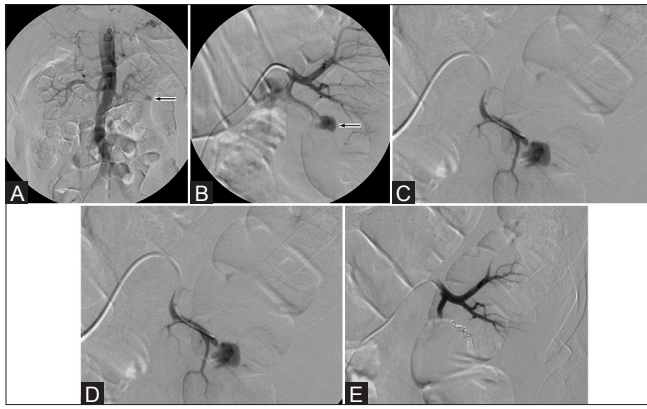
Figure 2(A-C): (A) Flowchart showing the number of patients, procedures performed, and the outcomes in the first (A), second (B) and third angiography sessions (C)

most common embolization material used in this study were embolization coils. Occasionally, polyvinyl alcohol particles were used as an adjuvant embolic material to reduce the flow. Histoacryl glue was used in a few cases where an arteriovenous fistula was seen. Other studies have used the same approach to manage renal hemorrhage. Some describe satisfactory results with only Histoacryl glue<sup>[22]</sup> or polyvinyl alcohol particles.<sup>[23]</sup> We have used only

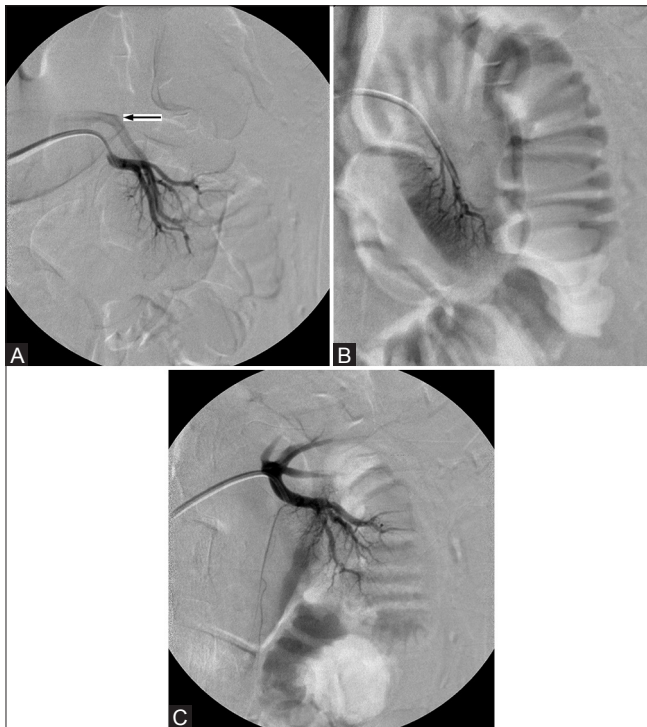
the transarterial approach for embolization in this group of patients. Other approaches that have been described are percutaneous ultrasound-guided embolization of a pseudoaneurysm with gelfoam<sup>[24]</sup> or embolization coils.<sup>[25]</sup>

It was found in this study that up to 20% of the initial angiograms did not show a bleed. This is lower compared to 30% as reported by another study.<sup>[26]</sup> An angiogram



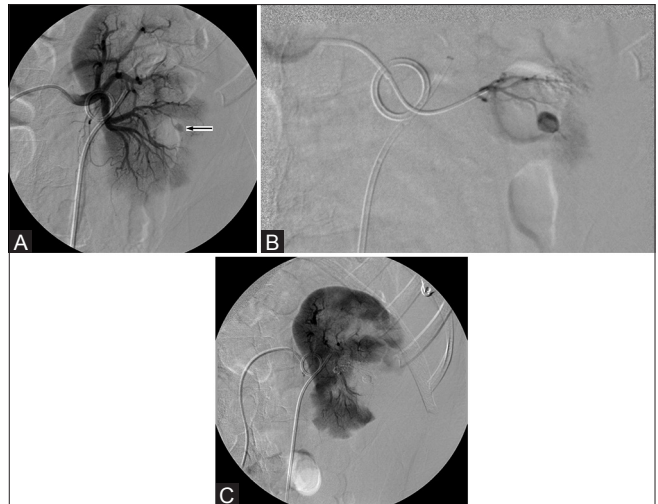

**Figure 3(A-E):** (A) Aortogram shows a pseudoaneurysm (arrow) in the lower pole of the left kidney (B) This was confirmed by a selective angiogram of the left renal artery (C) The lower segmental artery was superselectively cannulated with a microcatheter (D) Two 0.018" embolization coils were deployed (E) Post-embolisation angiogram shows complete occlusion of the branch

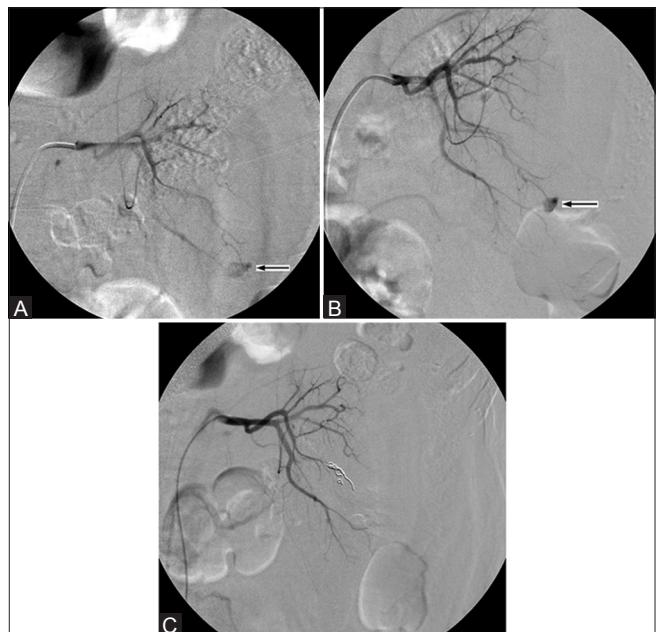


**Figure 5(A-C):** (A) Selective angiogram of the left renal artery shows an arteriovenous fistula in the lower pole region with a prominent draining vein (arrow) (B) Superselective cannulation of the arterial branch which developed spasm and thrombosis (C) Angiogram shows spontaneous resolution of the arteriovenous fistula with no opacification of the draining vein

could be negative immediately following an acute bleed. An angiogram could be falsely negative due to the tamponading effect of the hematoma or due to hypotension or transient spasm. Removal of the drainage tube in some cases could remove the tamponade and identify a bleed, thus helping to plan definitive treatment. An arteriocalyceal fistula may sometimes not be visualized if there is a blood clot obstructing the calyx.<sup>[7]</sup> The source of bleed may

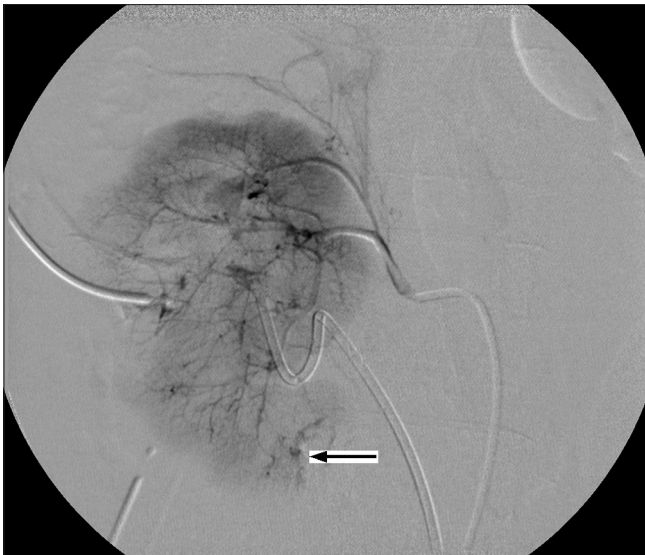


**Figure 4(A-C):** (A) Selective angiogram of the left renal artery shows a pseudoaneurysm (arrow) in the lower pole region. The large area seen as a filling defect is the surrounding hematoma (B) Superselective cannulation of this vessel and embolization with Histoacryl glue (C) Post-embolization angiogram shows occlusion of the vessel with no opacification of the pseudoaneurysm



**Figure 6(A-C):** (A) Left renal angiogram shows a pseudoaneurysm (arrow), but the arterial branch from which this arises is unclear (B) An oblique projection of the angiogram shows the pseudoaneurysm to be arising from a specific inter-polar branch (C) Embolization coils deployed within this branch to occlude it

sometimes not be identified even on repeated angiograms in a gradually worsening patient and a CT scan could be helpful in this situation. Selective empirical embolization can be helpful in an indeterminate bleed if the site of the renal injury is known, as in iatrogenic renal bleeds. In many situations, even when the bleed was not identified, the patient's condition resolved without further treatment, suggesting a process of spontaneous hemostasis. It is thus

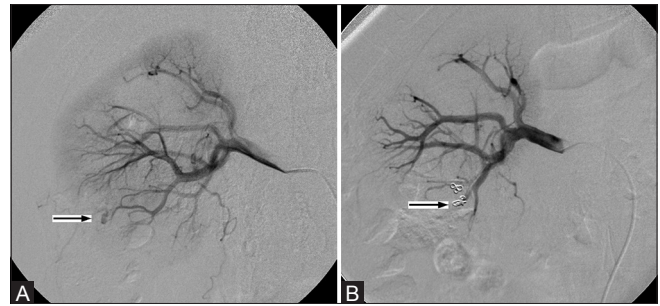


**Figure 7:** Right renal angiogram shows multiple punctate bleeding vessels (arrow) in all regions of the kidney, suggesting the presence of an enlarging subcapsular hematoma

important to evaluate and correct for any underlying coagulopathy. Two patients in this study were detected to have hemophilia. Recanalization of a bleeding vessel could be a cause for non-resolution that can persist even after embolization with coils or polyvinyl alcohol particles.

If the angiogram shows multiple punctate bleeding vessels [Figure 7] suggestive of an enlarging subcapsular hematoma,<sup>[27]</sup> a life-saving nephrectomy should be considered if the patient continues to be hemodynamically unstable. Preoperative embolization of the renal artery with Histoacryl glue may be helpful in an unstable patient while arrangements are being made for a nephrectomy. In the present study, all three patients who underwent nephrectomy were hemodynamically stable for more than a month. Only one patient died after a month in the intensive care unit due to complications related to seizures, aspiration pneumonia, and sepsis. Spasm and thrombosis of the bleeding branch vessel was inadvertently caused in three patients during superselective cannulation that resolved spontaneously [Figure 5]. This is a phenomenon that has also been described in the splanchnic territory.<sup>[28]</sup>

No major complications have been described in the literature. Minor complications include non-target glue embolization, coil migration, and renal artery occlusion.<sup>[26]</sup> Renal artery dissection is a previously described complication which resolves spontaneously.<sup>[10,29]</sup> Ureteric obstruction due to a migrated coil has also been described.<sup>[30]</sup> Non-target embolization can lead to post-embolization syndrome, hypertension,<sup>[2]</sup> and functional impairment of the kidney. None of the patients in this study developed post-embolization syndrome. The two minor complications which had occurred in this study, segmental artery dissection and coil



**Figure 8(A and B):** (A) Selective angiogram of the right renal artery showing a pseudoaneurysm (arrow) in the lower pole region for which embolization with coils was done (B) Post-embolization angiogram shows non-opacification of the pseudoaneurysm and migration of one of the coils into an adjacent arterial branch (arrow) resulting in non-target embolization

migration [Figure 8], had both resolved spontaneously.

## Conclusion

Angiography and selective embolization is safe and effective in iatrogenic renal vascular injuries. A second or a third angiogram is beneficial to detect an unidentified or recurrent bleed.

## Financial support and sponsorship

Nil.

## Conflicts of interest

There are no conflicts of interest.

## References

1. Poulakis V, Ferakis N, Becht E, Deliveliotis C, Duex M. Treatment of renal-vascular injury by transcatheter embolization: Immediate and long-term effects on renal function. *J Endourol* 2006;20:405-9.
2. Fisher RG, Ben-Menachem Y, Whigham C. Stab wounds of the renal artery branches: Angiographic diagnosis and treatment by embolization. *AJR Am J Roentgenol* 1989;152:1231-5.
3. Orons PD, Zajko AB. Angiography and interventional aspects of renal transplantation. *Radiol Clin North Am* 1995;33:461-71.
4. Hübsch PJ, Mostbeck G, Barton PP, Gritzmann N, Fruehwald FX, Schurawitzki H, *et al.* Evaluation of arteriovenous fistulas and pseudoaneurysms in renal allografts following percutaneous needle biopsy. Color-coded Doppler sonography versus duplex Doppler sonography. *J Ultrasound Med* 1990;9:95-100.
5. Sennet CA, Messersmith RN, Yousefzadeh DK, Thistlethwaite JR Jr. Percapsular and percutaneous embolization of renal transplant pseudoaneurysm and AV fistula: Case report. *Cardiovasc Intervent Radiol* 1989;12:270-3.
6. Maleux G, Messiaen T, Stockx L, Vanrenterghem Y, Wilms G. Transcatheter embolization of biopsy-related vascular injuries in renal allografts. Long-term technical, clinical and biochemical results. *Acta Radiol* 2003;44:13-7.
7. Huppert PE, Duda SH, Erley CM, Roth M, Lauchart W, Dietz K, *et al.* Embolization of renal vascular lesions: Clinical experience with microcoils and tracker catheters. *Cardiovasc Intervent Radiol* 1993;16:361-7.
8. Dorffner R, Thurnher S, Prokesch R, Bankier A, Turetschek K,

- Schmidt A, *et al.* Embolization of iatrogenic vascular injuries of renal transplants: Immediate and follow-up results. *Cardiovasc Intervent Radiol* 1998;21:129-34.
9. Somani BK, Nabi G, Thorpe P, McClinton S. Endovascular control of haemorrhagic urological emergencies: An observational study. *BMC Urol* 2006;6:27.
  10. Mavili E, Dönmez H, Ozcan N, Sipahioğlu M, Demirtaş A. Transarterial embolization for renal arterial bleeding. *Diagn Interv Radiol* 2009;15:143-7.
  11. Hellström PA, Mehik A, Talja MT, Siniluoto TM, Perala JM, Leinonen SS. Spontaneous subcapsular or perirenal haemorrhage caused by renal tumours. A urological emergency. *Scand J Urol Nephrol* 1999;33:17-23.
  12. Bookstein JJ, Goldstein HM. Successful management of postbiopsy arteriovenous fistula with selective arterial embolization. *Radiology* 1973;109:535-6.
  13. Vignali C, Lonzi S, Bargellini I, Cioni R, Petruzzi P, Caramella D, *et al.* Vascular injuries after percutaneous renal procedures: Treatment by transcatheter embolization. *Eur Radiol* 2004;14:723-9.
  14. Yeniyoğlu CO, Zeyrek N, Parıldar M, Selek E, Taşlı F, Memiş A. Life-threatening hematuria in a patient with renal angiomyolipoma and selective renal embolization prior to nephrectomy. *Int Urol Nephrol* 2002;34:185-8.
  15. Lovaria A, Nicolini A, Merzagaglia D, Saccheri S, Rivolta R, Rampoldi A, *et al.* Interventional radiology in the treatment of urological vascular complications. *Ann Urol (Paris)* 1999;33:156-67.
  16. Hom D, Eiley D, Lumerman JH, Siegel DN, Goldfischer ER, Smith AD. Complete renal embolization as an alternative to nephrectomy. *J Urol* 1999;161:24-7.
  17. Lupattelli T, Garaci FG, Manenti G, Belli AM, Simonetti G. Giant high-flow renal arteriovenous fistula treated by percutaneous embolization. *Urology* 2003;61:837.
  18. Huber J, Pahernik S, Hallscheidt P, Sommer CM, Wagener N, Hatiboglu G, *et al.* Selective transarterial embolization for posttraumatic renal hemorrhage: A second try is worthwhile. *J Urol* 2011;185:1751-5.
  19. Jain V, Ganpule A, Vyas J, Muthu V, Sabnis RB, Rajapurkar MM, *et al.* Management of non-neoplastic renal hemorrhage by transarterial embolization. *Urology* 2009;74:522-6.
  20. Perini S, Gordon RL, LaBerge JM, Kerlan RK Jr, Wilson MW, Feng S, *et al.* Transcatheter embolization of biopsy-related vascular injury in the transplant kidney: Immediate and long-term outcome. *J Vasc Interv Radiol* 1998;9:1011-9.
  21. Sam K, Gahide G, Soulez G, Giroux MF, Oliva VL, Perreault P, *et al.* Percutaneous embolization of iatrogenic arterial kidney injuries: Safety, efficacy, and impact on blood pressure and renal function. *J Vasc Interv Radiol* 2011;22:1563-8.
  22. Cantasdemir M, Adaletli I, Cebi D, Kantarci F, Selcuk ND, Numan F. Emergency endovascular embolization of traumatic intrarenal arterial pseudoaneurysms with N-butyl cyanoacrylate. *Clin Radiol* 2003;58:560-5.
  23. Davidson GS, Terbrugge KG. Histologic long-term follow-up after embolization with polyvinyl alcohol particles. *AJNR Am J Neuroradiol* 1995;16(Suppl):843-6.
  24. Sakr MA, Desouki SE, Hegab SE. Direct percutaneous embolization of renal pseudoaneurysm. *J Endourol* 2009;23:875-8.
  25. Cowan NC, Traill ZC, Phillips AJ, Gleeson FV. Direct percutaneous transrenal embolization for renal artery injury following percutaneous nephrostomy. *Br J Radiol* 1998;71:1199-201.
  26. Phadke RV, Sawlani V, Rastogi H, Kumar S, Roy S, Baijal SS, *et al.* Iatrogenic renal vascular injuries and their radiological management. *Clin Radiol* 1997;52:119-23.
  27. Axelrod DJ, Freeman H, Pukin L, Guller J, Mitty HA. Guide wire perforation leading to fatal perirenal hemorrhage from transcortical collaterals after renal artery stent placement. *J Vasc Interv Radiol* 2004;15:985-7.
  28. Cynamon J, Atar E, Steiner A, Hoppenfeld BM, Jagust MB, Rosado M, *et al.* Catheter-induced vasospasm in the treatment of acute lower gastrointestinal bleeding. *J Vasc Interv Radiol* 2003;14:211-6.
  29. Corr P, Hacking G. Embolization in traumatic intrarenal vascular injuries. *Clin Radiol* 1991;43:262-4.
  30. Rajesparan K, Partridge W, Taha N, Samman R, Aldin Z. Early migration and ureteric obstruction of an embolisation coil used to treat massive haemorrhage following percutaneous nephrolithotomy. *Cardiovasc Intervent Radiol* 2011;34:868-72.