

Use of a vascular sheath for introduction of radiofrequency ablation probe during radiofrequency ablation of osteoid osteoma

Munawwar Ahmed, Shyamkumar N Keshava, Vinu Moses, Suraj Mammen, Korula Mani Jacob¹, Vrisha Madhuri¹

Departments of Radiology, and ¹Orhtopaedics, Paediatrics Orhtopaedics Unit, Christian Medical College, Vellore, Tamil Nadu, India

Correspondence: Dr. Munawwar Ahmed, Department of Radiology, Christian Medical College, Vellore - 632 004, Tamil Nadu, India.
E-mail: munawwarahmed19@yahoo.co.in

Abstract

Radiofrequency ablation (RFA) has now become a preferred treatment option for osteoid osteoma. Accurate placement of RFA probe into the nidus of osteoid osteoma is important for good clinical outcome. Various methods and techniques have been described in the literature available. We describe the technique of using a vascular access sheath for introduction of RFA probe after bone drilling, which prevents loss of access to drill track and also serves as a pathway for accurate placement of RFA probe, thereby reducing the risk of damage to the RFA probe tip itself and the surrounding soft tissue.

Key words: Computed tomography scan; osteoid osteoma; radiofrequency ablation

Introduction

Osteoid osteoma (OO) is a benign bone tumor mostly occurring in adolescents or young adults.^[1] It is radiographically characterized by dense sclerosis surrounding a small radiolucent nidus.^[1] Radiofrequency ablation (RFA) has now become a preferred treatment option. Compared to surgery, it is less invasive and morbid and requires shorter hospital stay with earlier weight bearing. RFA causes thermal coagulation necrosis of the tumor nidus.^[1,2] Clinical outcome depends on the complete thermal necrosis of the nidus, which in turn largely depends on the accurate placement of RFA probe

into the nidus.^[1] Various techniques have been described for the localization of nidus, guidance and tracking for placement of the RFA probe.^[1-3] Many of these techniques have been described using commercially available introduction systems such as RITA StarBurst Hard Tissue Access System (AngioDynamics, Inc., GA, USA).^[2,3] RFA probe is introduced into the nidus after drilling through the cortex of the bone. However, introduction of RFA probe without any introduction system, even on computed tomography (CT) guidance, is often difficult and time consuming due to small diameter of the drill track, and also involves the risk of injury to the surrounding soft tissue or damage to the RFA probe tip itself. Vascular sheath for RFA was earlier used by Mahnken *et al.* in their two series.^[4,5] They introduced the sheath before drilling to secure the drill track and protect the surrounding soft tissue. Details of the technique of introduction of vascular sheath before drilling were not mentioned in their series. We describe a technique using a vascular sheath for accurately introducing the RFA probe into the nidus after drilling the bony cortex under conventional CT guidance.

Access this article online

Quick Response Code:



Website:
www.ijri.org

DOI:
10.4103/0971-3026.169460

Technique

We did a retrospective analysis of 14 cases (12 males and 2 females, age range 6-23 years, mean 14.1 years) where we employed this technique, mostly in deeply located lesions [Table 1]. Biopsy of the nidus was not done and diagnosis of OO was established by characteristic clinical and radiographic features. Complete ablation of the nidus was achieved in all the cases without any recurrence of pain in the follow-up period (range 1-18 months; mean 8.2 months). There was no complication encountered in our small series. In one case, while inserting the RFA probe, there was perforation of the sheath with displacement of needle through the perforation into the soft tissue track. The probe was pulled out and reinserted.

We used conventional CT guidance (single slice SOMATOM Emotion; Siemens, Erlangen, Germany), a manual (Aesculap Inc.-B Braun, Center Valley, PA) or battery-operated (Stryker Corp., Kalamazoo, MI) bone drill machine with cannulated drill bit (2.5-4.5 mm) (Zimmer, Warsaw IN), a commercially available RITA SDE StarBurst probe (17 gauge, 2 cm diameter, 12 cm; Angiodynamics, Inc., GA, USA), and generator (Model 1500X; Angiodynamics, Inc., GA, USA) for RFA. Ablation was for 5 min at a target temperature of 90°C. Technique is described in the following steps.

Step 1. Localization of nidus of OO and drilling

Formal informed consent was obtained before the procedure from the patient or the patient's legal guardian if the patient was a minor. Patient was placed in an appropriate position on the CT scan table after administering general anesthesia. After initial topogram with a radio-opaque marker on the skin surface, limited CT scan of the area of interest was taken

with 3 mm slice thickness. Nidus of the OO was localized, and depth, trajectory, and angle for bone drilling from skin surface were assessed on the CT scan workstation. Drilling track through the neurovascular bundle was avoided. Skin surface was marked, prepared with betadine 10% solution, and draped. We took the help of an orthopedic surgeon for bone drilling. Intermittent limited CT scan cuts were taken for guiding the drilling in correct direction and depth.

Step 2. Exchange of drill bit with vascular sheath

After drilling in appropriate trajectory and depth immediately posterior to the nidus, manual or battery-operated drill machine was separated keeping the cannulated drill bit *in situ* [Figure 1a]. Back and stiff end of a short (80 cm), 0.035-inch Amplatz guidewire (Cook Inc., Bloomington, IN, USA) was introduced through the cannulated drill bit. Drill bit was removed keeping the Amplatz guidewire *in situ*. Now a 5 or 6 F, short (11 cm) vascular access sheath (AVANTI+; Cordis Corp., FL, USA) (along with its dilator), cut and separated from its hub [Figure 1b], was introduced into the drilled bony track over the Amplatz guidewire [Figure 1c].

Step 3. Introduction of RFA probe

Amplatz guidewire and sheath dilator were removed and the RFA probe was introduced without difficulty directly into the nidus through the vascular introduction sheath [Figure 1d]. Limited CT scan cuts were taken to confirm the exact position of the probe tip in the nidus [Figure 1e]. After confirming the position of the probe in the nidus, the sheath was withdrawn 2-3 cm, and in some cases, it was cut longitudinally and peeled away. RFA electrodes were deployed in the nidus and ablation completed by connecting it to generator after placing dispersion electrode pads.

After completion of the ablation, the probe was removed and post procedure CT scan was done. Skin puncture was closed and dressed with adhesive bandage. All the patients were followed up on the same day in the ward and were discharged the next day. They were seen in the OPD within 1 week post procedure. Non-weight-bearing and avoidance of sports or strenuous work on the treatment side were advised for 4-6 weeks. Oral analgesics and prophylactic antibiotics were advised for 3-7 days post procedure.

Discussion

Accurate placement of RFA probe into the nidus of OO is important for good clinical outcome. Various methods and techniques have been described for RFA probe guidance and introduction, including 14 G bone penetration cannula with stylet for introduction of biopsy needle and RFA probe, Bonoptoy coaxial bone biopsy system (Radi Medical Systems, Uppsala, Sweden), along with dedicated Sluyter-Mehta 20 G thermal ablation cannula (Radionics, Burlington,

Table 1: List of patients evaluated including location of OO and follow up

Age in years/sex	Site of osteoid osteoma	Follow-up in months
17/male	Right calcaneum cortex near sustentaculum tali	18
11/male	Right femur neck posterior cortex	18
10/male	Left femur neck medulla	1
3/male	Right anterior glenoid cortex	2
9/male	Right femoral neck posterior cortex	15
20/male	Right femur neck inferior cortex	14
6/male	Left femur neck inferior cortex	12
18/female	Left femur neck inferior cortex	6
12/male	Left femur neck anterior cortex	8
18/female	Left lateral femoral condyle medulla	9
18/male	Right proximal femur posterior cortex	5
23/male	Left proximal femur anterior cortex	4
12/male	Left femur neck posterior cortex	1
11/male	Right proximal femur anterior cortex	1

OO: Osteoid osteoma

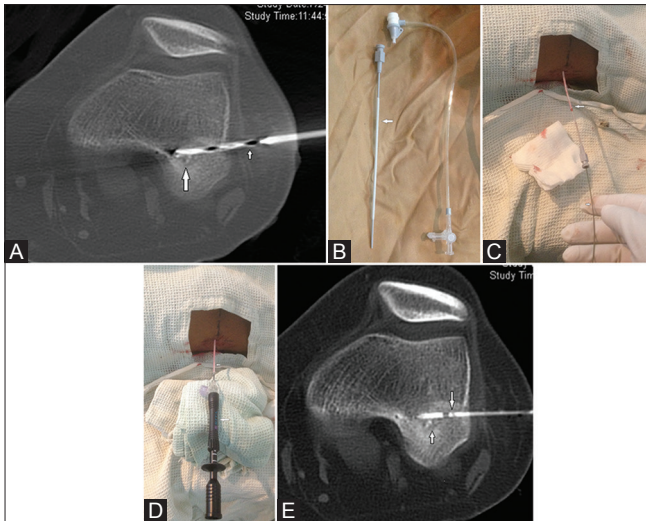


Figure 1(A-E): (A) Drill bit (small arrow) in the nidus (large arrow) of the OO in lateral condyle of the femur. (B) Vascular access sheath with dilator (arrow) cut and separated from its hub. (C) Vascular access sheath along with dilator (arrow) introduced into the nidus over Amplatz wire (small arrow). (D) RFA probe (large arrow) was introduced through the vascular access sheath (small arrow) into the nidus after removing Amplatz guidewire and dilator. (E) Axial CT image shows RFA probe (large arrow) in the nidus (small arrow) of OO

MA), and RITA StarBurst Hard Tissue Access System.^[1-3,6,7] Bonoptoy bone biopsy system consists of a 14-G and 95-mm-long penetration cannula that allows a 15-G drill and bone biopsy needle and introduction of a 20-G, 145-mm-long RFA cannula and probe through it.^[4] RITA StarBurst Hard Tissue Access System also consists of an 11 G cannula and a stylet.^[2,3] RFA probe is introduced through the cannula after removing the stylet. Penetration cannula helps in access to nidus and serves as a pathway for introduction of drill, biopsy needle, and RFA probe.^[1,6] Some authors have used Jamshidi or Ackermann bone biopsy needle to gain access to the nidus, which is again a coaxial system consisting of an outer cannula and a trocar, and the RFA probe is inserted through the outer cannula into the nidus after biopsy.^[8] All the above techniques use outer cannula as a coaxial system, which prevent loss of access to the bony track and allows introduction of biopsy needle and RFA probe. Although commercially available introduction systems can be used to introduce the probe precisely into the nidus.^[2,3,6,7] these increase the cost of the procedure and are therefore not commonly used.

Mahnken *et al.*,^[4,5] in their series, placed an introducer vascular sheath before drilling close to the cortical bone to protect the soft tissue and to secure the drill track. Drilling

and RFA were done through the sheath. The sheath was placed in the soft tissue and not inserted into the bony track. The sheath was used without cutting and separating the hub. Our technique is different in that we placed the vascular sheath after the bone drilling and inserted it into the bony track. Since the sheath was inserted into the bony track, it was withdrawn before RFA. Hub of the sheath was cut and separated for easy removal of the sheath after the introduction of RFA probe.

In conclusion, use of a vascular sheath during RFA of OO can be a good alternative to other available introduction systems. It secures access to drill track and serves as a pathway for accurate placement of RFA probe, thereby reducing the risk of damage to the RFA probe tip itself and the surrounding tissues.

References

1. Motamedi D, Learch TJ, Ishimitsu DN, Motamedi K, Katz MD, Brien EW, *et al.* Thermal ablation of osteoid osteoma: Overview and step by-step guide. *Radiographics* 2009;29:2127-41.
2. Busser WM, Hoogeveen YL, Veth RP, Schreuder HW, Balguid A, Renema WK, *et al.* Percutaneous radiofrequency ablation of osteoid osteomas with use of real-time needle guidance for accurate needle placement: A pilot study. *Cardiovasc Intervent Radiol* 2011;34:180-3.
3. Mylona S, Patsoura S, Galani P, Karapostolakis G, Pomoni A, Thanos L. Osteoid osteomas in common and in technically challenging locations treated with computed tomography-guided percutaneous radiofrequency ablation. *Skeletal Radiol* 2010;39:443-9.
4. Mahnken AH, Bruners P, Delbrück H, Günther RW. Radiofrequency ablation of osteoid osteoma: Initial experience with a new monopolar ablation device. *Cardiovasc Intervent Radiol* 2011;34:579-84.
5. Mahnken AH, Tacke JA, Wildberger JE, Günther RW. Radiofrequency ablation of osteoid osteoma: Initial results with a bipolar ablation device. *J Vasc Interv Radiol* 2006;17:1465-70.
6. Pinto CH, Taminiau AH, Vanderschueren GM, Hogendoorn PC, Bloem JL, Obermann WR. Technical considerations in CT-guided radiofrequency thermal ablation of osteoid osteoma: Tricks of the trade. *AJR Am J Roentgenol* 2002;179:1633-42.
7. Donkol RH, Al-Nammi A, Moghazi K. Efficacy of percutaneous radiofrequency ablation of osteoid osteoma in children. *Pediatr Radiol* 2008;38:180-5.
8. Cantwell CP, Obyrne J, Eustace S. Current trends in treatment of osteoid osteoma with an emphasis on radiofrequency ablation. *Eur Radiol* 2004;14:607-17.

Cite this article as: Ahmed M, Keshava SN, Moses V, Mammen S, Jacob KM, Madhuri V. Use of a vascular sheath for introduction of radiofrequency ablation probe during radiofrequency ablation of osteoid osteoma. *Indian J Radiol Imaging* 2015;25:365-7.

Source of Support: Nil, **Conflict of Interest:** None declared.