

# Endovascular treatment of central venous obstruction as a complication of prolonged hemodialysis - Preliminary experience in a tertiary care center

Mukesh K Yadav, Madhurima Sharma, Anupam Lal, Vivek Gupta, Ashish Sharma<sup>1</sup>, Niranjan Khandelwal

Departments of Radiodiagnosis and Imaging, and <sup>1</sup>Transplant Surgery, Post Graduate Institute of Medical Education and Research, Chandigarh, Punjab and Haryana, India

**Correspondence:** Dr. Mukesh K Yadav, Department of Radiodiagnosis and Imaging, Post Graduate Institute of Medical Education and Research, Chandigarh - 160 012, Punjab and Haryana, India. E-mail: mukeshyadav11@gmail.com

## Abstract

**Background:** Central venous disease is a serious complication in patients undergoing hemodialysis, often presenting with symptoms of venous hypertension. Treatment is aimed to provide symptomatic relief and to maintain hemodialysis access site patency. **Aim:** To describe our initial experience in the endovascular treatment of central venous stenosis or obstruction in patients undergoing hemodialysis. **Settings and Design:** This was a retrospective study carried out in a tertiary care center. Study duration was 24 months. Follow-up was variable. **Materials and Methods:** Eleven patients of chronic renal failure undergoing hemodialysis presented with central vein stenosis or obstruction having ipsilateral vascular access, between July 2012 and July 2014. All the patients underwent endovascular treatment and were analyzed retrospectively. **Results and Conclusion:** A total of 11 patients (4 male and 7 female) underwent 18 interventions for 13 stenotic segments during a time period of 2 years. Eight stenotic segments were in brachiocephalic vein, three in subclavian vein, and two in axillary veins. The technical success rate for endovascular treatment was 81.8%. Two patients underwent percutaneous transluminal angioplasty (PTA) alone and presented with restenosis later. Balloon angioplasty followed by stenting was done in seven patients, two of which required reintervention during follow-up. We found endovascular treatment safe and effective in treating central venous disease.

**Key words:** Angioplasty; central venous stenosis; endovascular; hemodialysis; stenting

## Introduction

Central venous stenosis and obstruction is a major concern in patients undergoing prolonged hemodialysis causing significant morbidity with access site dysfunction. Central venous disease (CVD) has been defined as 50% or greater stenosis involving the internal jugular, subclavian, or axillary veins.<sup>[1]</sup> Incidence of central venous stenosis is 25-40%.<sup>[2,3]</sup>

The main causes of central venous stenosis in hemodialysis patients are prolonged central venous catheterization and high-flow status in arteriovenous fistula (AVF) or graft, subsequently causing venous intimal hyperplasia and stenosis.<sup>[2,4]</sup> Clinically, central venous stenosis manifests as ipsilateral arm or neck swelling, elevated venous pressure during hemodialysis, and failure of hemodialysis access.

This is an open access article distributed under the terms of the Creative Commons Attribution-NonCommercial-ShareAlike 3.0 License, which allows others to remix, tweak, and build upon the work non-commercially, as long as the author is credited and the new creations are licensed under the identical terms.

**For reprints contact:** reprints@medknow.com

**Cite this article as:** Yadav MK, Sharma M, Lal A, Gupta V, Sharma A, Khandelwal N. Endovascular treatment of central venous obstruction as a complication of prolonged hemodialysis – Preliminary experience in a tertiary care center. *Indian J Radiol Imaging* 2015;25:368-74.

### Access this article online

#### Quick Response Code:



**Website:**  
www.ijri.org

**DOI:**  
10.4103/0971-3026.169463

The aim of the treatment is to provide symptomatic relief to the patients while preserving the function of AVF.<sup>[5]</sup>

Surgical and endovascular treatments are available for treatment of central venous stenosis. However, the optimal treatment is yet to be determined. Though high primary patency rates (80-90% at 1 year) have been reported with open surgical repair of the central veins,<sup>[6]</sup> it carries a high rate of postoperative morbidity and mortality. Endovascular management has been widely accepted as the modality of choice for treatment of central venous stenosis.<sup>[7-9]</sup> Endovascular treatment options include percutaneous transluminal angioplasty (PTA), bare metal stent or covered stent placement. The optimal endovascular treatment, however, remains unclear, with no clear advantage of primary stent placement in comparison to angioplasty.<sup>[10-12]</sup> The National Kidney Foundation Disease Outcomes Quality Initiative guidelines<sup>[13]</sup> have recommended angioplasty as the preferred treatment for CVD, with or without stent placement. In this retrospective study, we evaluated the outcomes of balloon angioplasty and stenting for management of central venous stenosis or occlusion in patients undergoing hemodialysis.

## Materials and Methods

This was a retrospective study approved by the departmental ethical committee. Informed written consent was obtained from all the patients. A total of 11 patients with central venous stenosis or occlusion underwent endovascular treatment in the department of radiodiagnosis. All the patients were on hemodialysis for chronic renal failure under the renal transplant surgery department of our institute. Mean duration of dialysis before the intervention was 2.5 years (range: 3 months-4.5 years). All 11 cases had autogenous AVF for dialysis access.

Indications for treatment were excessive swelling in the arm, decreasing flow during dialysis session, and pronged bleeding after cannulation. Pre-procedure contrast-enhanced CT (CECT) was done in all patients for objective documentation and extent of lesion. Due to deranged renal functions, CECT (Somatom Definition Flash, Siemens, Erlangen, Germany) was planned 24 h before the dialysis session. Average amount of contrast (Omnipaque, GE healthcare, USA) given was 60 ml. Pre-procedure CECT also helped in deciding upon the length and diameter of hardware required for the intervention. If acute thrombosis was found on CT, a change in treatment plan was made.

In all the patients, a preliminary diagnostic venography was performed with digital subtraction angiography (GE Healthcare, USA). Location, length, and extent of stenosis/obstruction were assessed. Endovascular interventions were performed in the same sitting. Venous access was obtained through cephalic vein in three cases.

In two cases, antegrade venous puncture was done through common femoral vein. In the remaining six cases, a combined approach using both cephalic and common femoral veins was used. Though approach through cephalic vein was preferred, femoral venous puncture was used to obtain access in difficult cases. After obtaining the access, the access site was secured using short 7F sheath (compatible with balloon and stent placement). A long sheath was used in cases of femoral approach to avoid traversing through the heart repeatedly.

The stenotic site was traversed using a 0.035-inch hydrophilic guidewire (Terumo, NJ, USA). For some hard obstructing lesions, the stiff end of the guidewire was also used. Microcatheter and microguidewire assembly was also used to negotiate through difficult lesions. Diagnostic catheters like Picard (Cook Inc., Bloomington, IN, USA) and multipurpose catheters were used. Microcatheter was also used in some cases (Progreat; Terumo, NJ, USA). After traversing the lesion, hydrophilic guidewire was replaced by exchange length stiff guidewire (Amplatz; Boston scientific, Marlborough, USA) and PTA was performed subsequently. PTA balloon diameter ranged from 10 to 14 mm with burst pressures between 20 and 25 atmosphere. Length of the balloons ranged from 4 to 8 cm. The various balloons used were: Evercross (eV3 endovascular Inc., USA), Conquest (Bard Inc., USA), and Advance (Cook Inc., Bloomington, USA). A balloon having diameter of 1-2 mm larger than the adjacent normal vein was selected and angioplasty was done by inflating the balloon for 15-20 min.

Stenting was performed if greater than 50% residual stenosis was present after PTA. In seven patients, PTA was followed by stent placement in the same setting. The diameter of the stent was the same as the adjacent normal vein. In all cases, bare metallic stents were used: Protege (eV3) and Luminex stent (Bard Inc.). Stent diameters ranged from 12 to 14 mm, with length ranging from 6 to 8 cm.

Technical success was defined as procedure without significant residual stenosis or without complications. Technical failure was defined as inability to cross/dilate the lesion or significant residual stenosis (>30%). A complication was defined as any event which is not routinely observed after the procedure, requiring treatment with endovascular or surgical intervention. Follow-up was censored for patient death, loss to follow-up, and closure or occlusion of the ipsilateral vascular access.

## Results

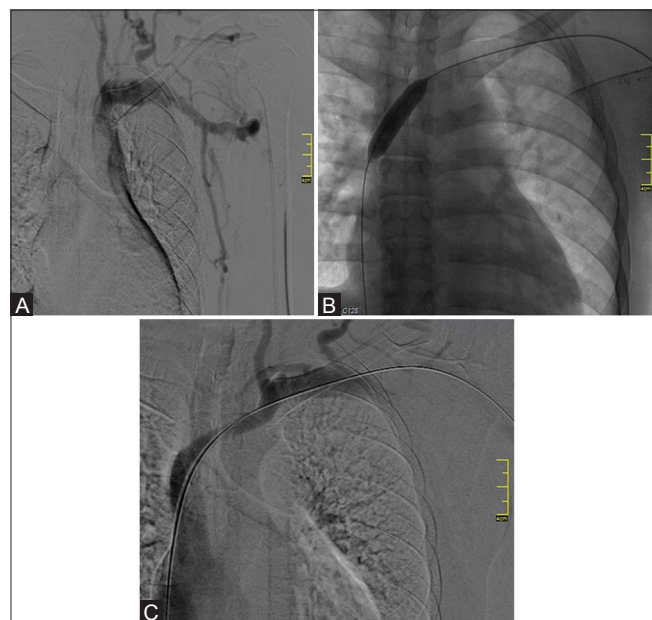A total of 11 patients underwent 18 interventions for endovascular treatment of CVD. The study comprised 4 men and 7 women with a mean age of 46 years (range, 25-73 years). Six patients had involvement of right-sided venous system and five patients had involvement of the left side. More than one segment was involved in two patients. A

total of 13 diseased segments were identified with complete occlusion in 8 segments and stenosis in 5 segments. Eight diseased segments were identified in brachiocephalic vein (five in left and three in right), three in subclavian vein (right), and two in axillary veins (one each in left and right). Average number of interventions performed on each diseased venous segment was 1.38. The length of the stenotic segment was 1-3 cm in five patients and 3-5 cm in five patients. One patient had long segment involvement of >5 cm.

Technical success was achieved in 81.8% cases (9/11). In two patients, the occluded segment could not be negotiated. There was localized tear while negotiating the guidewire through the occluded segment, resulting in contrast extravasation. The procedure was abandoned at this point. Repeat venograms done in these patients showed spontaneous cessation of extravasation, thus obviating the need for further intervention to stop bleeding.

In the remaining nine cases, only PTA was done in two cases (22.22%) [Figures 1 and 2]. In seven cases (77.77%), balloon angioplasty with stenting was done in the same setting. Symptomatic improvement was reported in all the patients with no major periprocedural morbidity or mortality. Complete coverage of the stenotic segment could not be achieved in one case [Figure 3].

Early complications encountered were local extravasation in two cases (following which the procedure was abandoned)



**Figure 1(A-C):** A 37-year-old male with AVF in the left arm presented with swelling of left arm and face. (A) Initial diagnostic venogram showed complete occlusion of left brachiocephalic vein with presence of collaterals (B) PTA was performed using 12 × 40 mm balloon (C) Post PTA venogram showed normal filling of left brachiocephalic vein. Patient presented with restenosis after 5 months and was treated with repeat PTA

[Figure 4] and incomplete coverage of the stenotic segment in one case [Figure 3b]. Late complications encountered were: In-stent stenosis [Figure 2f], edge stenosis [Figure 3c], and stent fracture [Figure 5].

Two patients died during follow-up at 4 and 5 months after the intervention, respectively. Both the patients had associated co-morbidities in the form of multiple myeloma, dilated cardiomyopathy, and hypothyroidism in one patient and diabetes mellitus with myocardial infarction in the other patient.

Both the patients who were treated with PTA alone presented with restenosis (at 5 and 2 months after the first intervention, respectively). Mean intervention-free period was 3.5 months. Repeat PTA was done in one patient. In the second patient, angioplasty was followed by stenting. Among seven patients who underwent PTA with stenting, reintervention was required in three cases (42.86%). Mean intervention-free period in these patients was 4.33 months. On repeat angiographic evaluation, two patients had edge stenosis while one patient had in-stent stenosis. Two patients were treated with repeat balloon angioplasty, while angioplasty followed by repeat stent placement was done in one patient. A total of two patients required more than two interventions.

Dialysis access site failure was seen in three out of seven patients (42.86%). In one case, failure was due to thrombosis of AVF. In the other two cases, access site was abandoned due to poor functional status with creation of new autogenous AVF at a different site.

Immediate complication encountered was localized extravasation during difficult manipulation of the guidewire ( $n = 2$ ). Delayed complications were restenosis ( $n = 5$ ) and stent fracture ( $n = 1$ ).

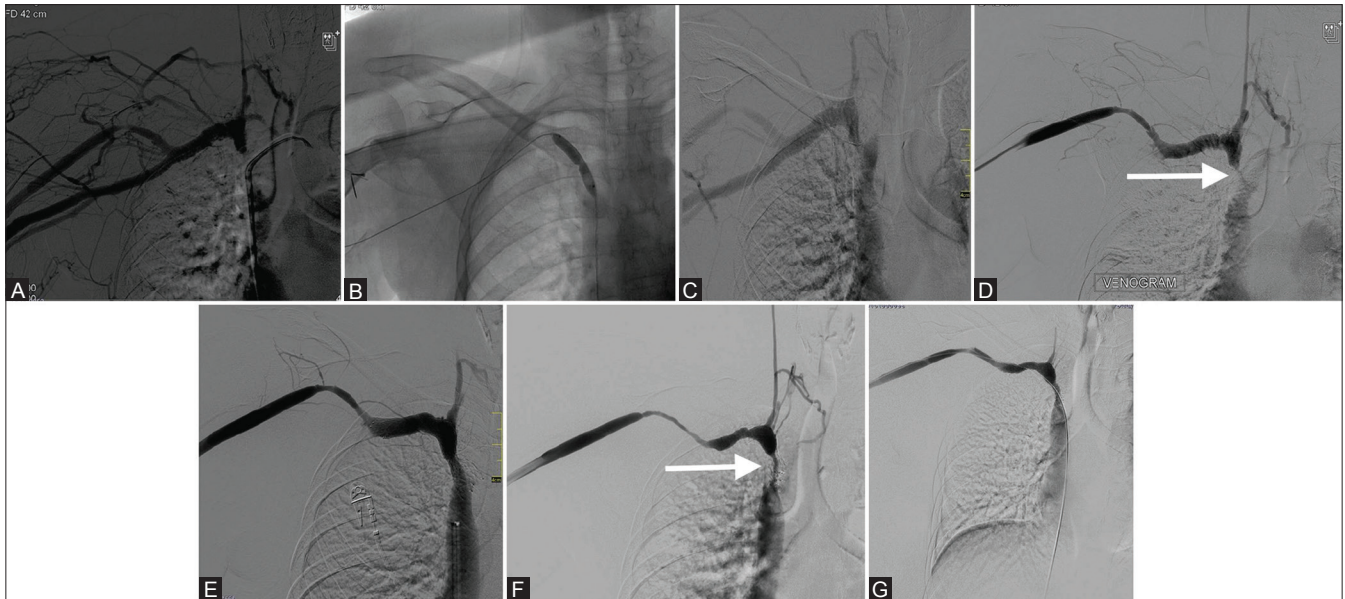
Proper follow-up of all the patients was not available. Patients presented to our referral center only if they had venous restenosis. Hence, due to lack of strict follow-up, the patency rates and long-term outcome could not be assessed.

## Discussion

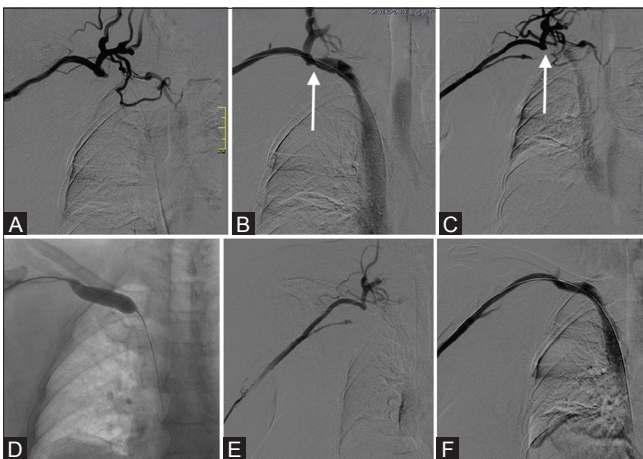
In recent years, there has been substantial increase in complications related to dialysis access due to increasing number of patients with end-stage renal disease and their increased survival.<sup>[14]</sup> CVD is a prevalent condition in patients undergoing hemodialysis. Two major factors implicated in development of CVD are venous trauma resulting from cannulation of central veins and hemodynamic stress secondary to high flow due to access site AVF.<sup>[3,15]</sup>

Central vein cannulation site determines central venous occlusion. Venous stenosis has been reported in up to 50% patients with catheterization of subclavian veins.<sup>[2,16]</sup> On





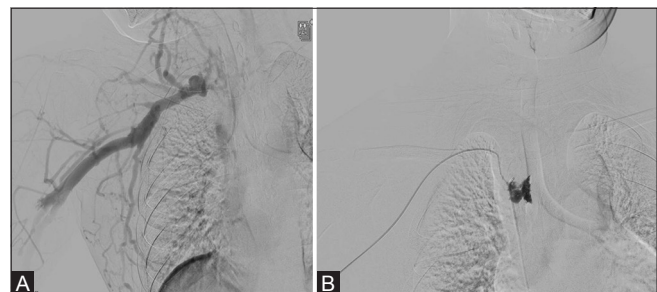**Figure 2(A-G):** A 53-year-old female patient with AVF in the right arm presented with right arm swelling. (A) Initial venogram showed complete occlusion of right brachiocephalic vein (B) PTA was done using 10 × 40 mm balloon (C) Post PTA venogram showed normal filling of right brachiocephalic vein. Patient presented with restenosis after 2 months (arrow in D) (E) Repeat venoplasty followed by stenting was done. However, there was recurrence with in-stent and edge stenosis (arrow in F) (G) Repeat venoplasty was done with approximately 60% opening of brachiocephalic vein



**Figure 3(A-F):** A 55-year-old female patient with AVF in the right arm. (A) Initial diagnostic venogram showed complete occlusion of right subclavian and brachiocephalic veins with multiple collaterals (B) Venoplasty and stenting was done resulting in opening of the occluded segment. However, there was inadequate coverage of stenotic segment at the proximal end (arrow in B). Patient presented with edge stenosis after 1 month (arrow in C), which was treated with venoplasty (D). There was recurrence (E) which was subsequently treated by restenting (F)

the other hand, right internal jugular vein cannulation has been associated with the lowest frequency of CVD.<sup>[17]</sup> The Dialysis Outcome and Quality Initiatives (DOQI) guidelines have advocated avoiding catheterization of subclavian vein in chronic renal failure patients for obtaining temporary access.<sup>[13]</sup>

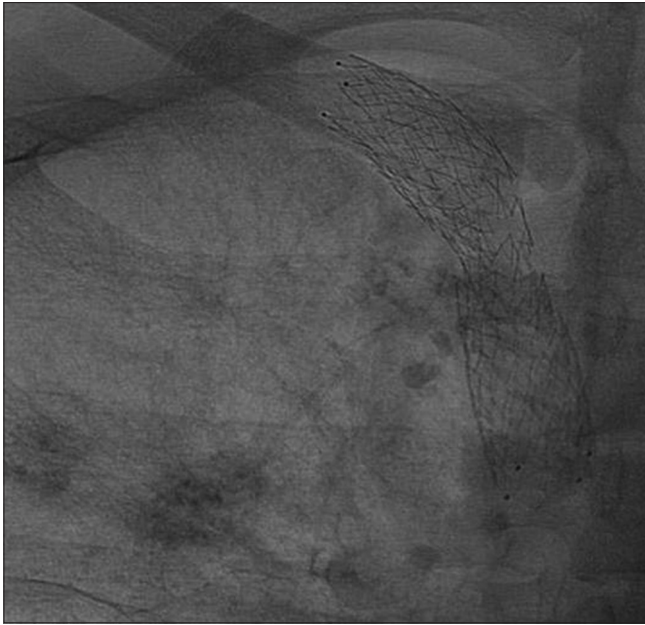
Development of central venous stenosis leads to increase in arteriovenous pressure at the dialysis access site. The



**Figure 4(A and B):** (A) Technical failure in a 43-year-old female patient presenting with complete occlusion of right brachiocephalic vein (B) There was a small tear while negotiating the guidewire through the occluded segment with contrast extravasation

resultant venous hypertension causes significant local morbidity by causing extremity, neck, and chest swelling. The initial management strategies were either surgical ligation of the fistula followed by abandonment of dialysis access site or open surgical repair of the central veins. Despite having high primary patencies at 1 year (80-86%), surgical methods carried high morbidity.<sup>[18,19]</sup> In the 1980s, evaluation of various endovascular methods was started for treating central venous stenosis.<sup>[20]</sup>

At present, endovascular treatment is the treatment of choice for CVD. The various endovascular methods used are balloon angioplasty, stenting, and, more recently, cutting balloon angioplasty. The optimal management strategy is still not clear. Primary stenting has been advocated by some for the treatment of CVD,<sup>[9,21]</sup> while others have advocated balloon angioplasty as the primary treatment, reserving stenting for treatment failure or restenosis.<sup>[10,12,22]</sup>



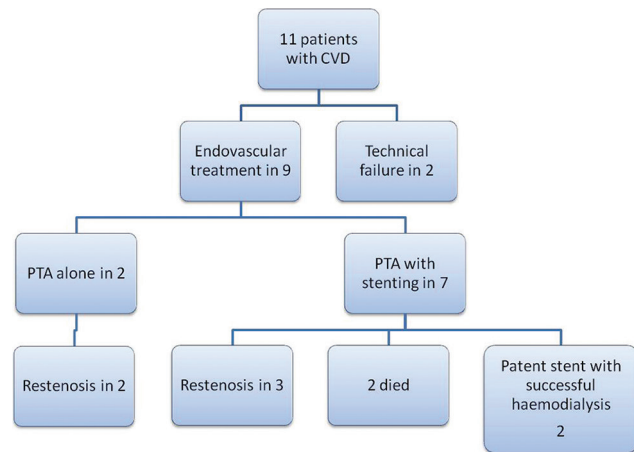
**Figure 5:** Stent fracture in a 33-year-old female patient who was previously treated with PTA and stenosis for occlusion of right brachiocephalic vein

In this retrospective study, we have reported our initial experience in endovascular treatment of CVD in patients having ipsilateral dialysis access.

Initial technical success rate in our case series was 81.8%. In both cases of technical failure, the guidewire could not be negotiated through completely occluded venous segment in the right brachiocephalic vein. For PTA, technical success rate ranging from 70 to 90% has been reported in the literature.<sup>[3,10-12,23-25]</sup> Very high technical success rates have been reported for bare metallic stenting in the literature, ranging from 90 to 100%.<sup>[8,9,22,26-28]</sup>

We performed only PTA in two patients [Figure 6]. No immediate complications were encountered. Both the patients presented with restenosis. Mean intervention-free period in these patients was 3.5 months (2-5 months). Elastic recoil is thought to be the cause for early recurrence in patients undergoing PTA.<sup>[29]</sup> In previous studies, primary patency rates for PTA ranged from 23 to 55% at 6 months and from 12 to 50% at 12 months. Cumulative patency rates range from 29 to 100% and from 13 to 100% at 6 and 12 months, respectively.<sup>[3,10,23-25]</sup>

In the remaining seven patients, PTA with stenting was performed [Figure 6]. We used self-expanding nitinol stent. Though nitinol stents are known to provide greater flexibility and resistance against kinking, in two previous studies, no significant difference was found between the patencies of wallstents and nitinol-based stents.<sup>[7,30]</sup> However, in another study, nitinol stents provided better patency rates



**Figure 6:** Flowchart showing follow-up of patients with primary and secondary endovascular procedures

than wallstents.<sup>[31]</sup> More recently, covered stents have also been utilized for treatment of central venous stenosis. High technical success rate with favorable outcomes have been reported in the limited literature available on the efficacy of covered stents.<sup>[32-35]</sup> Thus, covered stents appear to be an effective endovascular treatment option. However, their cost remains the limiting factor and cost/benefit analysis should be considered.

Three out of seven patients who underwent PTA with stenting presented with restenosis. Time for reintervention ranged from 1 to 8 months (mean 4.33 months). On diagnostic venography, two patients had recurrence at the margin of the stent (edge stenosis), while one patient had in-stent stenosis. Repeat PTA with ( $n = 1$ ) or without stenting ( $n = 2$ ) was done in all three patients. Hemodynamic stress and turbulence due to high blood flow in AVF has been implicated in causing intimal hyperplasia, thereby leading to stent restenosis.<sup>[36]</sup> With bare metallic stenting, primary patency rates of 63-100% at 3 months, 42-89% at 6 months, and 14-73% at 12 months have been reported. Cumulative patency rates range from 72 to 100%, from 55 to 100%, and from 31 to 97% at 3, 6, and 12 months, respectively.<sup>[8,9,11,22,26-28,37]</sup>

Delayed complication of stent fracture was also seen in one case.

Our study had certain limitations. Firstly, it was a non-randomized retrospective study. Secondly, the number of patients was very less with inadequate follow-up. Thus, patency rates could not be calculated. However, we have reported only our initial experience and further studies for longer time duration and with a larger sample size will be needed to assess long-term outcomes in the Indian population.



## Conclusion

To conclude, the endovascular treatment is an effective and safe method for treatment of CVD in patients undergoing hemodialysis. It has a high technical success rate without significant morbidity or mortality. However, multiple reinterventions are required for treatment of restenosis.

## Financial support and sponsorship

Nil.

## Conflicts of interest

There are no conflicts of interest.

## References

- Modabber M, Kundu S. Central venous stenosis in haemodialysis patients: An update. *Cardiovasc Intervent Radiol* 2013;36:898-903.
- Lumsden AB, MacDonald MJ, Isiklar H, Martin LG, Kikeri D, Harker LA, *et al.* Central venous stenosis in the hemodialysis patient: Incidence and efficacy of endovascular treatment. *Cardiovasc Surg* 1997;5:504-9.
- Glanz S, Gordon DH, Lipkowitz GS, Butt KM, Hong J, Sclafani SJ. Axillary and subclavian stenosis: Percutaneous angioplasty. *Radiology* 1988;168:371-3.
- Schwab SJ, Quarles LD, Middleton JP, Cohan RH, Saeed M, Dennis VW. Hemodialysis-associated subclavian vein stenosis. *Kidney Int* 1988;33:1156-9.
- Sprouse LR 2<sup>nd</sup>, Lesar CJ, Meier GH 3<sup>rd</sup>, Parent FN, Demasi RJ, Gayle RG, *et al.* Percutaneous treatment of symptomatic central venous stenosis [corrected]. *J Vasc Surg* 2004;39:578-82.
- Mickley V. Central vein obstruction in vascular access. *Eur J Vasc Endovasc Surg* 2006;32:439-44.
- Masková J, Komárková J, Kivánek J, Danes J, Slavíková M. Endovascular treatment of central vein stenoses and/or occlusions in hemodialysis patients. *Cardiovasc Intervent Radiol* 2003;26:27-30.
- Aytekin C, Boyvat F, Yagmurdu MC, Moray G, Haberal M. Endovascular stent placement in the treatment of upper extremity central venous obstruction in hemodialysis patients. *Eur J Radiol* 2004;49:81-5.
- Haage P, Vorwerk D, Piroth W, Schuermann K, Guenther RW. Treatment of hemodialysis related central venous stenosis or occlusion: Results of primary Wallstent placement and follow-up in 50 patients. *Radiology* 1999;212:175-80.
- Surowiec SM, Fegley AJ, Tanski WJ, Sivamurthy N, Illig KA, Lee DE, *et al.* Endovascular management of central venous stenoses in the hemodialysis patient: Results of percutaneous therapy. *Vasc Endovascular Surg* 2004;38:349-54.
- Bakken AM, Protack CD, Saad WE, Lee DE, Waldman DL, Davies MG. Long-term outcomes of primary angioplasty and primary stenting of central venous stenosis in hemodialysis patients. *J Vasc Surg* 2007;45:776-83.
- Quinn SF, Schuman ES, Demlow TA, Standage BA, Ragsdale JW, Green GS, *et al.* Percutaneous transluminal angioplasty versus endovascular stent placement in the treatment of venous stenoses in patients undergoing hemodialysis: Intermediate results. *J Vasc Interv Radiol* 1995;6:851-5.
- III. NKF-K/DOQI Clinical Practice Guidelines for Vascular Access: Update 2000. *Am J Kidney Dis* 2001;37(Suppl 1):S137-81.
- Nael K, Kee ST, Solomon H, Katz SG. Endovascular management of central thoracic veno-occlusive diseases in hemodialysis patients: A single institutional experience in 69 consecutive patients. *J Vasc Interv Radiol* 2009;20:46-51.
- Morosetti M, Meloni C, Gandini R, Galderisi C, Pampana E, Nicoletti M, *et al.* Late symptomatic venous stenosis in three hemodialysis patients without previous central venous catheters. *Artif Organs* 2000;24:929-31.
- Hernández D, Díaz F, Rufino M, Lorenzo V, Pérez T, Rodríguez A, *et al.* Subclavian vascular access stenosis in dialysis patients: Natural history and risk factors. *J Am Soc Nephrol* 1998;9:1507-10.
- Schillinger F, Schillinger D, Montagnac R, Milcent T. Central venous stenosis in hemodialysis: Comparative angiographic study of subclavian and internal jugular access. *Nephrologie* 1994;15:129-31.
- Wisselink W, Money SR, Becker MO, Rice KL, Ramee SR, White CJ, *et al.* Comparison of operative reconstruction and percutaneous balloon dilatation for central venous obstruction. *Am J Surg* 1993;166:200-5.
- Money S, Bhatia D, Daharamsy S, Mulingtapang R, Shaw D, Ramee S. Comparison of surgical bypass, percutaneous balloon dilatation (PTA), and PTA with stent placement in the treatment of central venous occlusion in the dialysis patient: One year follow-up. *Int Angiol* 1995;14:176.
- Glanz S, Gordon D, Butt KM, Hong J, Adamson R, Sclafani SJ. Dialysis access fistulas: Treatment of stenoses by transluminal angioplasty. *Radiology* 1984;152:637-42.
- Oderich GS, Treiman GS, Schneider P, Bhirangi K. Stent placement for treatment of central and peripheral venous obstruction: Along-term multi-institutional experience. *J Vasc Surg* 2000;32:760-9.
- Gray RJ, Horton KM, Dolmatch BL, Rundback JH, Anaise D, Aquino AO, *et al.* Use of Wallstents for hemodialysis access-related venous stenoses and occlusions untreatable with balloon angioplasty. *Radiology* 1995;195:479-84.
- Beathard GA. Percutaneous transvenous angioplasty in the treatment of vascular access stenosis. *Kidney Int* 1992;42:1390-7.
- Kovalik EC, Newman GE, Suhocki P, Knelson M, Schwab SJ. Correction of central venous stenoses: Use of angioplasty and vascular Wallstents. *Kidney Int* 1994;45:1177-81.
- Dammers R, de Haan MW, Planken NR, van der Sande FM, Tordoir JH. Central vein obstruction in hemodialysis patients: Results of radiological and surgical intervention. *Eur J Vasc Endovasc Surg* 2003;26:317-21.
- Vogel PM, Parise C. SMART stent for salvage of hemodialysis access grafts. *J Vasc Interv Radiol* 2004;15:1051-60.
- Vesely TM, Hovsepian DM, Pilgram TK, Coyne DW, Shenoy S. Upper extremity central venous obstruction in hemodialysis patients: Treatment with Wallstents. *Radiology* 1997;204:343-8.
- Vorwerk D, Guenther RW, Mann H, Bohndorf K, Keulers P, Alzen G, *et al.* Venous stenosis and occlusion in hemodialysis shunts: Follow-up results of stent placement in 65 patients. *Radiology* 1995;195:140-6.
- Kim YC, Won JY, Choi SY, Ko HK, Lee KH, Lee do Y, *et al.* Percutaneous treatment of central venous stenosis in haemodialysis patients: Long-term outcomes. *Cardiovasc Intervent Radiol* 2009;32:271-8.
- Maya ID, Saddekni S, Allon M. Treatment of refractory central vein stenosis in hemodialysis patients with stents. *Semin Dial* 2007;20:78-82.
- Rajan DK, Saluja JS. Use of nitinol stents following recanalization of central venous occlusions in hemodialysis patients. *Cardiovasc Intervent Radiol* 2007;30:662-7.
- Quinn SF, Kim J, Sheley RC. Transluminally placed endovascular grafts for venous lesions in patients on hemodialysis. *Cardiovasc Intervent Radiol* 2003;26:365-9.
- Kundu S, Modabber M, You JM, Tam P, Nagai G, Ting R. Use of PTFE stent grafts for hemodialysis-related central venous

- occlusions: Intermediate-term results. *Cardiovasc Intervent Radiol* 2011;34:949-57.
34. Anaya-Ayala JE, Smolock CJ, Colvard BD, Naoum JJ, Bismuth J, Lumsden AB, *et al.* Efficacy of covered stent placement for central venous occlusive disease in hemodialysis patients. *J Vasc Surg* 2011;54:754-9.
35. Jones RG, Willis AP, Jones C, McCafferty IJ, Riley PL. Long-term results of stent-graft placement to treat central venous stenosis and occlusion in hemodialysis patients with arteriovenous fistulas. *J Vasc Interv Radiol* 2011;22:1240-45.
36. Fillingier MF, Reinitz ER, Schwartz RA, Resetarits DE, Paskanik AM, Bruch D, *et al.* Graft geometry and venous intimal-medial hyperplasia in arteriovenous loop grafts. *J Vasc Surg* 1990;11:556-66.
37. Chen CY, Liang HL, Pan HB, Chung HM, Chen WL, Fang HC, *et al.* Metallic stenting for treatment of central venous obstruction in hemodialysis patients. *J Chin Med Assoc* 2003;66:166-72.