

Efficacy of ¹⁸F-FDG PET/CT in investigation of elevated CEA without known primary malignancy

Simon Sin-man Wong, Wong L Yu, Ki Wang, Anil T Ahuja

Department of Imaging and Interventional Radiology, Prince of Wales Hospital, Chinese University of Hong Kong, Hong Kong

Correspondence: Dr. Simon Sin-man Wong, Department of Imaging and Interventional Radiology, Prince of Wales Hospital, Chinese University of Hong Kong, Hong Kong. E-mail: wsm652@ha.org.hk

Abstract

Aim: To evaluate the efficacy of ¹⁸fluorodeoxyglucose positron emission tomography/computer tomography (¹⁸F-FDG PET/CT) in investigating patients with elevated carcinoembryonic antigen (CEA) and without known primary malignancy, and the impact of PET/CT findings on patient management. **Setting and Design:** PET/CT scans done in a tertiary hospital between December 2007 and February 2012 for elevated CEA in patients without known primary malignancy were retrospectively reviewed. **Materials and Methods:** The PET/CT findings, patients' clinical information, level of CEA, histological diagnosis, and subsequent management were retrieved by the electronic patient record for analysis. **Statistical Analysis:** Data were analyzed using SPSS version 19. **Results:** One hundred and one PET/CT scans were performed for patients with elevated CEA. Fifty-eight of these were performed for patients with known primary malignancy and were excluded; 43 PET/CT scans were performed for patients without known primary malignancy and were included. Thirty-three (77%) had a positive PET/CT. Among the 32 patients with malignancy, 15 (47%) suffered from lung cancer and 8 (25%) suffered from colorectal cancer. The sensitivity (97%), specificity (82%), positive predictive value (94%), negative predictive value (90%), and accuracy (93%) were calculated. Thirty (91%) patients had resultant change in management. The mean CEA level for patients with malignancy (46.1 ng/ml) was significantly higher than those without malignancy (3.82 ng/ml) ($P < 0.05$). In predicting the presence of malignancy, a CEA cutoff at 7.55 ng/ml will achieve a sensitivity of 91% and a specificity of 73%. **Conclusion:** PET/CT, in our study population, appears to be sensitive, specific, and accurate in investigating patients with elevated CEA and without known primary malignancy. In addition to diagnosis of underlying primary malignancy, PET/CT also reveals occult metastases which would affect patient treatment options. Its role in investigating patients with elevated CEA and without known primary, compared with other investigation modalities, remains to be studied.

Key words: Biological; carcinoembryonic antigen; neoplasms; positron emission tomography; tomography; tumor markers; unknown primary; X-ray computed

Introduction

Elevated carcinoembryonic antigen (CEA) is an increasingly common clinical problem nowadays due to increased availability of the test as part of health check-up, as well

as in patients presenting with metastases of unknown primary. Many modalities are currently used as part of the investigations of elevated CEA, such as chest radiograph, upper and lower endoscopy, and computed tomography. ¹⁸Fluorodeoxyglucose positron emission tomography/

Access this article online

Quick Response Code:



Website:
www.ijri.org

DOI:
10.4103/0971-3026.190412

This is an open access article distributed under the terms of the Creative Commons Attribution-NonCommercial-ShareAlike 3.0 License, which allows others to remix, tweak, and build upon the work non-commercially, as long as the author is credited and the new creations are licensed under the identical terms.

For reprints contact: reprints@medknow.com

Cite this article as: Wong SS, Yu WL, Wang K, Ahuja AT. Efficacy of ¹⁸F-FDG PET/CT in investigation of elevated CEA without known primary malignancy. Indian J Radiol Imaging 2016;26:405-10.

computer tomography (18F-FDG PET/CT) is evolving to be a potential modality for diagnosis and staging in patients with elevated CEA. PET/CT has been shown to be useful in detecting recurrent colorectal carcinoma in patients with elevated CEA but not showing suspicious lesion on conventional imaging. The reported sensitivity and specificity are in the range of 87–100% and 66–100%, respectively.^[1] PET/CT is also useful in the identification of occult head and neck primary in patients with cervical metastases, with reported sensitivity and specificity ranging from 91 to 100% and from 67 to 87%, respectively.^[2,3] The value of PET/CT lies not only in its ability to diagnose primary malignancy but is also reflected by its ability to reveal distant metastases that would upstage the disease, and has an impact on patients' management. Several studies have shown that PET/CT is able to reveal clinically occult distant metastases which will affect tumor resectability and subsequent management.^[3-5] However, the performance of PET/CT in investigating elevated CEA in patients without known primary malignancy is not well established. Our study aims to evaluate the efficacy of PET/CT in investigating patients with elevated CEA and without known primary malignancy, and the impact of PET/CT findings on patient management.

Materials and Methods

In the authors' institution, informed consent and institutional ethics review were waived for retrospective study. PET/CT scans done in a tertiary hospital between December 2007 and February 2012 for elevated CEA (>2.5 ng/ml) were reviewed. Patients without known primary malignancy were included, whereas those with known primary malignancy were excluded. In the authors' institution, patients presenting with elevated CEA are first assessed by the clinician, who obtains a detailed medical history and performs a comprehensive physical examination to identify the most likely source of elevated CEA. Depending on the organ system concerned, this is followed by specific investigations, such as chest radiograph, computed tomography, bronchoscopy, colonoscopy, etc., PET/CT is also an option, but it is not a publically funded investigation and can only be performed in patients who can afford the cost. The choice of investigation relies on the clinical judgment of the referring clinicians. Therefore, at the time of PET/CT, the investigations received by the patients were variable. Patients were regarded to have no known primary malignancy if there was no clinical history, physical examination findings, and available imaging and pathological findings to suggest a likely primary malignancy. On the contrary, patients were regarded to have known malignancy if there was such evidence on clinical history (e.g., known lung cancer), physical examination findings (e.g., a rectal mass), and available imaging/endoscopic (e.g., lung mass on chest radiograph, colonic mass on colonoscopy) or pathological (e.g. biopsy-proven

malignancy) examinations. PET/CT was performed using Philips Gemini GXL scanner (Philips Medical Systems International BV, Best, The Netherlands). Patients were fasted for 6 hours before scanning. Blood glucose level was monitored and insulin was given if the blood glucose level exceeded 11 mmol/l. Then 10 mCi 18-FDG was injected intravenously and the patients were asked to rest for 1 hour before scanning. PET images (4 mm slice thickness) were first acquired from vertex to below the knee, followed by low-dose plain CT (5 mm slice thickness; Philips 16-slice MDCT; 30 mA, 140 kV) for attenuation correction and anatomical correlation (to register the anatomical location of tracer activity). PET acquisition was usually covered by 12–15 beds of scanning. Each bed covered a length of 180 mm and was counted in 90-s segments. The total length of coverage was 1104–1356 mm. Depending on the referral request, supplementary diagnostic CT with or without intravenous contrast would be performed. The images were processed and viewed using Philips Extended Brilliance (TM) Workspace, as exemplified in Figure 1A. The PET/CT findings, including the size, site, number, and maximal standardized uptake value (SUVmax) of the lesions, were retrieved. Patients' clinical information, including age, sex, diabetic status, smoking status, level of CEA before PET/CT, other investigations performed (such as chest radiograph, bronchoscopy, colonoscopy, etc.), and the results, histological diagnosis, and subsequent management were retrieved by the electronic patient record for analysis. A positive PET/CT is defined as a PET/CT which detects the presence of primary malignancy based on morphological lesions or abnormal hypermetabolic (e.g., SUVmax > 2.5) focus. A negative PET/CT is defined as a PET/CT which is normal, shows incidental benign lesions, or is inconclusive for the presence of primary malignancy. Change in management is defined as identification of occult distant metastases which would preclude surgical resection. The gold standard to confirm the presence of primary malignancy is histological confirmation. If the suspected lesion was accessible by endoscopy, a negative endoscopy (i.e., no lesion detected) would also be considered as the gold standard to confirm absence of malignancy. If no biopsy or endoscopy is performed, a follow-up for at least 6 months would be used. Patients who remain well without clinical or radiological evidence of primary malignancy are considered negative for primary malignancy and vice versa.

All statistical analyses were performed using the Statistical Package for the Social Sciences version 19 (Chicago, IL, USA). Means of metric variables were compared using two-sample *t*-test. Levene's test was used to test the equality of variance of the variables. Correlation was tested using Spearman's correlation test. Difference in proportions of two independent samples was tested using Fisher's exact test. *P* value below 0.05 was considered to be statistically significant.

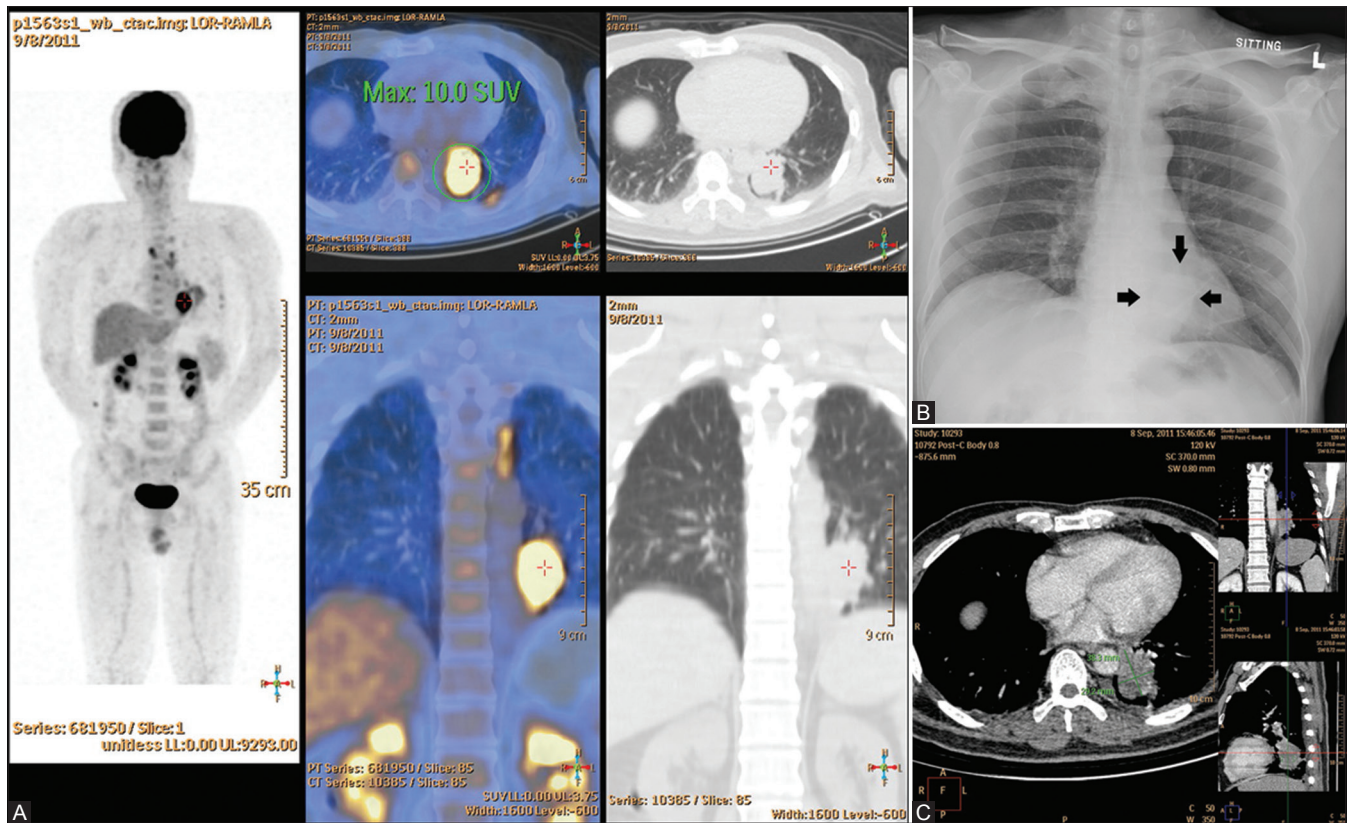


Figure 1 (A–C): (A) Axial and coronal images of fusion PET/CT showing a hypermetabolic (SUVmax: 10.0) left lower lobe mass suspicious of lung cancer with mediastinal nodal metastases. (B) Frontal chest radiograph of the same patient, showing a retrocardiac mass (arrows). (C) Axial, coronal, and sagittal CT images of the same patient confirming an irregular soft tissue lung mass at the retrocardiac region

Results

Between December 2007 and February 2012, there were 101 PET/CT scans performed for patients with elevated CEA. Fifty-eight of these were performed for patients with known primary malignancy and were excluded. Forty-three PET/CT scans were performed for patients without known primary and were included in the analysis [Figure 2]. Their basic demographics are listed in Table 1. The mean time interval between CEA measurement and PET/CT was 13.3 (2–115) days. Some patients had undergone multiple investigations before PET/CT, resulting in a longer time interval. The distribution of CEA level is depicted in Table 2. Because of the time lag between referral and examination, 1 patient had his CEA level normalized (0.6 ng/ml) 3 days before PET/CT.

Among the 32 patients with malignancy, 15 (47%) suffered from lung cancer and 8 (25%) suffered from colorectal cancer [Figure 3A–D]. Others included lymphoma (1 patient); carcinoma of gallbladder (1 patient), nasopharynx (1 patient), pancreas (1 patient); myeloma (1 patient); and unknown primary (2 patients).

Among the 43 patients, 33 (77%) had a positive PET/CT whereas 10 (23%) had a negative scan. Table 3 shows the

Table 1: Demographics of 43 patients included

Age (years)	66 (range 13-91)	
Sex	Male 22 (51%)	Female 21 (49%)
Active smoker	Non-smoker 36 (84%)	Active smoker 7 (16%)
Diabetes	Non-diabetic 30 (70%)	Diabetic 13 (30%)
Mean CEA (ng/ml)	158 (range 0.6* – 2262), SD 441	
Mean duration of follow up (months)	26.4	

SD: (Standard deviation) Percentage in parenthesis *Due to time lag between referral and examination, one patient had his CEA level normalized (0.6ng/ml) 3 days before PET/CT

cross-tabulation of the results of PET/CT against the final diagnosis. The sensitivity (97%), specificity (82%), positive predictive value (94%), negative predictive value (90%), and accuracy (93%) are calculated accordingly. Among the 33 patients with positive scan, 30 (91%) patients had resultant change in management due to detection of occult distant metastases precluding surgical resection. The distribution of common sites of metastatic disease is presented in Table 4. There was no change in management in 3 patients (9%). Two patients suffered from colorectal cancer without distant metastases. One patient was found to have hypermetabolic lesion in the urinary bladder, which was subsequently confirmed to be cystitis by cystoscopy. No distant hypermetabolic lesion was identified.

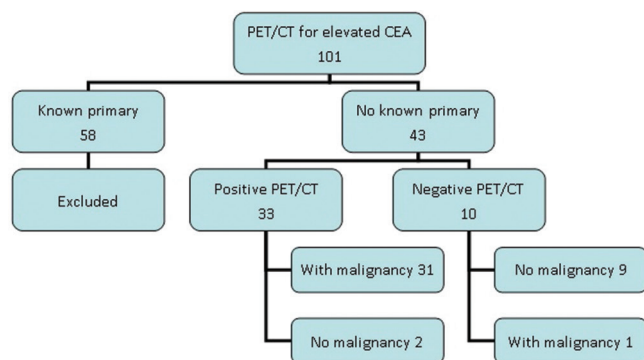


Figure 2: Analysis of 101 patients with elevated CEA

Table 2: Distribution of CEA level of 43 patients included for analysis

CEA level (ng/ml)	Number of patients
<10	15
10-50	15
50-100	5
100-500	4
>500	4

*Range (0.6-2262)

*Due to time lag between referral and examination, one patient had his CEA level normalized (0.6ng/ml) 3 days before PET/CT

Table 3: PET/CT result vs. Final Diagnosis

PET/CT result	Final Diagnosis		Total
	No malignancy	With malignancy	
Negative	9	1	10
Positive	2	31	33
Total	11	32	43

There was 1 false-negative PET/CT in which the scan showed hypermetabolic hilar nodes and increased FDG activity in the axial skeleton [Figure 4]. The patient had known history of chronic anemia. The marrow activity appeared mildly hypermetabolic (SUVmax less than 2.5) and homogenous. Such finding was, therefore, interpreted as marrow hyperplasia. Skeletal survey was also negative. However, subsequent blood test showed hyperparaproteinemia and bone marrow biopsy revealed plasma cell myeloma. There were two false-positive PET/CT scans. The first showed mildly hypermetabolic (SUVmax: 2.0) wall thickening (wall thickness: 1.6 cm) of the urinary bladder, suspicious of bladder cancer. A flexible cystoscopy showed cystitis only and bladder biopsy was also negative for malignancy. The second one found increased FDG activity at the anus (SUVmax: 3.9) with hypermetabolic hilar and mediastinal nodes (SUVmax: 3.1–3.3) and small (1 cm) bilateral lung nodules (SUVmax: 3.8). Anal cancer with lung metastases was suspected. However, colonoscopy and MRI pelvis performed subsequently

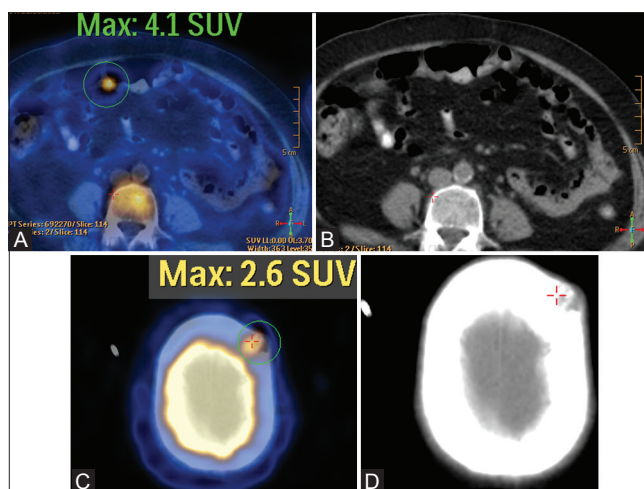


Figure 3 (A–D): A 62-year-old lady presenting with elevated CEA (5.2 ng/ml). A hypermetabolic focus was found at the mid-transverse colon on fusion PET/CT (A), which persisted in delay image (not shown). No obvious lesion was found on plain CT (B). Another hypermetabolic lesion was found at the left frontal skull on fusion PET/CT (C), corresponding to a destructive bone lesion on CT (D). Features were consistent with a small colonic tumor with skull metastasis

showed no suspicious anal lesion and the patient remained well on follow-up.

The CEA levels between patients with and without malignancy, as determined by biopsy or follow-up, were compared using two-sample *t*-test after natural logarithmic transformation [Table 5]. The mean CEA level in patients with malignancy (46.1 ng/ml) was significantly higher than in those without malignancy (3.82 ng/ml) ($P = 0.027$). No significant difference in CEA level was found between lung cancer and colorectal cancer groups ($P = 0.21$). Figure 5 shows the receiver operating curve (ROC) of CEA level as a means to predict final diagnosis (with or without malignancy). The shape of the curve and area under curve (0.936) demonstrate that CEA level is a test with good sensitivity and specificity. A CEA cutoff at 7.55 ng/ml will achieve a sensitivity of 91% and a specificity of 73%, whereas if it is increased to 8.95 ng/ml, a sensitivity of 88% and specificity of 91% will be achieved.

No significant correlation was demonstrated between the level of CEA and SUVmax, number of lesions, and number of involved organ systems identified on PET/CT. There was significant correlation between the number of lesions and the number of involved organ systems, with correlation coefficient of 0.76 ($P = 0.01$). No significant difference in SUVmax was found between lung cancer and colorectal cancer groups ($P = 0.82$).

Among the 32 patients with malignancy, 15 (47%) suffered from lung cancer. All patients had positive PET/CT (100% sensitivity). The mean CEA was 137 ng/ml. Among these 15 patients, 13 (87%) had abnormal chest radiograph when

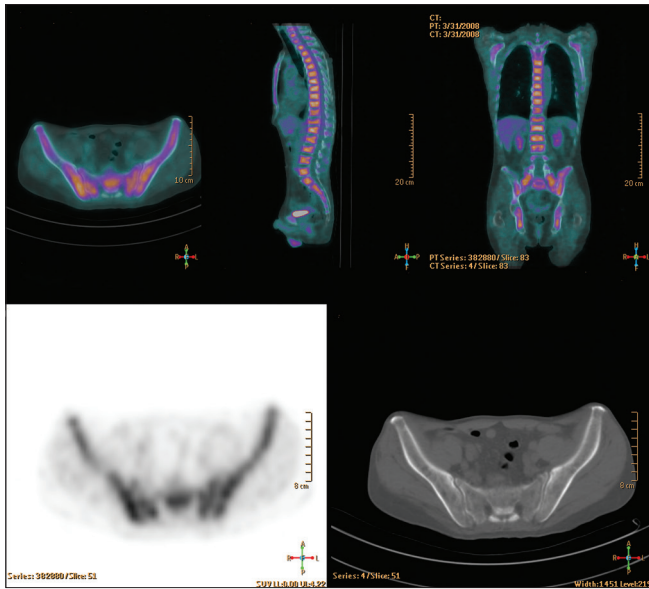


Figure 4: A 73-year-old man presenting with elevated CEA of 46 ng/ml. Fusion PET/CT images show diffuse homogenous hypermetabolic activity along the entire axial skeleton. No definite destructive lesion was identified on CT. Findings were interpreted as marrow hyperplasia due to chronic anemia. However, subsequent blood test revealed hyperparaproteinemia and bone marrow biopsy revealed plasma cell myeloma

reviewed by radiologist whereas 9 (60%) were considered abnormal by referring clinicians; however, this difference was not statistically significant (Fisher exact test: $P = 0.14$). The primary lesions in the 4 chest radiographs considered normal by referring clinicians were projected in the retrocardiac [Figure 1B and C], paravertebral, or intercostal regions.

Discussion

In our study, PET/CT showed reasonably good performance in detecting primary malignancy in patients with elevated CEA. The sensitivity (97%) and specificity (82%) were comparable with those reported for patients with elevated CEA and known primary malignancy, such as colorectal carcinoma.^[1,6] Ninety-one percent of positive PET/CT identified occult distant metastases which preclude surgical resection. Although there is a study suggesting correlation between SUV of the tumor and CEA level in colorectal cancer,^[7] such correlation was not found in our study. This can be due to the heterogeneity of the tumor type. The number of lesions correlates with the number of involved organ systems, which is expected as many patients have widespread metastatic disease.

There were two false-positive cases due to increased uptake at the urinary bladder and anal canal. Since FDG is normally excreted into the urinary and gastrointestinal tracts, physiological activity in the urinary bladder and bowels can sometimes mimic pathology. The reporting radiologists

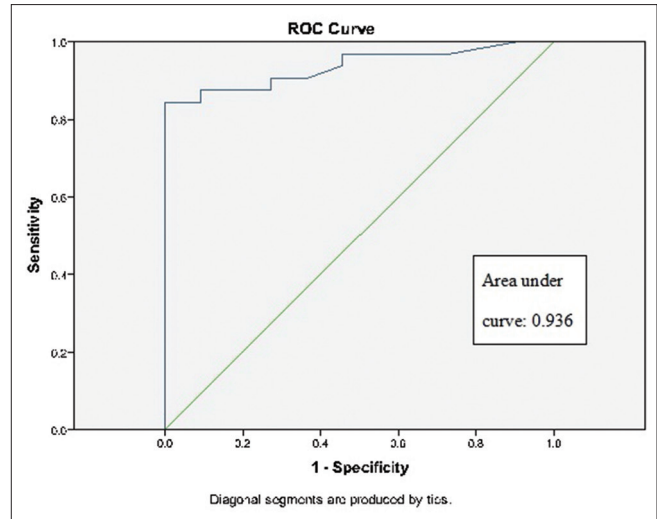


Figure 5: ROC for CEA level in predicting the presence of primary malignancy

Table 4: Common site of metastases in 30 patients with metastatic disease

Site of metastases	Number of patients*	Mean SUVmax
Regional node	24 (80%)	5.53
Bone	12 (40%)	5.08
Pulmonary	8 (27%)	3.53
Brain	7 (23%)	8.87
Liver	7 (23%)	6.89

*Percentage in parenthesis

Table 5: CEA level between patients with and without malignancy

	With malignancy	No malignancy	t test
Number	32	11	
Mean CEA (ng/ml)	46.1	3.82	$P < 0.05$

should be aware of these pitfalls and request delayed scan if necessary to distinguish physiological from pathological uptake. In difficult cases, endoscopy (e.g., colonoscopy or cystoscopy) should always be suggested to confirm the findings.

We found that CEA was significantly higher in patients with malignancy and the CEA level appeared to be reasonably sensitive and specific in categorizing patients with or without malignancy. CEA level is commonly elevated in patients with malignancy, especially those originating from endodermally derived organs, breast, and mucinous ovarian primaries.^[8] Normal CEA level is associated with better prognosis in patients with unknown primary.^[9] We found that a CEA cutoff at 7.55 ng/ml will achieve a sensitivity of 91% and a specificity of 73%, whereas if it is increased to 8.95 ng/ml, a sensitivity of 88% and specificity of 91% will be achieved. These levels are approximately close to the cutoff level currently used for CEA measurement. On the

other hand, significant proportion (23%) of patients had no evidence of malignancy despite CEA elevation. As CEA is known to increase in nonmalignant conditions, such as hepatic dysfunction, biliary obstruction,^[10] colonic polyp, or even in smokers,^[11,12] its role in screening of malignancy remains questionable. The risk of PET/CT, which carries considerable amount of radiation, to investigate elevated CEA level must be balanced with the diagnostic yield in this group of patients with relatively low pre-test probability.

In the subgroup analysis of patients with lung cancer, PET/CT was 100% sensitive; 87% of these patients had abnormal chest radiograph and 60% were identified by referring clinicians. This is not surprising given the subtleness of early lung cancer on chest radiograph.^[13] Among the chest radiographs considered normal by referring clinicians, the primary tumors were usually projected in the review areas such as retrocardiac [Figure 1B and C], paravertebral, or intercostal regions. It is, therefore, helpful for clinicians to be aware of these review areas and to involve radiologist's input, if necessary, when interpreting the chest radiographs of patients with raised CEA.

There are several limitations of our study. The sample size was small. The study population was biased toward a selected group of patients who could afford PET/CT as it is not a publically funded investigation. This group of patients was also heterogeneous in terms of the investigations received before PET/CT due to a lack of standardized protocol of investigating elevated CEA in authors' institution. Therefore, our results may not be generalizable to all patients with elevated CEA. In addition, direct comparison with other investigations (such as endoscopy and CT) could not be made and remains a question to be answered by future study. The retrospective nature of this study makes data acquisition not standardized. Not all patients with positive PET/CT had histological confirmation. Some patients with presumed disseminated malignancy might not receive further investigations/treatment. Future prospective study with larger sample size and standardized protocol to compare PET/CT with other investigation modalities will be very helpful to overcome these limitations.

In conclusion, in our study population, PET/CT appears sensitive, specific, and accurate in investigating patients with elevated CEA and without known primary malignancy. It may also reveal occult metastases which would affect patient treatment options. Its role in

investigating patients with elevated CEA and without known primary, compared with other investigation modalities, remains to be studied.

Financial support and sponsorship

Nil.

Conflicts of interest

There are no conflicts of interest.

References

1. van Kouwen MC, Oyen WJ, Nagengast FM, Jansen JB, Drenth JP. FDG-PET scanning in the diagnosis of gastrointestinal cancers. *Scand J Gastroenterol Suppl* 2004;85-92.
2. Regelink G, Brouwer J, de Bree R, Pruijm J, van der Laan BF, Vaalburg W, *et al.* Detection of unknown primary tumours and distant metastases in patients with cervical metastases: Value of FDG-PET versus conventional modalities. *Eur J Nucl Med Mol Imaging* 2002;29:1024-30.
3. Wong WL, Sonoda LI, Gharpurhy A, Gollub F, Wellsted D, Goodchild K, *et al.* 18F-fluorodeoxyglucose positron emission tomography/computed tomography in the assessment of occult primary head and neck cancers--An audit and review of published studies. *Clin Oncol (R Coll Radiol)* 2012;24:190-5.
4. Fülöp M, Kásler M, Remenár E, Lengyel Z, Borbély K. [The role of PET-CT in detecting unknown primary tumour in patients with cervical lymph node metastases]. *Magy Onkol* 2012;56:84-92.
5. Wartski M, Le Stanc E, Gontier E, Vilain D, Banal A, Tainturier C, *et al.* In search of an unknown primary tumour presenting with cervical metastases: Performance of hybrid FDG-PET-CT. *Nucl Med Commun* 2007;28:365-71.
6. Lu YY, Chen JH, Chien CR, Chen WT, Tsai SC, Lin WY, *et al.* Use of FDG-PET or PET/CT to detect recurrent colorectal cancer in patients with elevated CEA: A systematic review and meta-analysis. *Int J Colorectal Dis* 2013;28:1039-47.
7. Choi MY, Lee KM, Chung JK, Lee DS, Jeong JM, Park JG, *et al.* Correlation between serum CEA level and metabolic volume as determined by FDG PET in postoperative patients with recurrent colorectal cancer. *Ann Nucl Med* 2005;19:123-9.
8. Koch M, McPherson TA. Carcinoembryonic antigen levels as an indicator of the primary site in metastatic disease of unknown origin. *Cancer* 1981;48:1242-4.
9. Fernandez-Cotarelo MJ, Guerra-Vales JM, Colina F, de la Cruz J. Prognostic factors in cancer of unknown primary site. *Tumori* 2010;96:111-6.
10. Ruibal Morell A. CEA serum levels in non-neoplastic disease. *Int J Biol Markers* 1992;7:160-6.
11. Loewenstein MS, Zamcheck N. Carcinoembryonic antigen (CEA) levels in benign gastrointestinal disease states. *Cancer* 1978;42(3 Suppl):1412-8.
12. Lee JY, Lee DC, Lee JW. Serum carcinoembryonic antigen is associated with non-alcoholic fatty liver disease in healthy Korean non-smokers. *Clin Chem Lab Med* 2013;51:1499-504.
13. White CS, Flukinger T, Judy J, Chen JJ. Use of a computer-aided detection system to detect missed lung cancer at chest radiography. *Radiology* 2009;252:273-81.