

Antenatal Sonological Omphaloischiophagus Twin

BR NAGARAJ, AB MANJUNATH

Ind J Radiol Imag 2005 15:2:263-265

Key words : - Conjoined Twins, Omphaloischiophagus

INTRODUCTION:

The prevalence of conjoined twins is approximately 1 per 50,000 to 1 per 1, 00,000 of births [1,2]; the incidence of conjoined twins is sporadic with no known associations.

Normal Twin pregnancy occurs as a result of division of the embryonic disc after 8 days post conception resulting in formation of two embryos within a single amnion and a chorion, single yolk sac may be present. Incomplete division of the embryonic disc after 13 days and within 2 weeks post conception results in abnormal twins (conjoined) and resultant fusion with shared body parts [1,2]. Nomenclature of the twins depends on the site of fusion.

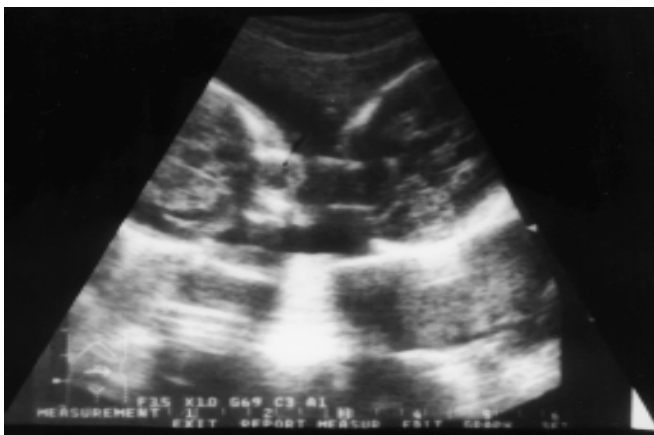

Fig 1

CASE REPORT:

A primi gravida aged about 18 yrs with 32 weeks amenorrhoea, no history of consanguinity presented for routine antenatal US examination. It was noticed that both fetuses were facing each other, two skulls appreciated separately (fig no 1) with two separate spines, no CNS anomalies were detected. One fetus was found to be at a slightly higher level than the other. Both fetuses were in breech presentation with over crowding of lower limbs and

Diagnosis Of An

inter locking with restricted movements. Both upper limbs were appreciated separately, abdominal circumference could not be measured separately, and standard sections of AC could not be taken in both fetuses.

Liver was shared by both fetuses.

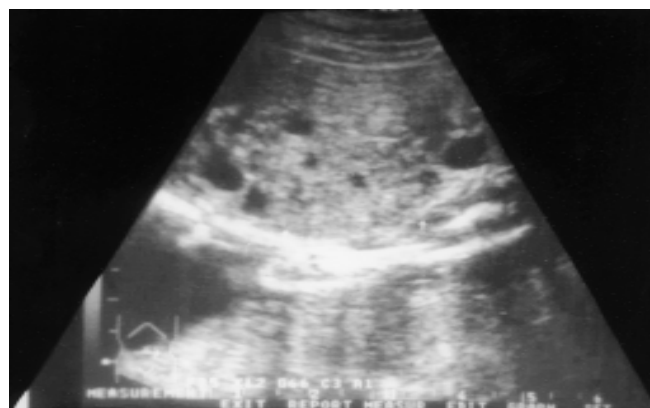

Fig 2

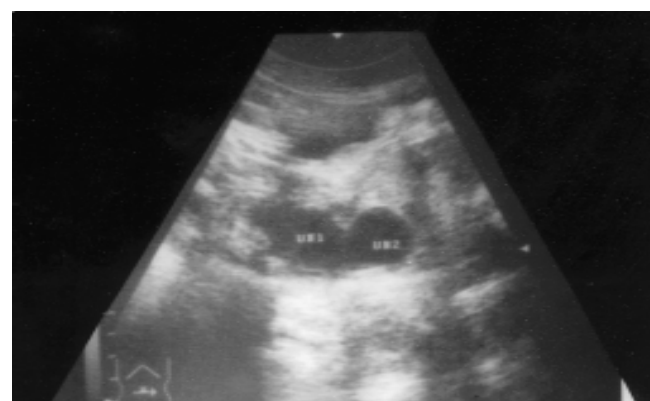

Fig 3

Typical stomach bubbles were not appreciated separately (fig no 2), instead a fluid filled cystic structure was seen in both fetuses on the same side (one on left, other on right side), we could not confirm it by special investigations

From the Dept Of Radio Diagnosis, Vani Vilas Women And Children Hospital, Bangalore Medical College, Bangalore.

Request for Reprints: Dr BR Nagaraj, No. 720, 39 Th Cross, 17 Th Main, 4 Th T Block, Jayanagar, Bangalore - 560 041

Received 5 August 2003; Accepted 10 October 2004

since the condition of the fetuses were not permissible.

Small bowel loops could not be appreciated, kidneys were appreciated separately in both fetuses, urinary bladder was also appreciated separately (fig no 3), and genital organs could not be appreciated due to breech presentation. A single placenta was seen in the fundus with a single umbilical cord.

Lower limb and body movements were sluggish, hand movements and upper body and skull movements were normal. Head circumference, Bi-parietal diameter of both the fetuses were measured separately, femur lengths could be measured inspite inter locking and corresponded to 32 weeks of gestation, AC could not be obtained separately, however typical sections of the lumbosacral spines were obtained which showed close approximation of the LS spines (fig no 4)

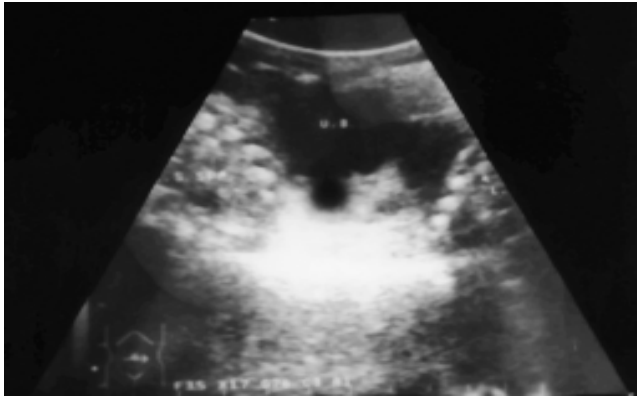

Fig 4

A provisional diagnosis of Omphaloischiophagus was made, clinicians were requested to extract this rare anomalous twins by Hysterotomy and not by destructive procedures.




Fig 5

The fetuses were extracted based on antenatal US report by Hysterotomy both newborns were alive for 42 hours. No special investigations could be performed since the new borns started deteriorating after 24 hours.

Specimen radiograms (fig no 5) showed ischiophagus tetrapus with fusion of the ischium. The typical colonic gas shadows were not appreciated in each fetus separately instead a tubular structure resembling large bowel was seen extending from one fetus to the other.

Absence of small bowel shadows was also confirmed on the radiogram.

Gross specimen showed presence of glans penis located posteriorly (fig no6& 7) Testis were not present externally Anal orifice was absent, how ever new borns micturated once through the penis located posteriorly, Attendants were requested to hand over this rare specimen for further investigations was turned down by parents due to social constraints.




Fig 6



Fig 7

DISCUSSION:

All conjoined twins are mono chorionic monoamniotic and account for approximately 4 % of monozygotic twins. [1,2] Incomplete division of the embryonic disc after 13 days and within 2 weeks post conception results in conjoined twins and resultant fusion with shared body parts.[1,2]

The prevalence of conjoined twins is approximately 1 per 50,000 to 1 per 1,00,000 of births; the incidence of conjoined twins is sporadic with no known associations [2]

The nomenclature of the conjoined twins is based on the region of fusion and organs shared. The most common form of conjoined twins is the fusion of the thorax and abdomen referred as thoracophagus or the thoraco omphalophagus [3] other varieties are xiphophagus (fusion of sternum), craniophagus (fusion of skull), cephalophagus (Fusion of face), diprosopus (two face one head), dicephalus (two heads, single trunk)

Cephalothoracophagus (fusion of head and the thorax), thoracophagus (fusion of the thorax), omphalophagus (fusion in the region of umbilicus), paraphagus (fusion of the thorax and abdomen side to side), pygophagus (fusion of the Sacrococcygeal region), rachiphagus (fusion of the spinal column dorsally).[3,4]

Conjoined twins must be suspected in all monochorionic monoamniotic twin pregnancies and careful sonographic assessment be performed to identify the presence of shared fetal organs and other anomalies, this is mandatory to decide the obstetric management as well as prognosis. [1,2]

The index of suspicion of conjoined twins should increase if twins maintain a constant and often unusual relative position and move together with constant hyperextension of the neck and the head.[1,2]

60% of conjoined twins are either still born or lost in utero[3], 35 % of the conjoined twins which are born die within 24 hours of birth[3]. Conjoined twins are most likely to be females (70%),[3,4] this is because male twins are more likely to be miscarried.

Omphalo-Ischiophagus: a combination of omphalophagus and ischiophagus, There have also been reported cases of thoraco-omphalo-ischiophagus and xipho-omphalo-ischiophagus twins. [5]

Ischiophagus: accounts for 6 % of all conjoined twins, [3,4] united from the Umbilicus to a large conjoined pelvis with two sacrums and two pubic sympheses pubis, They are Joined end to end with spine in straight line, four arms and a variable number of legs And in general a single external genitalia and a single anus.

Ischiophagus dipus - Only two legs are present, Twins, this variety is the least common type of ischiophagus twins [3]

Ischiophagus tripus: three legs are present, may have only one set of external genitalia (the other set being present internally)

The third leg may be fused (two legs fused into one) or vestigial (non functioning)

Ischiophagus tetrapus/quadripus: - four legs are present; this is the most common variety of all ischiophagus [3]

REFERENCES:

1. Nyberg D.a, Ultrasound Diagnosis Of Fetal Anomalies, 1990: 592- 622.
2. Rumack, Sonography In Diagnosis And Management Of Conjoined Twins, 2nd Edition, 1063-1064
3. Catherine, Imaging In Pre Op Assessment Of Conjoined Twins, Radiographics 2001, 21: 1187-1208
4. BA Barth, Filly Et Al, Conjoined Twins: Prenatal Diagnosis And Assessment Of Associated Malformations, Radiology 1991 Jan 178(1): 287
5. Xiphomphaloischiophagus Tripus Conjoined Twins Spitz, Journal Of Ped Surg 1991 Jan; 26(1) 26-9

MEDPRO