

# Amorphous Acardiac Parabioc Twin

LG KRISHNA, R UPPOOR, J SHANKAR, SANDHYA.

Ind J Radiol Imag 2005 15:2:267-270

**Keywords:** Acardiac Parabioc Twin, Infantogram, CT scan, Pathological autopsy.

## INTRODUCTION :

Acardiac parabioc twin occurs as a rare, bizarre phenomenon in a monochorionic twin pregnancy as a sequelae of the TRAP (Twin Reversed Arterial Perfusion) sequence. Its incidence is 1 in 35000 deliveries or 1 % of monozygotic twins - said to be 3 times higher among monozygotic triplets than twins. One twin is termed "Acardiac" since it has no heart of its own and thrives as a parasite off the potentially viable, normal "pump" twin, relying on it for its nutrition.

We present a case of acardiac amorphous parabioc twin which was retrospectively diagnosed following twin delivery of an unbooked pregnant woman admitted in labour.

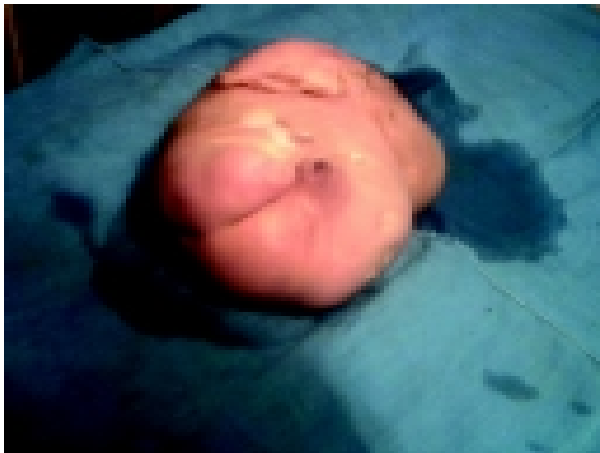

Fig 1

## CASE REPORT :

A 28 year old woman, gravida - 2, para-1, living-1, with a previously undiagnosed twin gestation; at term; presented in labour, was admitted, and subsequently delivered a live, healthy female baby of 2.5 kg birth weight followed by expulsion of another fleshy mass. 3rd stage of labour

progressed uneventfully. The mass was subjected to an infantogram followed by a CT examination which revealed a blob of fleshy mass showing absence of bony cranium, both upper limbs and one lower limb, and a rudimentary lower limb bud on one side. The axial skeletal survey showed an ossified incomplete ring of bony structure at the cranial end of vertebral column suggestive of attempted formation of basi occiput. Spinal column showed 26 somatic elements and vertebrae showed 'C' shaped curvature with segmentation / fusion anomaly of T12 and L1 vertebrae. Thorax showed 12 pairs of rudimentary ribs. There was no evidence of any identifiable organs within the fleshy mass and no identifiable air filled heart chambers were visualized.

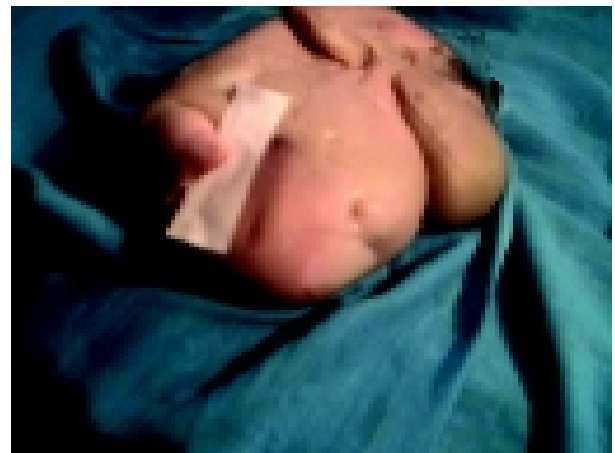

Fig 2

Gross specimen photographs of the fleshy mass showing the umbilical cord attachment (large black arrow), cloaca (white arrowhead), rudimentary lower limb bud (black arrow head), and a tuft of scalp hair (white arrow).

Fig - 3 Infantogram - showing absence of bony cranium, both upper limbs, and a rudimentary lower limb bud on one side. An incomplete bony ring at cranial end; with

From the Department of Radiology, Vijayanagar Institute of Medical Sciences, Cantonment, Bellary-583104

Request for Reprints: Dr. K. Sandhya, Department of Radiology, Vijayanagar Institute of Medical Sciences, Cantonment, Bellary-583104

Received 6 September 2004; Accepted 12 February 2005

partially developed / primitive vertebral column, with rudimentary ribs , rudimentary iliac blades and bony pelvis are also seen.

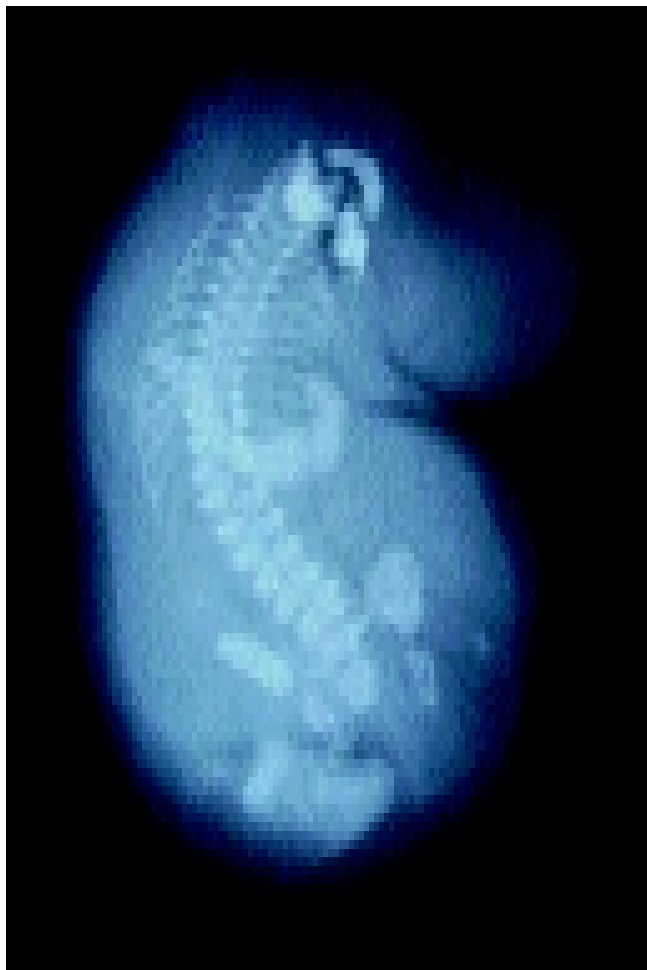

Fig 3

(1) Fig 4 as shown above is an axial plain CT section taken at the cranial end showing an incompletely ossified bony ring suggestive of attempted formation of basi occiput.(2) Fig 5 is an axial CT section taken at the caudal end of the specimen showing incompletely formed bony pelvis with only the right iliac wing visible in this slice.

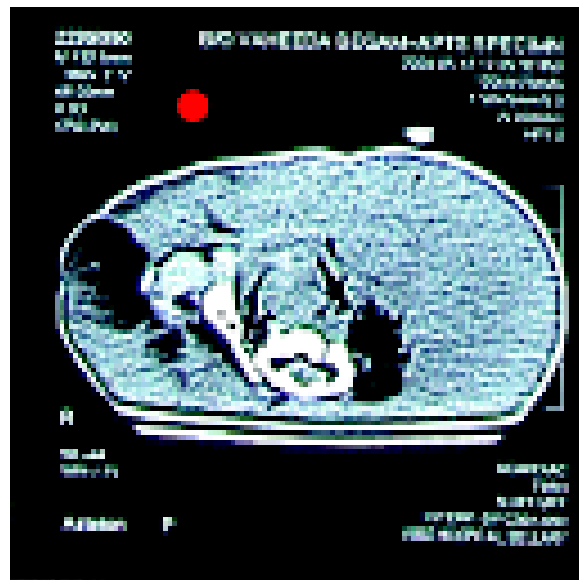


Fig 5

Fig 6 represents a CT section taken through the thoracic region of the specimen which reveals absence of any identifiable cardiac chambers. Note also from figs 4 & 5 that the imaged pelvic and thoracic blood vessels reveal intraluminal air within and there are no identifiable organs within the thoracic, abdominal and pelvic cavities.

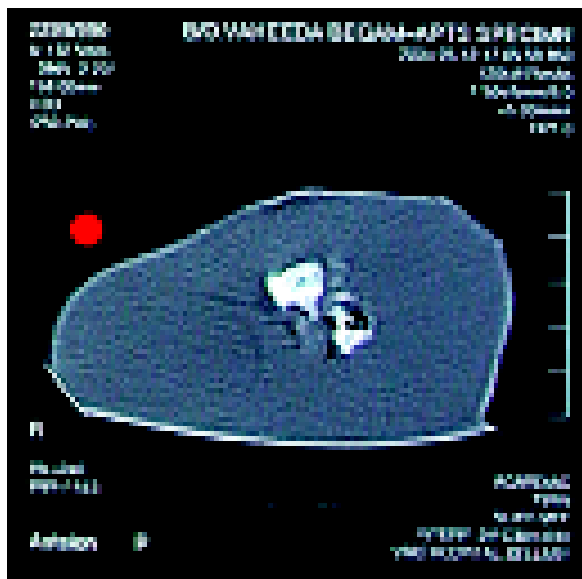


Fig 4

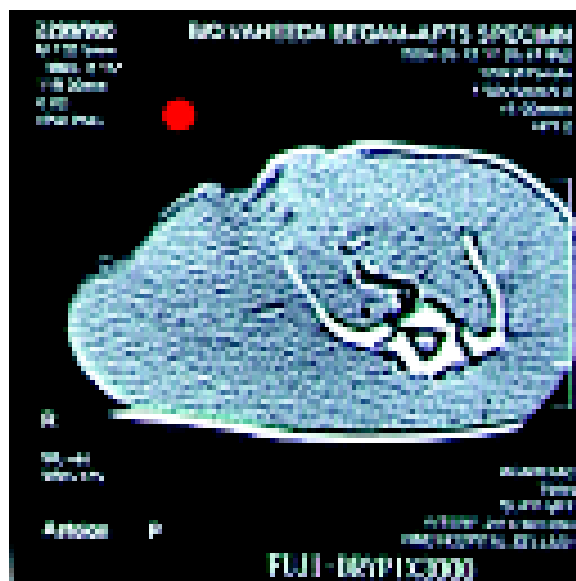


Fig 6

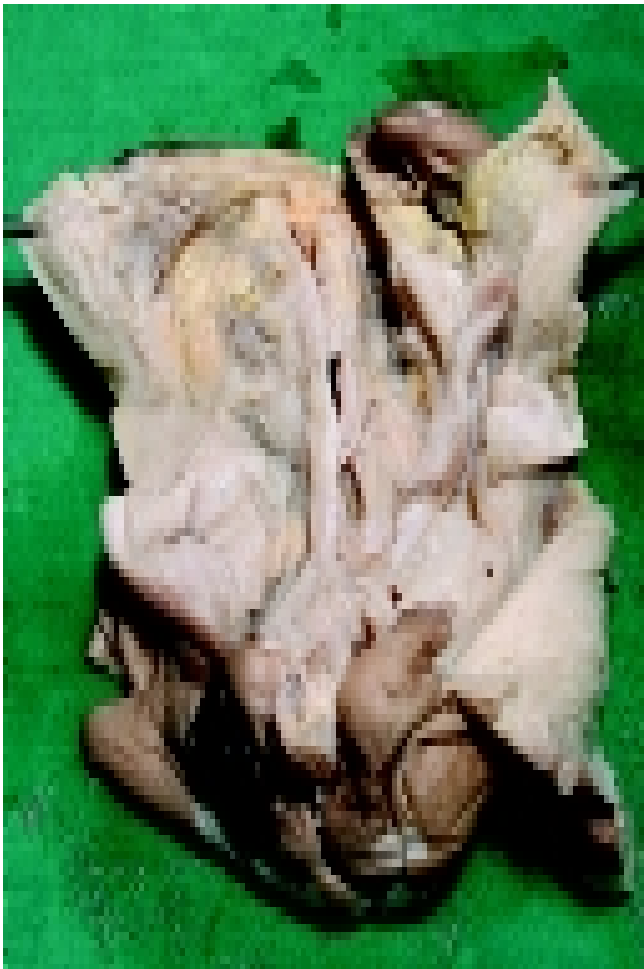

Fig 7

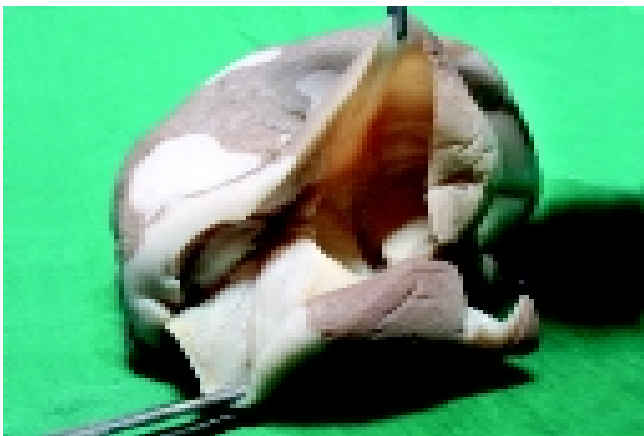

Fig 8

Finally, a pathological autopsy was conducted which revealed absence of any recognizable intra thoracic or intra abdominal organs. The cephalic end consisted of a cavity filled with straw colored fluid lined by epithelium with connective tissue covering. Section from umbilical

cord showed single artery and a vein. The imaging investigations as described above and the autopsy report were consistent with a diagnosis of acardiac twin.

The above figs. are those of the autopsy specimen revealing absence of any identifiable intrathoracic or intraabdominal organs. Fig 8 shows a cavity filled with straw coloured fluid at the cranial end .

#### DISCUSSION :

Acardiac twining is considered to occur as a sequelae of the TRAP sequence in mono chorionic twin pregnancies. The acardiac twin is perfused by the normal co-twin (referred to as the "pump" or "donor" twin) by means of reversal of circulation through large vein to vein anastomosis with in the placenta. The acardiac / recipient twin therefore has no direct vascular communication of its own with the placenta. This reversed circulation in the anomalous twin alters the haemodynamic forces needed for normal cardiac morphogenesis resulting in acardia.

#### ASSOCIATED ANOMALIES :

Preferential perfusion of the parasitic twin's lower body with low pressure hypoxemic blood results in acardia and varying degrees of upper body regression. Other anomalies include - total / partial absence of cranial vault, holoprosencephaly, anencephaly, anophthalmia, absent facial structures, cleft lip and palate, absent or rudimentary heart, diaphragmatic defects, rudimentary limbs, esophageal atresia, ascitis, skin edema and cystic hygroma.

Half of acardiac twins have chromosomal abnormalities. These may also occur in donor foetus especially autosomal trisomies and Klinefelter syndrome. Hence a careful search for malformation in "pump" twin is recommended.

Based on the degree of cephalic and truncal maldevelopment, four types are recognized

1. Acardius anceps : Head & face partially developed.
2. Acardius acephalus : Commonest - 60 - 75 % cases - no cephalic structures.
3. Acardius acornus : Rarest - Head with out body.
4. Acardius amorphous : Formless blob, contains all tissue types with out recognizable organs.

#### DIAGNOSIS :

1. Doppler sonogram of acardiac twin's umbilical vessels shows reversal of normal flow. Umbilical artery S/D ratio of donor twin has been observed to be normal. S/D ratio of the reversed flow in the acardiac twin's

umbilical vein - reported to be elevated - provides a measure of systemic vascular resistance of the acardiac foetus. Acardiac twin's cord contains single umbilical artery in 50 % cases.

2. Fetal echocardiography is essential to evaluate pump twin to look for signs of heart failure.

#### DIFFERENTIAL DIAGNOSIS :

1. Acardiac twin may be mistaken for dead anomalous twin especially when cranial structures are present.
2. Amniotic band syndrome in 3rd trimester foetus.

#### MANAGEMENT :

GOAL OF TREATMENT : To interrupt blood flow to acardiac twin without harming the pump twin. Since fetuses share common placenta and have vascular communications between them, damage to pump twin may occur if safe techniques are not used.

#### 1. USG GUIDED THROMBOSIS OF UMBILICAL CORD :

Though simpler than other approaches, death of pump twin has occurred in over 50 % cases. Umbilical artery should be thrombosed selectively since blood in this vessel flows towards the acardiac twin. If vein is thrombosed, there is risk of emboli traveling back to pump twin. USG guided infusion of absolute alcohol / thrombogenic coils / fibrin can also be attempted.

#### 2. UMBILICAL CORD LIGATION

Endoscopic ligation of acardiac twin's umbilical cord has been attempted successfully. The acardiac twin remains inside the amniotic cavity without harm to mother or pump twin and is passed at the time of delivery. Pump twin is unaffected by the procedure. Success rate - 70 - 80 %. Risks include - technical impossibility, premature rupture of membranes and bleeding.

3. Selective delivery of the abnormal foetus through 2nd trimester hysterotomy (sectio parva) followed by subsequent cesarian section may also be attempted but has been associated with abruptio placentae, preterm labour, preterm birth and prolonged maternal hospitalization.

4. Acardiac pregnancy may be treated with digoxin when there are sonographic signs of cardiac insufficiency of pump twin.

#### 5. RADIO FREQUENCY ABLATION :

A high energy device is used to destroy the blood vessels and surrounding tissue at the site where they enter the acardiac twin, procedure being termed Radiofrequency ablation. Energy is precisely deployed to the desired site using ultrasound guidance; by using color Doppler the energy is applied until blood flow completely stops. This approach has eliminated the need for open surgery or introducing a fetoscope into the uterus.

#### PROGNOSIS :

Overall perinatal mortality is 55 % for the donor twin - this is directly related to weight of the donor and recipient twins; higher the weight of the recipient twin - higher is the likelihood of polyhydramnios, cardiac insufficiency in donor twin, and premature delivery. Moore's ratio or Twin Weight Ratio is defined as - Weight of the acardiac twin expressed as percentage of pump twin weight. When this ratio exceeds 70 %, it results in significantly higher incidence of the above complications.

#### REFERENCES :

1. Moor T. R. et al - Perinatal outcome of 49 pregnancies complicated by Acardiac twinning. American Journal of Obstetrics And Gynaecology - 163:907 , 1990.
2. Sheer D . M. et al - Prenatal sonographic , Diagnostic Doppler Velocimetric Umbilical Cord Studies And Subsequent Management Of An Acardiac Twin Pregnancy : Obstetrics And Gynaecology 74 : 472-75 ; 1989.
3. Acton C. M. And Woodward C. S. : Acardiac Twins. Australas radiology. 37 (4) : 389 - 92 : 1993.
4. Izquierdo L , Smith J . Gilson G . et al : Twin, Acardiac , Acephalus. Fetus ; 1-3 : 1991.
5. Mohanty C. , Mishra O.P. ,Singh C.P., Das B.K. And Singha P.N. : Acardiac Anamoly Spectrum. Tetralogy , 62(5) : 356 - 59 : 2000.
6. Nerlich A Wisser J. Draeger A et al : Human Acardiac Anamoly - A Report Of Three Cases. European Journal Of Obstetrics And Gynaecology - 38 : 79 - 85 : 1990.
7. Nyberg D. A. Pretorius D.H. : Diagnostic Ultrasound Of Fetal Anamolies ; Text And Atlas . St. Louis , M O ; Mosby , Year Book . 1990 , pgs 608 - 609.
8. Pezzati M. Cianciulli. D And Danesi G : Acardiac Twins - Two case Reports . Journal Of Perinatal Medicine ; 25 (1) : 119 - 24 : 1997.