Article published online: 2021-08-02

3 Tesla MRI - A New Workhorse

DR SHRINIVAS B. DESAI
Editor-in-Chief

Ind J Radiol Imag 2006 16:3:281-282

For past few years a wide speculation and debate is centered around the clinical utility of 3 TESLA MRI. Both, highly optimistic and cautious opinions have been expressed by different workers. Today it has been proved. It is more than a glorified high Tec microscope. It can delineate structures that have not been seen before such as blood vessels as small as 200-300 microns, almost going down to ultrastructural level. We have been using 3T MRI since past more than a month and can confidently say that 3T can do anything which present workhorse 1.5T MR can do and do it faster and better.

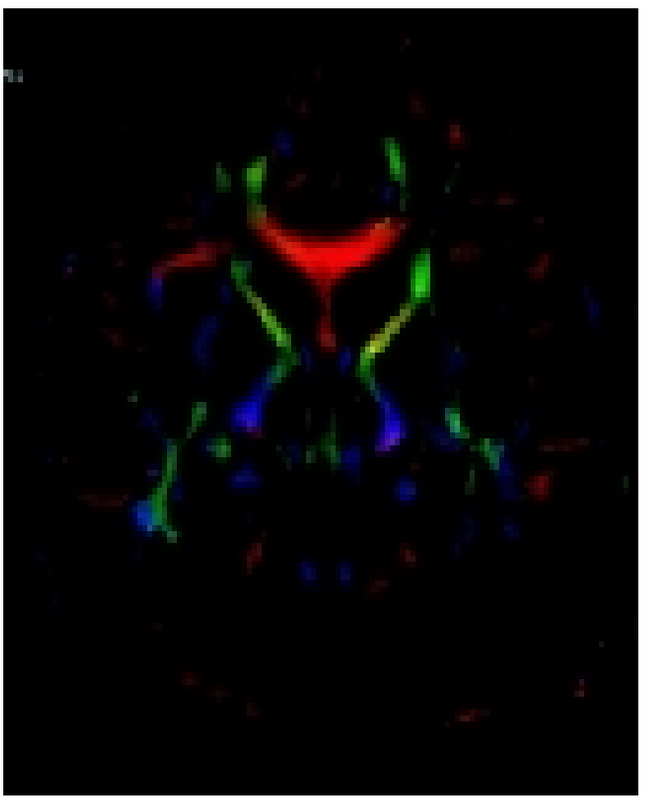

Figure 1: Normal Diffusion Tensor Map

With increasing field strength, it is a common knowledge that SNR (signal to noise ratio) also increases. With 3 to 4 fold higher SNR 3T can more precisely localize areas of activation, enabling accurate mapping of brain function in patients more than 90-95% of the time. 3T MRI is already established as a gold standard for functional brain imaging (fMRI). According to Dr. Keith Tulborn of university of Illinois, 3T MRI makes potentially insensitive techniques clinically robust.

On 3T, direct cortical mapping and perfusion studies plot patients physiology upto the edge of the lesion and DTI (diffusion tensor imaging) trace white matter tracks that need to be persevered during surgery, for excellent presurgical evaluation. 1.5T BOLD imaging results in the signal changes in the order of 1% to 2% while on 3T signal change increased to 3-5%. This helps in highly reliable patient mapping and interpretation.

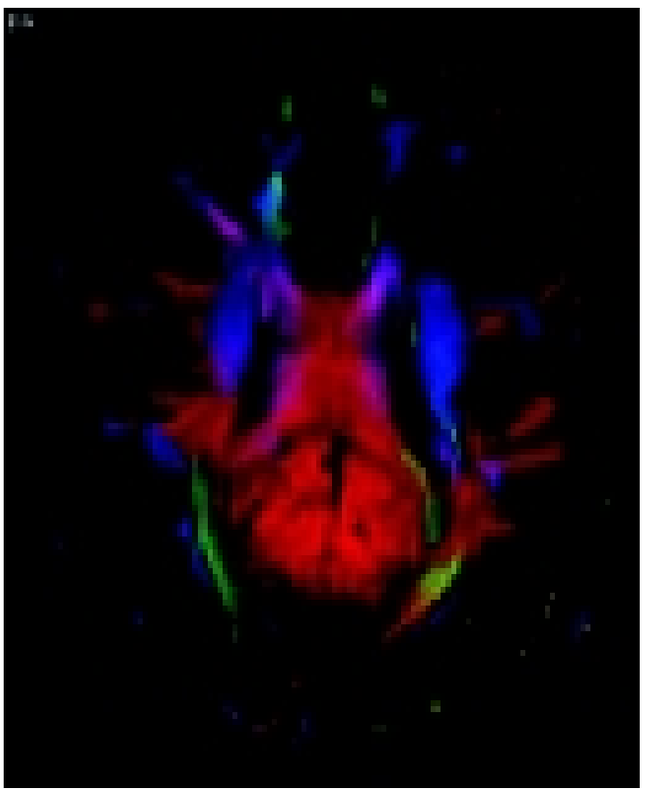

Figure 2 : Diffusion tensor map withfocal lesion in left fronto-parietal white matter

3T helps in identifying the areas of abnormality during rehabilitation in patients with cognitive impairment after proper treatment of acquired brain injuries.

The quality and resolution of spectroscopy is of a very high order on 3 TESLA MRI. More peaks are identified and there is marked improvement in the separation of the peaks in spectroscopy, thereby profoundly improving interpretation quality and reducing the time. The spectra can be obtained in 2 to 3 minutes. Contrary to common belief, 3T MRI can perform super-fast imaging without sacrificing image quality in the body. Speed in the past

was achieved by gradient structure, however, now other technologies like parallel imaging have removed hardware constraints. Transition from 1.5 to 3T body imaging have actually been easier both from an engineering as well as an optimization prospective because all the manufacturer have over come the problem of specific absorption rate (SAR). With software and body coil engineering design clinical 3T MRI virtually matches all the 1.5T SAR performance standards and hence, preserves the definite increase in signal to noise. New 3T machines have much higher slew rates and higher gradient performers

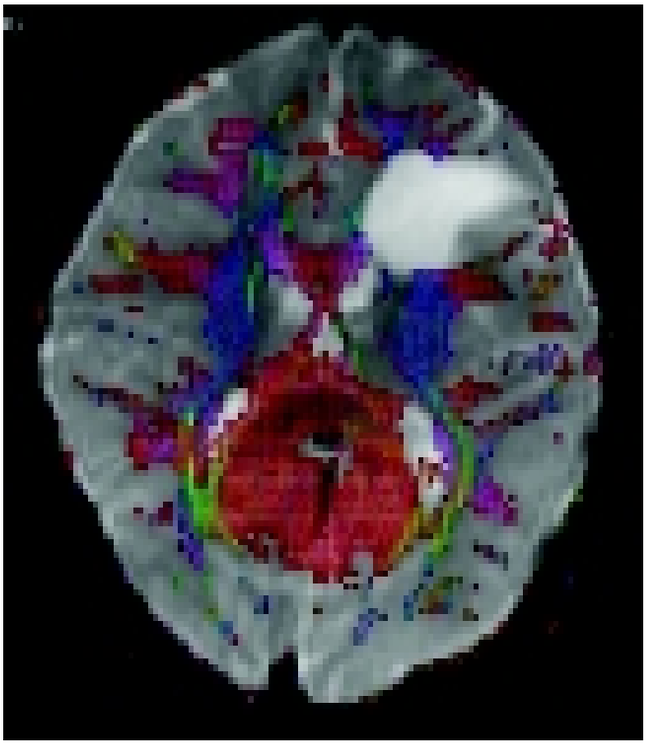

Figure 3: DTI with anatomical map

T1 WI images needs special attention on 3T as it is slightly longer and hence produces greater inflow enhancement and background suppression. We have circumvented the problem of prolonged T1 at 3T obscuring gray white matter differentiation on SE images by using 3D T1 WI MP rage, obtained with 1mm isotropic voxel with 256 x 256 matrices. The gray and white matter differentiation is significantly greater by using this sequence than SE sequence at any field strength.

Though T2 WI imaging has been considered as main strength of the 3T MRI, we have found all the different types of the sequence yielded better results on 3T, SWI done at 3T reveals more pathologies in finer details than 1.5T

3T has been found superior in musculoskeletal MR due to improved image quality and spatial resolution. The articular cartilage imaging is exceptional on 3T. In recent years the treatment options for cartilage defects and degenerative damage of cartilage have undergone substantial changes and hence, better imaging of cartilage for qualitative and quantitative assessment has become mandatory. It provides superior bone muscle and bone cartilage contrast and better visibility of intercarpal ligaments, cartilage, median and ulner nerves. With its higher spatral resolution capability 3T is ideal for imaging trabecular bone with trabecular size of 50-200 micrometers. High spatral resolution of 3T is also useful to better demonstrate tendonitis, partial and complete tendon tear and labrum of shoulder and hip joints, which are many a times insufficiently evaluated and seen with 1.5T systems. MR arthrography would be excellent with contrast resolution on 3T.

Figure 4: Dess imaging of shoulderjoint

The fast imaging possibility has yielded very high quality liver imaging in our practice. The quality of abdominal imaging is surprisingly better than 1.5T, opening many vistas of more evaluation.

We are convinced that the radiologist thinking of using 3T as a stand alone MRI should not be worried. We have not come across a single SAR error problem with brain or body imaging in last more than 500 patients. We are in agreement with other authors like Dr. Ross etc., opinion that MR angiogram, diffusion MR, new MR sequences in CNS studies, FMRI and many other newer sequences are better at higher field strength. The increased signal to noise at 3T has significantly improved our diffusion weighted and ADC images and resulted into better perfusion studies.

Our experience with 3T MR imaging in more than 500 patients over the last 1 ½ month has been excellent.