

Hypertrophic Pulmonary Osteoarthropathy Detected By Tc-99m MDP Bone Scintigraphy. A Case Report And Review of Literature

A SREEKUMAR

Ind J Radiol Imag 2006 16:1:17-18

Keywords: Hypertrophic osteoarthropathy, bone scintigraphy

INTRODUCTION

Hypertrophic pulmonary osteoarthropathy is a syndrome characterized by proliferative changes in the skin and skeleton. Proliferative periostitis of the long bones, oligopolysynovitis and digital clubbing are also common. There are two types of hypertrophic osteoarthropathy; primary and secondary. Secondary hypertrophic osteoarthropathy is more common than the primary and is seen in association with many disease conditions of the cardiovascular, hepatobiliary gastrointestinal and also in malignancies. Among the malignancies, carcinoma of the lung and breast are the commonest, which produces hypertrophic osteoarthropathy. Bone scintigraphy with Tc-99m MDP [Methylene Diphosphonate] is a sensitive investigation in the detection of hypertrophic osteoarthropathy.

CASE REPORT

A sixty five-year-old male patient presented with cough and haemoptysis of three months duration. Chest radiograph showed a homogeneous mass in the right upper zone. A fine needle aspiration done revealed small cell carcinoma lung. A Tc-99m MDP bone scan was performed as a part of initial work up to rule out skeletal metastases.

BONE SCINTIGRAPHY FINDINGS

Bone scan shows intense bilateral symmetrical cortical uptake of radiopharmaceutical in both tibia, fibula and femur (Fig 1a, 1b). Humerus, radius and ulna show increased uptake of radiopharmaceutical in the distal ends (Fig 2a, 2b). The medullary cavities of the long bones were not involved. The axial skeletons were also not involved. The diagnosis of hypertrophic osteoarthropathy was made out based on the typical bone scintigraphy findings.

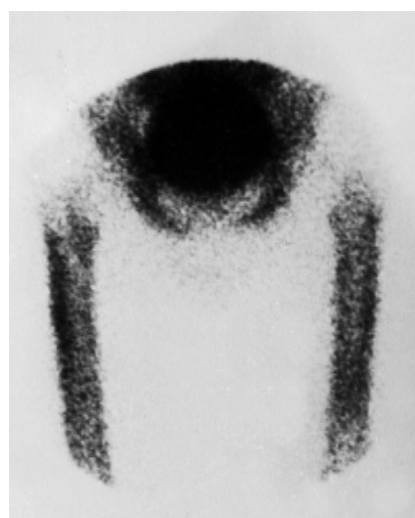
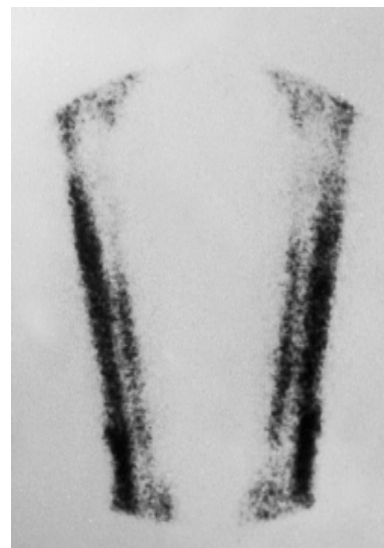
Fig 1a, 1b Bone scan showing intense bilateral symmetrical cortical uptake of Tc-99m MDP in tibia, fibula and femur, consistent with "Hypertrophic osteoarthropathy". The characteristic "tram line" sign is also seen.

From the Regional Cancer Center, Medical, College PO, TRIVANDRUM - 695011

Request for Reprints: Dr. Sreekumar A, Associate Professor of Nuclear Medicine, Regional Cancer Center, Medical, College PO, TRIVANDRUM - 695011

Received 6 April 2005; Accepted 12 September 2005

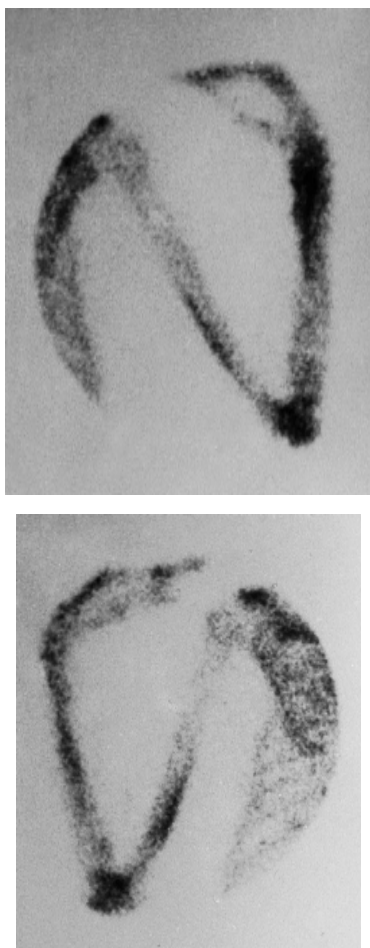


Fig 2a 2b Humerus, radius and ulna showing increased uptake of Tc-99m MDP in the distal ends.

DISCUSSION

Hypertrophic osteoarthropathy (HOA) is a syndrome characterized by digital clubbing and periostosis of the tubular bones. The syndrome can be primary or secondary. Primary HOA, or pachydermoperiostosis, is a rare familial autosomal dominant condition. About 3-5% of patients with HOA have primary HOA [1]. The remaining 95-97% have secondary HOA, or hypertrophic pulmonary osteoarthropathy (HPOA). The term HPOA emphasizes the pulmonary problems that represent a major cause of periostitis, although conditions other than pulmonary disorders may cause HPOA. This syndrome mainly affects the distal aspects of the extremities and then gradually progresses proximally. Secondary causes of HPOA can be subdivided into pulmonary, pleural, cardiac, abdominal, and miscellaneous [2]. Pleural causes include pleural fibroma and mesothelioma. Cyanotic heart disease with a right-to-left shunt is the only cardiac cause described.

Pulmonary causes include bronchogenic carcinoma; pulmonary tuberculosis; pulmonary abscesses; blastomycosis; bronchiectasis; emphysema; and *Pneumocystis carinii* infection in patients with AIDS, Hodgkin disease, metastases, or cystic fibrosis.

Abdominal causes include liver cirrhosis, ulcerative colitis, Crohn disease, amebic and bacillary dysentery, gastrointestinal tract polyposis, gastrointestinal tract neoplasm's (gastric and pancreatic), lymphoma of the bowel, Whipple disease, and biliary atresia. Among the malignancy carcinoma of the lung and breast are the commonest causes for hypertrophic osteoarthropathy. Nasopharyngeal and esophageal carcinoma also can cause hypertrophic osteoarthropathy. Miscellaneous causes include infected aortic or axillary artery grafts and sarcoidosis. The exact pathogenesis of hypertrophic osteoarthropathy is not known current theory states that it is secondary to faulty pulmonary clearance of macrothrombocytes that lodge in distal capillary beds and release growth factors leading to stimulation of fibroblasts which results in cell growth and collagen synthesis [3]. Bone scintigraphy is very sensitive in detecting hypertrophic osteoarthropathy. The scintigraphic findings characteristics of hypertrophic osteoarthropathy are bilateral symmetrical increased uptake of the radiopharmaceutical along the cortical margins of the long bones. Due to the typical appearance it is also known as "tram line" or "double stripe" sign [4]. Associated synovitis can cause increased uptake in periarticular regions. About 5% to 12% of patients with bronchogenic carcinoma develop hypertrophic osteoarthropathy [5]. It is mostly seen in small cell carcinoma. In a study done by Ali et al [6] the extremities were always involved. The commonest sites were tibia and fibula. The second commonest sites of involvement were the femurs and the radius and ulna symmetric and regular pattern of cortical uptake was seen in 83% of the patients. After treatment of the associated disease, there would be rapid regression of the scintigraphic changes. Recurrence of the primary disease is often associated with recurrence of hypertrophic osteoarthropathy. The absence of medullary cavity involvement of the long bones and absence of axial skeletal involvement distinguishes hypertrophic osteoarthropathy from metastatic involvement of the bones.

REFERENCES

1. Martinez-Lavin M, Pineda C, Valdez T, et al: Primary hypertrophic osteoarthropathy. *Semin Arthritis Rheum* 1988 Feb; 17(3): 156-62.
2. Epstein O, Ajdukiewicz AB, Dick R, Sherlock S: Hypertrophic hepatic osteoarthropathy. Clinical, roentgenologic, biochemical, hormonal and cardiorespiratory studies, and review of the literature. *Am J Med* 1979 Jul; 67(1): 88-97
3. Martinez-Lavin M. Pathogenesis of hypertrophic osteoarthropathy. *Clin Exp Rheumatol* 1992 May-June 10 Suppl 7.
4. Rosenthal, et al. Observations on radionuclide imaging in hypertrophic pulmonary osteoarthropathy. *Radiology* 1976; 120 : 359- 362.
5. Freeman N H, Tonkin A K, Manifestations of hypertrophic pulmonary osteoarthropathy in patients with carcinoma of the lung. *Radiology* 120 : 363- 365.
6. Ali, A, Tetalman M R, Fordham E W et al, Distribution of hypertrophic pulmonary osteoarthropathy. *Am. J. Roentgenol* 134 : 771- 780.