

Aneurysmal Bone Cyst Of Sacrum - A Case Report

A SHAH, P LUTHRA, AR MAHALE, A KUMAR, A VENUGOPAL, V POORNIMA

Ind J Radiol Imag 2006 16:1:19-21

Keywords: ABC, Sacrum, Bone tumor

INTRODUCTION

The origin of the term "aneurysmal bone cyst" stems from two cases reported by Jaffe and Lichtenstein in their article on unicameral bone cysts in 1942. In that report, they noted two "peculiar blood-containing cysts of large size," which they described as aneurysmal cysts. Aneurysmal bone cysts are expansile, lytic lesions of bone, which on pathologic examination are seen to consist of thin-walled, blood-filled cavities lacking normal endothelium and elastic lamina.

We would like to present a case of aneurysmal bone cyst of sacrum. A rare presentation of the lesion in the vertebral body with no/minimal septations and distinct fluid-fluid level in our patient.

CASE REPORT

A thirteen-year-old female child presented with pain in the region of left hip for one month of duration. The pain was not well localized. Patient also complained of radiation of pain to left thigh and difficulty in walking. On examination, there was no localized tenderness in the region of sacrum on the left side. Hematological examinations showed mild elevation of total leukocyte count with neutrophilia. Peripheral smear showed neutrophilic leucocytosis with toxic granulations within neutrophils. Erythrocyte sedimentation rate was in normal limits. Radiograph of pelvis showed a lytic lesion with well-defined margins in the ala of sacrum on the left side. There were no septations; no sclerosis of margins. Ultrasonographic study of abdomen did not demonstrate any abnormality. Magnetic Resonance study was done on GE signa profile 0.2 T machine, which showed hyperintensity involving the presacral space at S1 level on T2WI measuring about 67 x 35 mm on left side. S1 vertebral body showed hyperintense signal with fluid - fluid level and decrease in body height on T2WI. (Spinal canal dimensions were within normal limits). Spinal canal showed hyperintense signal within, with displacement of

the cal sac to the right side. Neural foramina at S1 level on left side showed hyperintense signal within. Intervertebral disc contours and signal intensities were preserved at all visualized levels (fig. 1).

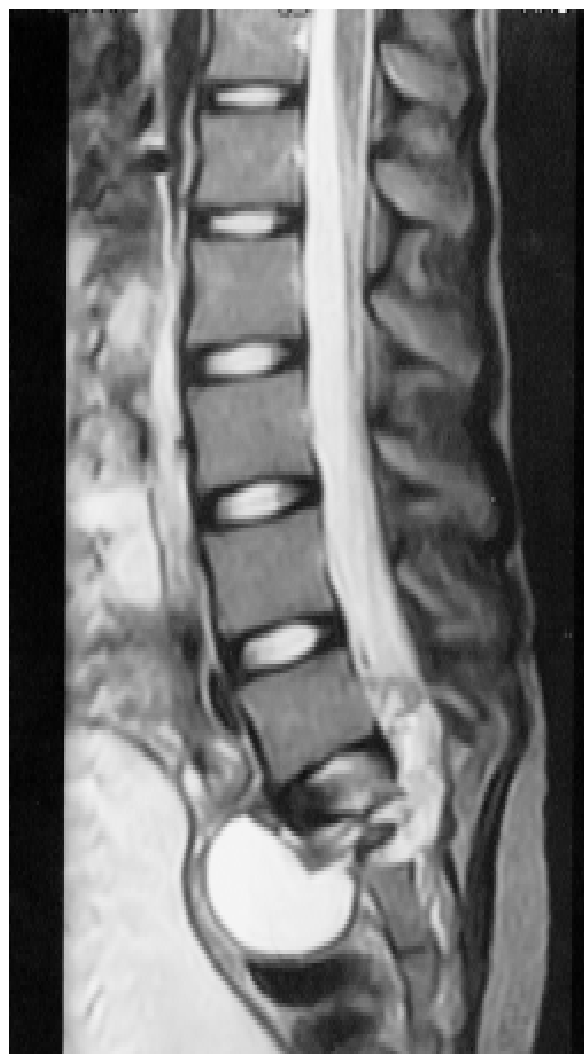

FIGURE 1: - S1 vertebral body shows hyperintense signal with fluid - fluid level and decrease in body height on T2 weighted images.

From the Department of Radio diagnosis and Imaging, Kasturba Medical College, Mangalore - 575001 India

Request for Reprints: DR. ANKUR SHAH, Department of Radio diagnosis and Imaging, Kasturba Medical College, Attavar, Mangalore - 575001

Received 20 April 2005; Accepted 10 October 2005

MR study was followed by the FNAC from this cystic mass lesion from the wall of the cyst. Histopathological morphology was suggestive of aneurysmal bone cyst. The case was taken up for surgery for drainage of the lesion by retroperitoneal approach under general anesthesia and a sanguinous fluid filled cavity with a feeding blood vessel was found which was coiled and curettage of the cavity done with out filling it with bone chips (fig. 2).

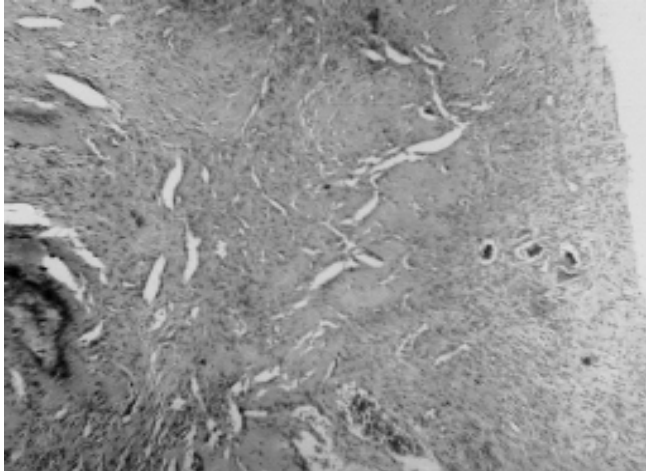


FIGURE 2: - Spindle cells with ill defined cytoplasmic borders and multinucleate osteoclastic giant cells- features of aneurysmal bone cyst.

DISCUSSION:-

The origin of the term "aneurysmal bone cyst" stems from two cases reported by Jaffe and Lichtenstein in their article on unicameral bone cysts in 1942 in that report, they noted two "peculiar blood-containing cysts of large size," which they described as aneurysmal cysts. In a subsequent paper, Jaffe chose the name "aneurysmal bone cyst" as the descriptive term for this lesion, with the word "aneurysmal" to emphasize the "blown-out," distended contour of the affected bone, and the words "bone cyst" to underscore that when the lesion is entered through a thin shell of bone, it appears largely as a blood-filled cavity. [1]

Aneurysmal bone cysts are expansile, lytic lesions of bone, which on pathologic examination are seen to consist of thin-walled, blood-filled cavities lacking normal endothelium and elastic lamina. [2]

Tubular bones

The classic description of an aneurysmal bone cyst includes an eccentric radiolucency and a purely lytic, or, occasionally, trabecular process, with its epicenter in the metaphysis of an unfused long bone.

The trabeculae in the cyst may create a soap-bubble appearance in the lesion.

The margins of the lesion are well defined, with a smooth inner margin and a rim of bone sclerosis. The tumor does not usually extend into the Epiphyseal plate until after complete fusion, when it may occasionally do so. [3] Epiphyseal lesions are usually intramedullary and associated with chondroblastoma or giant cell tumor. [1] The expansion or ballooning of the cortex occasionally may result in the loss of the sharp definition of its margin. In this case, the finding should correctly be interpreted as an aggressive lesion rather than a solely diagnostic of malignant change.

New bone may horizontally traverse the angle between the original cortex and the expanded part of the bone; this occurs because the periosteum is lifted. No periosteal reaction occurs, except when the periosteum is fractured. [3]

Spine

Typically, the spinal lesion is osteolytic, with a predilection for the posterior elements. [3] Spine involvement is typically in the posterior elements, although extension into the vertebral body is common (75%). Involvement localized to the vertebral body is rare, and associated scoliosis and kyphosis are present in more than 10% of patients. Spinal lesions commonly will cause compression of the spinal cord or nerves. [1]

Other locations

As in the innominate bones, flat bones have osteolysis with an expansile lesion. Expanded bone may displace the adjacent viscera, such as urinary bladder, when they occur in pelvis.

Lesions in the skull have osteolysis, with expansion of both inner and outer tables with intracranial extension.

Mandibular and maxillary lesions are multilocular, expansile, and osteolytic. They predominate in the region of the molar teeth.

Aneurysmal bone cysts are difficult to distinguish from malignant lesions in some locations. It may mimic a sarcoma in the ribs, scapula, or sternum, especially when associated with a large soft-tissue component. [3]

MR findings: T1- weighted images show predominantly low-to-intermediate signal intensity with or without fluid levels. Acute hemorrhage into the cyst may have high signal intensity.

T2-weighted images show areas of low-to-intermediate signal intensity or some areas of heterogeneous high signal intensity, depending on the contents of the cyst. A rim of low signal intensity with internal septa may produce

IJRI, 16:1, February 2006

a multicystic appearance.

MRI images of aggressive lesions show tumor enhancement with gadolinium enhancement, especially when they are associated with other tumors. [3]

The MR images showed a number of features that would be expected from the classic plain film findings of aneurysmal bone cyst. All lesions had an expansile appearance, and many had lobulations. These lobulations often were small and have been referred to as diverticula. [4]

In general, the signal intensity increases with increasing T2 weighting. The distinctness of the fluid levels seen with the cysts may vary with the degree of T2 weighting, suggesting that if only a single sequence is obtained, fluid levels may not be seen.

The constellation of (1) a young patient, (2) an expansile lesion bordered by a thin low-signal rim, (3) increasing signal with augmented T2 weighting, and (4) possibly a lobulated contour and/or fluid levels within it strongly suggests the diagnosis of aneurysmal bone cyst. [2]

Recently, embolotherapy has been used to treat vascular bone tumors to limit blood loss at surgery or as definitive therapy when surgery is not feasible. Transcatheter selective arterial embolization has proved useful in this

Aneurysmal Bone Cyst of Sacrum 21

regard, either by itself or in combination with surgery. The goal of embolization is occlusion of the vascular supply of the lesion without interfering with the vascularity of surrounding tissue or structures. Various materials have been used, depending on the size of the vessels involved and the therapeutic indications. [1]

Our patient showed atypical presentation with vertebral body involvement, no/minimal septations and indistinct fluid level.

REFERENCES

- 1) Mark J. Kransdorf and Donald E. Sweet. Aneurysmal bone cyst: Concept, Controversy, Clinical Presentation, and Imaging. *AJR* 1995;164:573-580
- 2) Peter L. Munk, Clyde A. Helms, R. Gary Holt, James Johnston, Lynn Steinbach and Christian Neumann. MR Imaging of Aneurysmal Bone Cysts. *AJR* 153:99-101, July 1989
- 3) Mahesh Kumar Neelala Anand, Eric A Wang. Aneurysmal Bone Cyst: Medicine / Radiology March 2004.
- 4) Beltran J, Simon DC, Levy M, Herman L, Weis L, Mueller CF. Aneurysmal bone cysts: MR imaging at 1.5 T. *Radiology* 1986; 158:689-690