

Arrhythmogenic Right Ventricular Dysplasia; Radiologic Findings Of The Left Ventricle: A Case Report And Review Of The Literature

K ARDA, N CILEDAG, F KACMAZ, O TUFEKCIOGLU, Y SEREFLISAN

Abstract

Arrhythmogenic right ventricular dysplasia (ARVD) is characterized by progressive fibro fatty replacement of the right ventricular myocardium which constitutes a substrate for electrical instability and a focus of ventricular arrhythmias. Most of the patients have some degree of left ventricular involvement which also affects the right ventricle by the same disease process. From thirty percent to 50% of patients with ARVD have a family history of the disease. The most common pattern of inheritance is autosomal dominant. Clinically, ARVD usually presents with ventricular arrhythmias, and there is approving evidence that this is the underlying disease in a substantial number of sudden deaths among young, especially healthy individuals. The diagnosis of ARVD relies on the presence of structural and functional abnormalities of the right ventricle, electrophysiological abnormalities, and family history. The imaging modalities are conventional angiography, echocardiography (ECO), radionuclide angiography, ultra fast computed tomography, and magnetic resonance imaging. (MRI). We are presenting a case of ARVD with ECO, computed tomography (CT), and MRI findings.

Ind J Radiol Imag 2006 16:1:131-134

Keywords: Dysplasia, Arrhythmia, Arrhythmogenic right ventricular dysplasia, Magnetic resonance image, computed tomography, echocardiography

INTRODUCTION

ARVD is clinically characterized by ventricular arrhythmias with left bundle branch block (LBBB) which may lead to cardiac arrest and morphologically by fatty or fibro fatty infiltration of the right ventricular myocardium (1-7). Most of the patients have some degree of left ventricular involvement which also affects the right ventricle by the same disease process (4). Several reports suggest that there is a familial occurrence of ARVD of about 30%-50% (2), with mainly autosomal dominant inheritance, various penetrance, and polymorphic phenotypic expression (1, 7, 8). Although incidence and prevalence of ARVD are unknown, ARVD is recognized as a major cause of sudden death in young adolescents, and in one series it was found that 20% of sudden deaths in the individuals younger than 35 and 22% of sudden deaths in young athletes were caused by ARVD (1, 8). Therefore, an early and accurate diagnosis followed by appropriate therapy for this condition is increasingly becoming important as it may prevent lethal arrhythmias. We are

reporting a 28-year-old-man with ARVD. The diagnosis was achieved by CT and MR imaging, that showed fatty infiltration of right and ventricle wall and was confirmed with the echocardiography findings.

CASE REPORT

A 28 year-old-man admitted to our hospital for evaluation of long staining palpitation and recurrent syncope. His physical examination was normal other than arrhythmic cardiac pulse. T-wave inversion in the right precordial leads and ventricular premature beats with left bundle branch block morphology was present in ECG.

Holter monitor recordings revealed runs of sustained ventricular tachycardia episodes (Figure 1).

Transthoracic Echocardiography (TTE) showed right ventricular dilatation with reduced systolic function (%37-38 ejection fraction), dyskinesia and severely attenuated systolic thickening in the free wall (systolic thickness:

From the Türkiye Yüksek İhtisas Hospital, Department of Radiology, Sıhhiye Ankara TURKEY

Request for Reprints: Kemal Arda, MD, Türkiye Yüksek İhtisas Hospital, Department of Radiology, Sıhhiye Ankara TURKEY

Received 14 October 2005; Accepted 10 March 2006

3mm) (Figure 2).

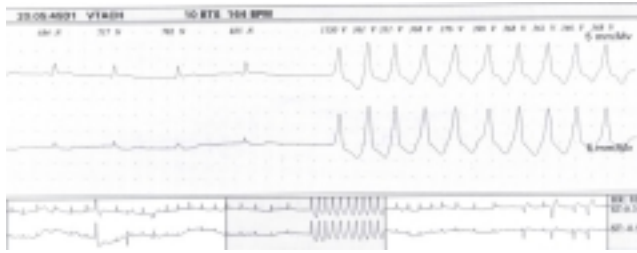

Figure 1. Holter monitorization showed episodes of sustained ventricular tachycardia in the form of LBBB (Originating from the right ventricle).

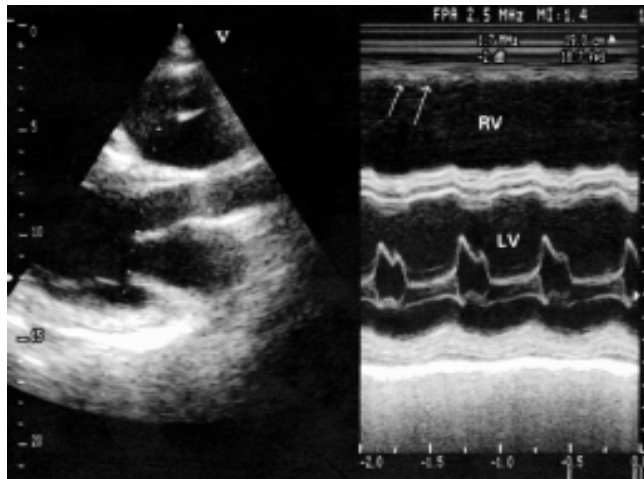


Figure 2. M-mode echocardiography shows thinning and marked reduced systolic thickening in the right ventricular wall (arrows). Note the dilatation and attenuated systolic functions of the right and left ventricles (LV, left ventricle; RV, right ventricle).

CT scans showed fatty infiltration (in minus HU values) in the subepicardial myocardium of the left ventricle wall and also showed that the thickness of the left ventricle wall was 2 mm (Figure 3).

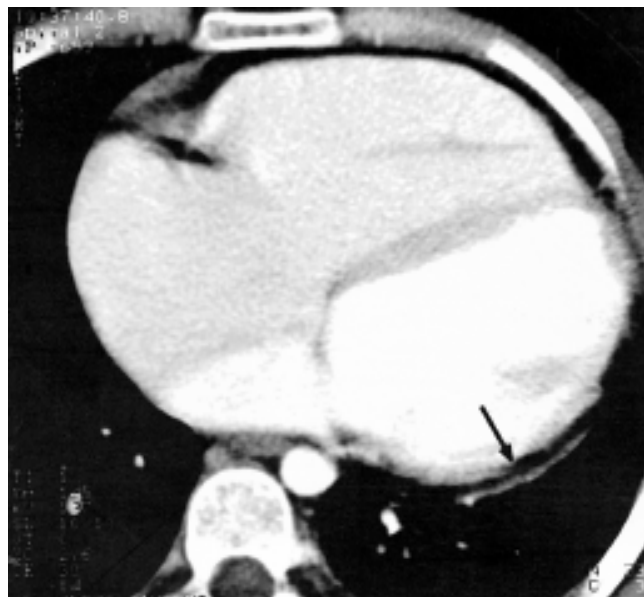

Figure 3. CT scans showed fatty infiltration in the myocardium of the left ventricle wall and also showed that the thickness of the left ventricle wall was 2 mm.

MR imaging revealed bulging of the right ventricle free wall in end-diastole, absence of systolic thickening, fibrofatty infiltration and enlargement in the left ventricle outflow tract (Figure 4).

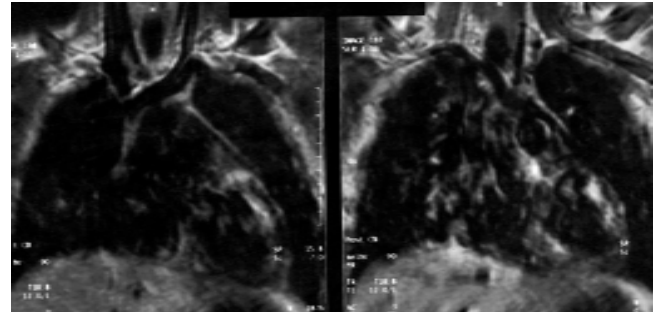


Figure 4. T1 weighted MR image shows thinning and high signal intensity of fat in the left ventricular wall.

β blocker therapy (metoprolol 100mg/day) was started and an AICD (Automated Implantable Cardioverter Defibrillator) was implanted successfully and this treatment provided good symptomatic relief.

DISCUSSION

ARVD is characterized by fibro fatty replacement of the right ventricle myocardium pathologically and by right ventricular arrhythmias clinically. In most of the ARVD patients, some degree of left ventricular involvement is seen. Biventricular involvement is usual, but isolated left ventricular involvement is a rare condition.

In our case both right and left ventricular involvement was diagnosed.

ARVD is an important cause of sudden death among young people. Pathogenesis, prevalence, and etiology are not fully known yet. The diagnosis at an early stage is essential. McKenna et al (1) reported the diagnostic criteria of ARVD, which are based on the presence of structural, histological, electrocardiograph cal findings and arrhythmic, genetic factors (Table 1). The detection of functional and structural alternations are realized with echocardiography, conventional angiography, CT, MRI, or radionuclide angiography. Two major, one major and two minor, or four minor criteria is sufficient for the diagnosis of ARVD

Table 1. Criteria for Diagnosis of Arrhythmogenic Right Ventricular Dysplasia/Cardiomyopathy(3)

- I. Family history
 - Major criteria
 - Familial disease confirmed at necropsy or surgery
 - Minor criteria

- Family history of premature sudden death (at <35 years) caused by suspected ARVD
Family history (clinical diagnosis based on present criteria)
- II. ECG depolarisation/conduction abnormalities
 - Major criteria
 - Epsilon waves or localized prolongation (=110 msec) of the QRS complex in right precordial leads (V1-V3)
 - Minor criteria
 - Late potentials seen on signal averaged electrocardiography
 - III. ECG repolarisation abnormalities
 - Minor criteria
 - Inverted T waves in right precordial leads (V2 and V3) in people older than 12 years and in the absence of right bundle branch block
 - IV. Arrhythmias
 - Minor criteria
 - Sustained or nonsustained left bundle branch block type ventricular tachycardia documented on the ECG, Holter monitoring or during exercise testing
 - Frequent ventricular extrasystoles (more than 1000/24 hours on Holter monitoring)
 - V. Global and/or regional dysfunction and structural alterations
 - Major criteria
 - Severe dilatation and reduction of right ventricular ejection fraction with no (or only mild) left ventricular involvement
 - Localized right ventricular aneurysms (akinetic or dyskinetic areas with diastolic bulging)
 - Severe segmental dilatation of the right ventricle
 - Minor criteria
 - Mild global right ventricular dilatation and/or ejection fraction reduction with normal left ventricle
 - Mild segmental dilatation of the right ventricle
 - Regional hypokinesia of the right ventricle
 - VI. Tissue characterization of walls
 - Major criteria
 - Fibrofatty replacement of myocardium at endomyocardial biopsy

Kimura et al (5) and Kayser et al (1) reported CT and MRI findings of ARVD.

We added CT and MRI findings of our case and made a table of CT and MRI findings for the diagnosis of ARVD (Table 2) (1, 5, 14).

Table 2. CT and MRI findings of ARVC (5,8,14)

CT findings

- a) Fatty density in the subepicardial myocardium of the right ventricular wall,
- b) To become thinning of right ventricular free wall,
- c) Enlarged myocardial trabeculae of anterior and inferior walls,

- d) Fatty tissue in the left ventricular free wall and in the ventricular septum,
 - e) Diastolic bulging of the free wall of the right ventricle,
 - g) Abnormal and reduced wall functions of the right ventricle,
 - h) Dilatation of right ventricle,
 - i) Right ventricle outflow tract > left ventricle outflow tract
- MR imaging findings
- I. Spin-Echo technique
 - a) On T1 weighted images, characteristic high signal intensity of fat in the right ventricular wall (non-invasive myocardial tissue characterisation),
 - b) To become diffuse thinning of the right ventricle,
 - c) Dilatation and aneurysm of the right ventricle,
 - d) Right ventricle outflow tract > left ventricle outflow tract
 - II. Cine MRI technique
 - a) Regional or global enlargement of the right ventricle,
 - b) Systolic and diastolic dysfunction,
 - c) Regional contraction abnormalities,
 - d) Aneurysm of right ventricle,

The standard of reference for the diagnosis of ARVD is based on histological demonstration of transmural fibro fatty replacement of the right ventricular myocardium in either surgery or autopsy. Even when the biopsy specimen is obtained from the right ventricular free wall, the sensitivity is 67% and the specificity is 92% for the diagnosis of ARVD, based on the criteria of greater than 3% fat and less than 40% fibrous tissue replacing the myocardial muscle (1). Recent studies demonstrated that significant fatty infiltration of the right ventricle occurs in more than 50% of normal hearts in elderly people. The demonstration of some fat in the right ventricular myocardium may not be specific enough to help in establishing the diagnosis of ARVD (4, 9, 10). Therefore, in most cases, endomyocardial biopsy to confirm the diagnosis is not recommended, especially when the right ventricular wall is very thin and biopsy of this region risks perforation and cardiac tamponade. In our case due to high risk of the perforation and cardiac tamponade, endomyocardial biopsy was not performed.

The sensitivity and specificity of angiography in the diagnosis of ARVD is low. Echocardiography plays an important role in the evaluation of patients with suspected ARVD. However, it has many limitations in the assessment of right ventricular function, and there is still no generally recommended method to quantify the function of the right ventricle.

Kimura et al (5) reported characteristics of the helical CT in the diagnosis of the ARVD. These are the dilatation of the right ventricle, fatty tissue in conspicuous trabeculae of the right ventricle, especially in the anterior wall, apex, and inferior wall, and a scalloped appearance (bulging) of the right ventricular wall. The fatty tissue of the left ventricle

and ventricular septum is frequently seen in ARVD, and fat in ventricular septum is another useful finding for the diagnosis of ARVD. Electron-beam tomography and multislice CT are superior to non-gated helical CT in assessment of abnormal right and left ventricular functions.

MR imaging allows a three-dimensional evaluation of the heart and the ventricular anatomy and volumes, and, in views of its excellent spatial resolution and unlimited field of view, MR imaging is an excellent tool to visualize the right ventricle (1, 3, 10, 11, 13). MR imaging is useful for evaluating not only of fatty replacement of the right ventricular myocardium but also the global regional functional abnormalities of the right ventricle and right ventricular outflow tract. MR imaging provides the most important anatomic, functional, and morphological criteria for diagnosis of ARVD. Positive MR imaging findings should be used as important additional criteria in the clinical diagnosis of ARVD, although negative MR imaging findings do not rule out ARVD (1).

As a conclusion, CT is a simple and noninvasive technique that may give information about morphology and tissue character of the right ventricle. MRI can be performed simply and give much information about morphology, functional abnormalities and also tissue character of the right and the left ventricle wall.

REFERENCES

1. Kayser H, Wall E, Sivananthan M, Blooker T, Roos A. Diagnosis of arrhythmogenic right ventricular dysplasia. *Radiographics* 2002;22:639-650.
2. Linström L, Wilkenshoff M, Larsson H, Wranne B. Echocardiographic assessment of arrhythmogenic right ventricular cardiomyopathy. *Heart* 2001;86:31-38.
3. Corrado D, Basso C, Thiene G. Arrhythmogenic right ventricular cardiomyopath: diagnosis, prognosis, and treatment. *Heart* 2000;83:588-595.
4. Pasquale CG, Heddle WF. Left sided arrhythmogenic ventricular dysplasia in siblings. *Heart* 2001;86:128-130.
5. Kimura F, Sakai F, Sakomura Y, Fujimura M, Ueno E, Matsuda N, Kasanuki H, Mitsuhashi N. Helical CT features of arrhythmogenic right ventricular cardiomyopathy. *Radiographics* 2002;22:1111-1124.
6. Markus F, Towbin J, Zareba W, Moss A, Calkins H, Brown M, Gear K. Arrhythmogenic right ventricular dysplasia/cardiomyopathy. *Circulation* 2003;107:2975-2978.
7. Gilbert-Barness E. Review: Metabolic cardiomyopathy and conduction system defects in children. *Annals of clinical & laboratory science* 2004;34(1):15-34.
8. Fisher NG, Gilbert TJ. Arrhythmogenic right ventricular dysplasia. An illustrated review highlighting developments in the diagnosis and management of this potentially fatal condition. *Postgrad med j* 2000;76:395-398.
9. Basso C, Thiene G, Corrado D, Angelini A, Valente M. Arrhythmogenic right ventricular cardiomyopathy: dysplasia, dystrophy, or myocarditis? *Circulation* 1996;64:983-991.
10. Blake LM, Schheinmann MM, Higgins CB. MR features of arrhythmogenic right ventricular dysplasia. *AJR* 1994;162:809-812.
11. White RD, Trohman RG, Flamm SD, et al. Right ventricular arrhythmia in the absence of arrhythmogenic dysplasia: MR imaging of myocardial abnormalities. *Radiology* 1998;207:743-751.
12. Pantanowitz L. Fat infiltration in the heart. *Heart* 2001;85:253.
13. Diamon Y, Watanabe S, Takeda S, Hijikata Y, Komuro I. Two-layered appearance of noncompaction of the ventricular myocardium on magnetic resonance imaging. *Circulation* 2002;66:619-621.
14. Tandri H, Saranathan M, Rodriguez R, Martinez C, Bomma C, Nasir K, Rosen B, Lima J, Calkins Hugh, Bluemke D. Noninvasive detection of myocardial fibrosis in arrhythmogenic right ventricular cardiomyopathy using delayed-enhancement MRI. *Journal of the American College of Cardiology* 2005;45:98-103.