

Bilateral Ovarian Teratoma in an elderly woman - A case report.

S SMITI, NC SARMA, S MURMU

Ind J Radiol Imag 2006 16:2:205-206

Key words : Ovarian teratoma, USG, CT

A 63 year old woman came to Radiology Department for Ultrasound with a complaint of epigastric pain for 3 days and fever for 15 days.

Clinically abdomen was soft, non tender and no organomegaly was present.

Bowel sounds were normal .Ultrasound of upper abdomen was normal.

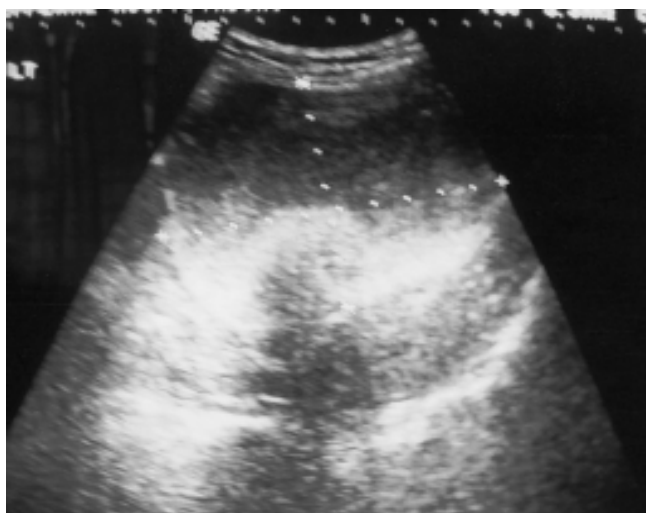

Fig 1

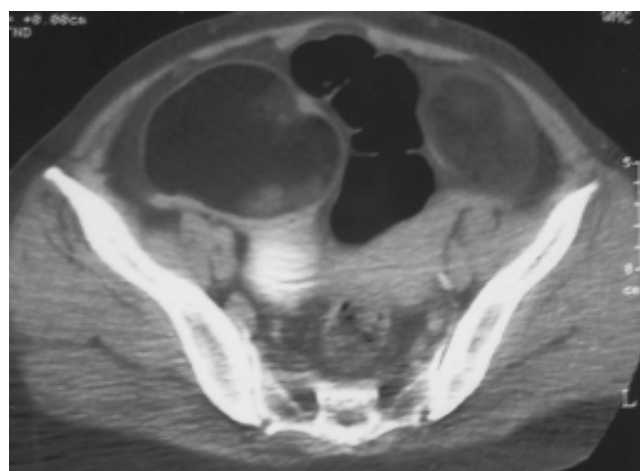


Fig 3

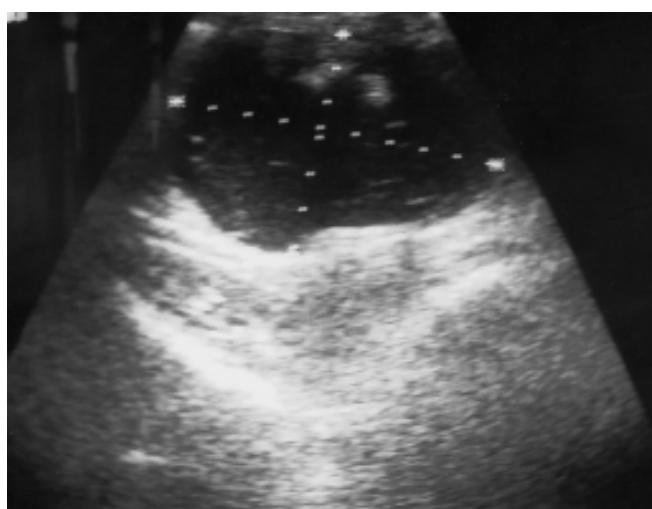

Fig 2

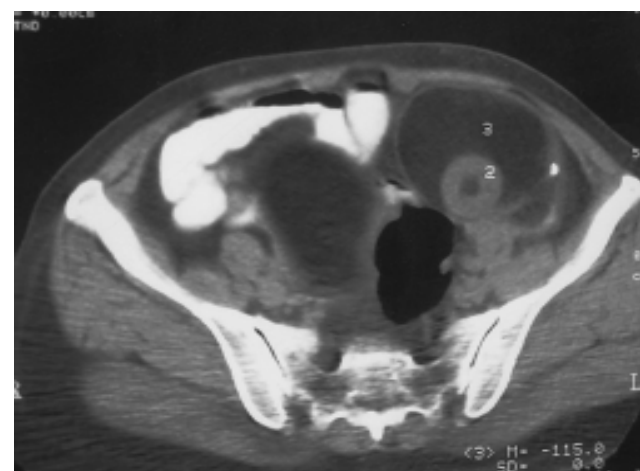


Fig 4

From the Dept.of Radio-diagnosis, Sikkim Manipal Institute of Medical Sciences & Central Referral Hospital, 5th Mile Tadong, Gangtok. Sikkim-737102

Request for Reprints: Dr. Smiti S, Asst.Professor, Dept.of Radio-diagnosis, Sikkim Manipal Institute of Medical Sciences & Central Referral Hospital, 5th Mile Tadong, Gangtok. Sikkim-737102

Received 17 August 2005; Accepted 15 April 2006

Ultrasound of lower abdomen revealed a well defined round, hypoechoic mass measuring 6.9 x 8.8 cm in size on right showing an echogenic area within. Another well defined, mixed echogenic round mass lesion with posterior acoustic shadowing was seen in left lower abdomen measuring 6.9 x 8.1 cm in size. No colour uptake was seen on Doppler study. Sonologically a diagnosis of Bilateral ovarian teratoma was made and CT scan was done to confirm the above findings. CT revealed a well defined hypodense mass lesion having fat density (CT value = -115HU) in left lower abdomen with a calcific focus within the wall. A round soft tissue density area (CT value = 21 HU) was seen within s/o Dermoid plug. The lesion extended superiorly from infra-umbilical region up to antero - superior surface of Urinary Bladder on left. Bowel loops were displaced and pushed towards right. Another hypodense mass lesion (CT value = - 112 HU) was seen on right beginning at a slightly lower level than the one on left and extended inferiorly up to antero-superior surface of Urinary Bladder on right. A soft tissue density region (CT value = 25HU) was noted within the mass. No e/o enhancement was seen on post contrast study. Based on above imaging findings a diagnosis of Bilateral ovarian teratoma was made. Total abdominal Hysterectomy with Bilateral Salpingo-oophorectomy was done and sent for histopathological examination. Gross specimen of ovarian mass showed a smooth external surface with cut surface totally filled with sebum like material and matted hairs. Microscopy showed thick capsule along with adipose tissue, giant cell reaction and spotty calcification. Hair masses were seen along with sebaceous glands s/ o mature teratoma of both ovaries.

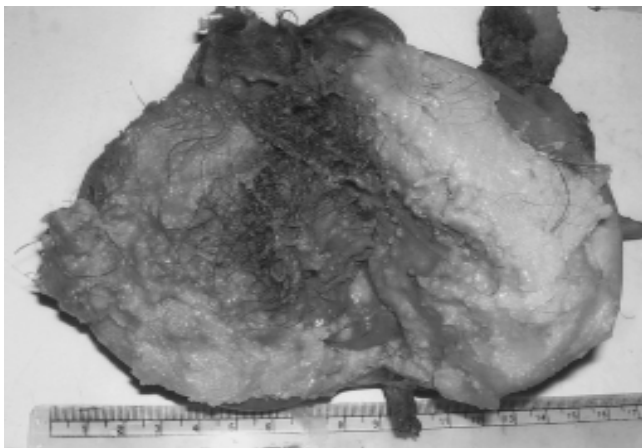


Fig 5

Uterus, cervix and tubes were unremarkable.

DISCUSSION

Cystic teratomas make up approximately 15% to 25% of ovarian neoplasms; 10% to 15% are bilateral. They are composed of well differentiated derivatives of three germ layers- ectoderm, mesoderm and endoderm(1). Mature cystic teratomas (MCTs), often referred to as dermoid cysts, are the most common germ cell tumours of the

ovary in women of reproductive age and are usually asymptomatic until they reach considerable size. Though they are common in reproductive age but they can occur at any age including post-menopausal woman. Most are 5 cms to 10cms in diameter when diagnosed and on sectioning they usually contain thick sebaceous material, tangled hair and various dermal structures (2). One of the major complications seen in cystic teratomas is torsion, a partial or complete twisting of the ovarian suspensory pedicle causing severe pain, nausea and tissue necrosis. Malignant transformation is uncommon, occurring in approximately 2% of cases usually in older women.

Sonographically cystic teratomas have a variable appearance ranging from anechoic to completely hyperechoic. Certain features are specific for cystic teratomas like predominantly cystic mass with echogenic mural nodule called Dermoid plug. The Dermoid plug contains hair, teeth or fat and frequently causes acoustic shadowing. Fat fluid level is also highly specific. Multiple linear hyperechogenic interfaces may be seen floating within cyst because of hair fibres and is called as Dermoid mesh sign. In a study done in a large cohort of women, ovarian dermoid cysts had a predisposition to a right lateral location(3).

The increased resolution capabilities provided by Transvaginal sonography allow incidental detection of previously unsuspected dermoids and permit identification of their nature(4). Dermoid cysts of ovary are devoid of blood flow with flow detection rate being only 24.3% from the cyst capsule. When apparently vascularized solid tissue is detected in central part of a sonographically suspected benign cystic teratoma, struma ovary is highly suspected (5). Endometriosis co-existing with bilateral dermoid cysts of the ovaries is a rare occurrence although both benign conditions are said to be common in women in reproductive age group (6). This association has a clinical relevance because an endometriotic pathology can reveal a silent teratoma with bilateral ovarian localization.

REFERENCES

1. Shia salem,MD-the uterus and Adnexa-In Diagnostic Ultrasound by Carol M Rumack, Stephanie R Wilson-Vol 1, 2nd Edition Eds. Robert A Hurley, Elizabeth Corra, 1998, Mosby year book pg 558.
2. Wittich AC ; Adnexal torsion presenting as an acute abdomen in a patient with bilateral cystic teratoma of the ovary. Am Osteopath Assoc. 2002 Apr; 102(4):231-3.
3. Al-Fozan H, Glassman J, Caspi B, Appelman Z, Tulandi T.Lateral distribution of ovarian dermoid cyst. J Am Assoc Gynecol Laparosc. 2003 Nov; 10(4):489-90.
4. Serafini G, Quadri PG, Gandolfo NG, Gandolfo N, Martinoli C Sonographic features of incidentally detected, small, nonpalpable ovarian dermoids. Ref J Clin Ultrasound. 1999 Sep; 27(7):369-73.
5. Zalel Y, Caspi B, Tepper R.Doppler flow characteristics of dermoid cyst: unique appearance of struma ovarii. Ultrasound Med 1997 May; 16(5):355-8.
6. Frederick J, DaCosta V, Wynter S, Tenant I, McKenzie C, McDonald Y.Endometriosis co-existing with bilateral dermoid cysts of the ovaries treated by laparoscopy. West Indian Med J. 2003 Jun; 52(2):179-81.