

Diffusion abnormality detects an acute demyelinating lesion due to probable multiple sclerosis

Rohit Bhatia, Ajay Garg*

Departments of Neurology and *Neuroradiology, All India Institute of Medical Sciences, New Delhi, India

Correspondence: Dr. Rohit Bhatia, Department of Neurology, All India Institute of Medical Sciences, New Delhi, India.
E-mail: rohitbhatia71@yahoo.com

Introduction

Multiple sclerosis (MS) is an autoimmune demyelinating disease of the central nervous system (CNS), commonly presenting as relapsing remitting neurological deficits affecting the brain, spinal cord and optic nerve, alone or in combination. Acute demyelinating lesions are generally picked up on magnetic resonance imaging (MRI) as gadolinium-enhancing lesions which may also be used to diagnose MS on follow-up imaging, especially in monophasic events or where other MRI findings do not qualify for the diagnosis. We report here the case of a young woman who presented with an acute focal neurological deficit and whose MRI showed features suggesting MS, with the acute lesion delineated on diffusion-weighted imaging but without any enhancement.

Case Report

A 28-years-old woman woke up in the morning with a feeling of numbness and weakness of the left side of her body, asymmetry of face and mild clumsiness of her left upper and lower limb. An evening before, she was observed to have been walking with an awkward gait. She had no dysarthria, aphasia, visual blurring, vertigo, deafness, headache, nausea or vomiting. There was a history of transient visual blurring in her left eye two years prior, following the birth of her child, which had improved spontaneously. There was no history of similar events in the past. She had no history of hypertension, smoking, diabetes, arthralgia, rash, photosensitivity, recurrent abortions, recurrent oral or genital ulcers, hypo or hyperthyroidism or any chronic drug intake. Family history of similar events, recurrent strokes or coronary artery disease (CAD) was absent. General physical examination and examination of chest, cardiovascular system (CVS) and abdomen was normal. Neurological examination revealed normal visual

acuity and fundus, left upper motor neuron (UMN) facial palsy, left hemiparesis, mild left hemianesthesia and subtle clumsiness in the left upper limb. She had brisk reflexes in all four limbs, especially on the left side with an upgoing plantar on the left side. Her ESR was 10 mm and her hemogram, biochemistry, vasculitis screen, lipid profile and vascular Doppler were normal. Her visual evoked response (VER) showed prolonged P100 latency in her left eye but BAER was normal.

The MRI of the brain revealed multiple hyperintense, ovoid/rounded lesions in the white matter on T2W and FLAIR images especially juxtaventricular in location, with their long axis perpendicular to the corpus callosum [Figure 1a] with no enhancement after intravenous administration of gadolinium [Figure 1b]. There was one hyperintense lesion in the left cerebellar hemisphere which showed mild enhancement. On diffusion-weighted imaging (DWI), there was a lesion in the right centrum semiovale showing restricted diffusion, appearing as a hyperintense [Figure 1c], and with a corresponding dark signal on the apparent diffusion coefficient (ADC) map [Figure 1d]. The spine MRI was normal. A possible diagnosis of acute demyelination probably due to underlying multiple sclerosis was made, based on the other imaging features and previous history of visual impairment. She was treated with steroids with significant improvement.

Discussion

MRI is an invaluable tool in the diagnosis of MS and other monophasic demyelinating disorders. Presence of new enhancing lesions is thought to be a marker for activity and also is a proposed criterion for diagnosing MS.^[1] However, MRI may miss lesions apart from the macroscopic lesions i.e., normal-appearing white matter (NAWM), and in recent years, studies have investigated the potential role of DWI and

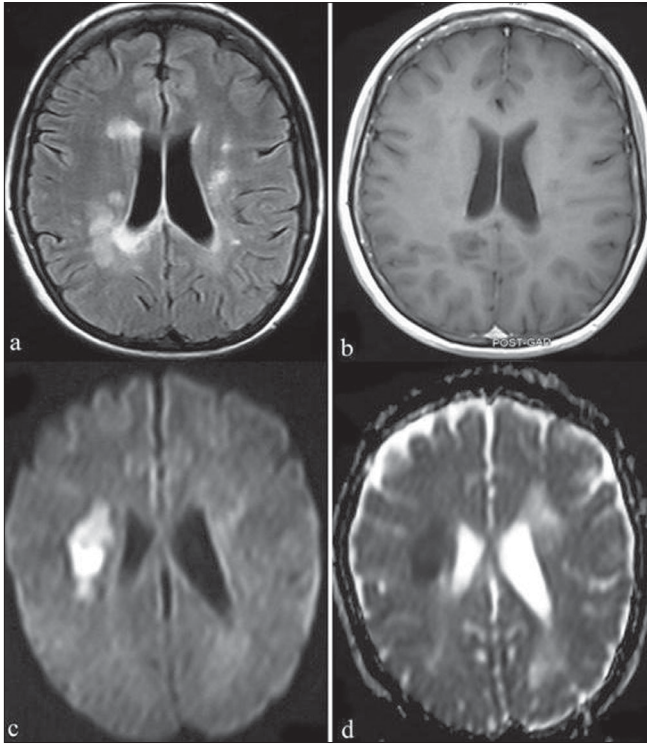


Figure 1: Multiple sclerosis. Axial FLAIR (a) image shows multiple round-ovoid juxtaventricular hyperintense lesions perpendicular to the ventricular surface. None of these lesions shows enhancement following intravenous gadolinium administration (b). Diffusion-weighted image (c) and ADC map (d) show restricted diffusion in one of the lesions in the right corona radiata, suggesting cytotoxic edema in an acute demyelinating lesion

diffusion tensor MRI in studying damaged cerebral tissue in MS.^[2] DWI, especially diffusion tensor imaging is a helpful tool in delineating lesions in areas which otherwise appear normal on routine T2W MRI. There have been, however, variable and conflicting findings when comparing ADC and mean diffusivity (MD) (average of the ADCs measured in three orthogonal directions) between enhancing and non-enhancing lesions in the acute stage.^[3] The MD values may be increased at baseline and may continue to rise on follow-up.^[4] In the other scenario, it may highlight the acute lesion manifesting as restricted diffusion and low ADC, suggesting energy failure leading to cytotoxic edema/cell swelling. This has been reported in acute disseminated encephalomyelitis (ADEM) and MS lesions,^[2,5,6] and suggests that significant neuronal injury occurs in MS. How much of the injury is transient (due to edema, demyelination, remyelination) and how much is permanent (due to axonal loss) and how all this correlates with the enhancement pattern, requires large follow-up studies.^[2]

Caution is advised, as similar changes are consistently described in other acute lesions, such as stroke.

Therefore history, examination, investigations and other corroborative MRI features and laboratory data are of utmost importance in diagnosing a demyelinating disease. However, the abnormalities in NAWM are seen more often in MS as compared to ADEM.^[5] Although the role of DWI and DT MRI has not still been fully established as a diagnostic method, it probably is a strong tool in delineating pathology both within and outside the abnormal lesions visible on T2W images.^[2] Their role in the brain is likely to be more important than in the spine and optic nerves, mainly related to technical difficulties in the latter areas, although studies in the optic nerve as well quantification in spinal cord pathology, are available in the literature.^[7,8]

Our case illustrates that diffusion abnormality may detect an acute lesion in MS and this abnormality may be looked for in patients with suspected acute demyelinating events. The tissue damage evidenced by imaging in the present case was probably reversible, as evidenced by the significant clinical improvement in our case.

References

1. McDonald WI, Compston A, Edan G, Goodkin D, Hartung HP, Lublin FD, et al. Recommended diagnostic criteria for multiple sclerosis: Guidelines from the International Panel on the diagnosis of multiple sclerosis. *Ann Neurol* 2001;50:121-7.
2. Rovaris M, Gass A, Bammer R, Hickman SJ, Ciccarelli O, Miller DH, et al. Diffusion MRI in multiple sclerosis. *Neurology* 2005;65:1526-32.
3. Fillipi M, Iannucci G, Cercignani M, Assunta Rocca M, Pratesi A, Comi G. A quantitative study of water diffusion in multiple sclerosis lesions and normal appearing white matter using echoplanar imaging. *Arch Neurol* 2000;57:1017-21.
4. Castriota-Scanderbeg A, Sabatini U, Fasano F, Floris R, Fraracci L, Mario MD, et al. Diffusion of water in large demyelinating lesions: A follow up study. *Neuroradiology* 2002;44:764-7.
5. Inglese M, Salvi F, Iannucci G, Mancardi GL, Mascalchi M, Filippi M. Magnetization transfer and diffusion tensor imaging of acute disseminated encephalomyelitis. *AJNR Am J Neuroradiol* 2002;23:267-72.
6. Tievsky AL, Ptak T, Farkas J. Investigation of apparent diffusion coefficient and diffusion tensor anisotropy in acute and chronic multiple sclerosis lesions. *AJNR Am J Neuroradiol* 1999;20:1491-9.
7. Hickman SJ, Wheeler-Kingshott CA, Jones SJ, Miszkil KA, Barker GJ, Plant GT, et al. Optic nerve diffusion measurement from diffusion weighted imaging in optic neuritis. *AJNR Am J Neuroradiol* 2005;26:951-6.
8. Clark CA, Werring DJ, Miller DH. Diffusion imaging of the spinal cord in vivo: Estimation of the principal diffusivities and application to multiple sclerosis. *Magn Reson Med* 2000;43:133-8.

Source of Support: Nil, **Conflict of Interest:** None declared.