

# Cardiac CT: A personal clinical perspective

Rajesh Thachathodiyl

Department of Cardiology, Amrita Institute of Medical Sciences, Kochi, Kerala State, India

**Correspondence:** Dr. Rajesh Thachathodiyl, Department of Cardiology, Amrita Institute of Medical Sciences, Kochi, Kerala State, India.  
E-mail: drtrajesh@aims.amrita.edu

## Introduction

The advent of 64-slice cardiac CT scanner in the latter half of 2005, has made a difference to the practice of cardiology in our Institute. I have made an attempt to put together the experiences accumulated over the last two years, from the perspective of an adult interventional cardiologist.

There is a trend among invasive cardiologists to make conventional coronary angiograms more safe and patient friendly. Also there have been major advancements in cathlab imaging technology and refinements in the technique of arterial access.

The quality of imaging and also the ability to have a three dimensional perspective of the coronary vasculature has been made feasible with the advent of the digital flat panel technology. The quantity of contrast load and radiation dose required have considerably reduced with the use of rotational X-ray angiography (spin technology).

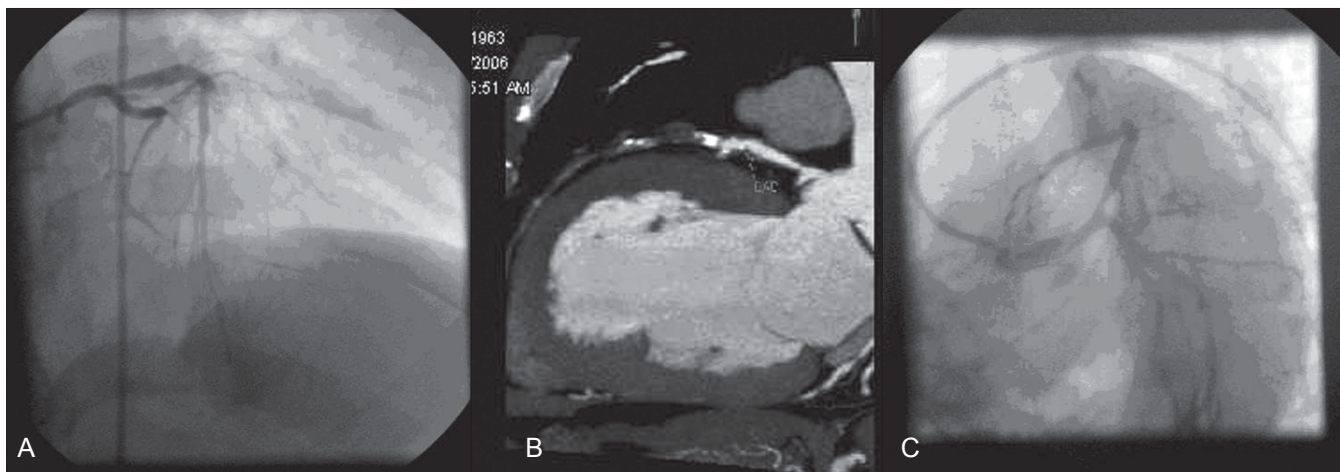
Coronary angiography can be performed via the femoral arterial or radial arterial routes.<sup>[1]</sup> Radial angiograms are more comfortable for the patients, because they can walk out of the angiography lab immediately after the procedure.

In this background has emerged the multi-slice CT (MSCT) scanner. Not only is a CT angiogram far simpler and less noninvasive but also has the ability to partly characterize an atherosclerotic plaque, which is not possible on a conventional angiogram.<sup>[2]</sup>

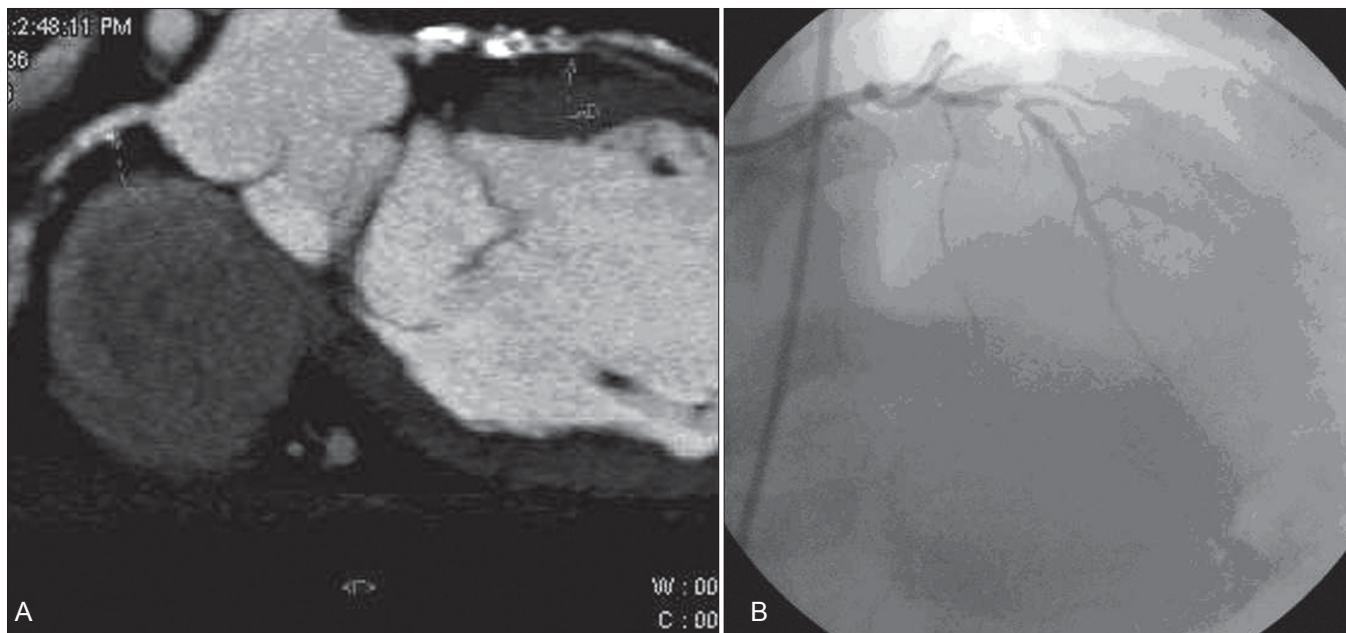
Ours is a 1000 bedded tertiary care facility with a high profile team of invasive cardiologists. We acquired a 64 slice CT scanner in October 2005. Coronary imaging is performed by a team of radiologists, technologists and a single cardiologist. Our referrals have been from within the hospital and also from the community. Well-informed, asymptomatic patients have also referred themselves for CT angiography.

Wherever it is possible, if there are no contradictions, we encourage patients to be on beta-blockers, the day prior to imaging. If they are not optimally beta-blocked, then on the day of the scan, supplemental oral and if required, intravenous metoprolol are additionally given. As a policy, we refuse to perform CT angiograms in patients with high calcium scores and we have arbitrarily fixed a cut-off calcium score of 400 for this.

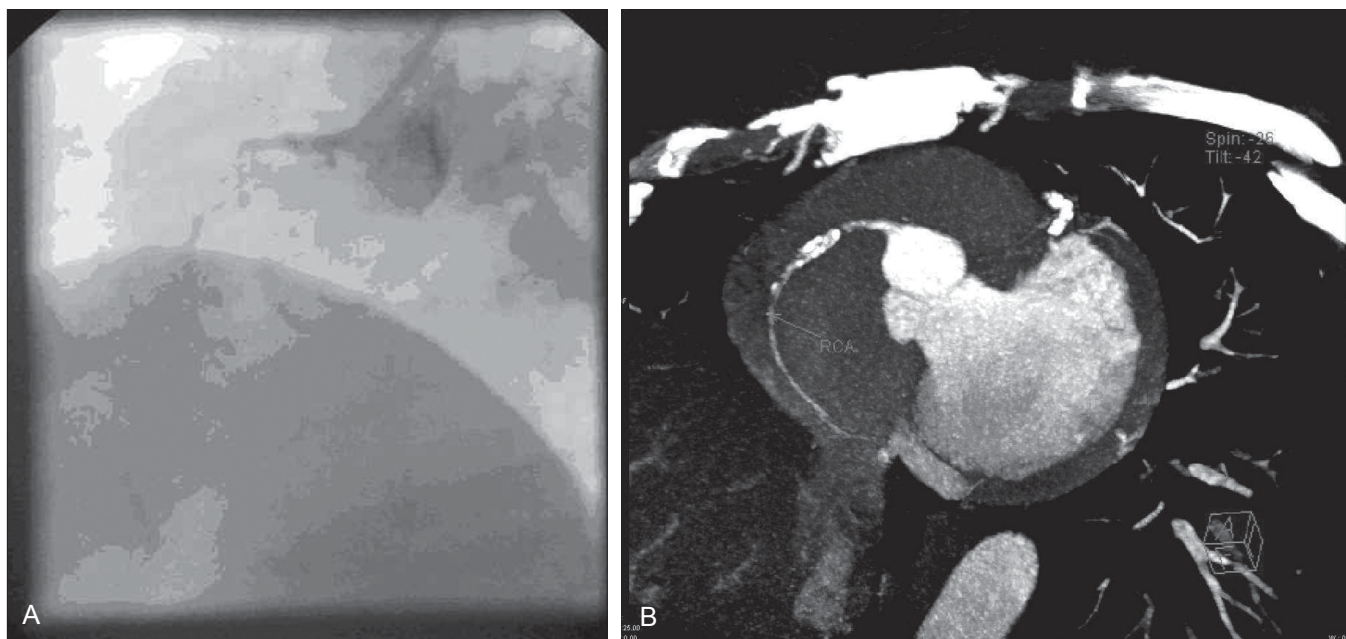
We have performed CT scans in 879 patients from Oct 2005



**Figure 1 (A-C):** Chronic total mid-LAD occlusion. Catheter angiogram (A) shows the occlusion (arrow), which could not be crossed with a stiff wire. Note the dense calcification (arrow) on the CT angiogram (B), at the origin of the occlusion - the anatomy is suitable for PTCA, which was successfully performed (C).



**Figure 2 (A, B):** Dense calcification. The CT angiogram (A) shows a severe mid-RCA stenosis (arrow) with dense LAD calcification (arrowhead), which masks an underlying severe stenosis (arrow), seen well in the conventional angiogram (B)



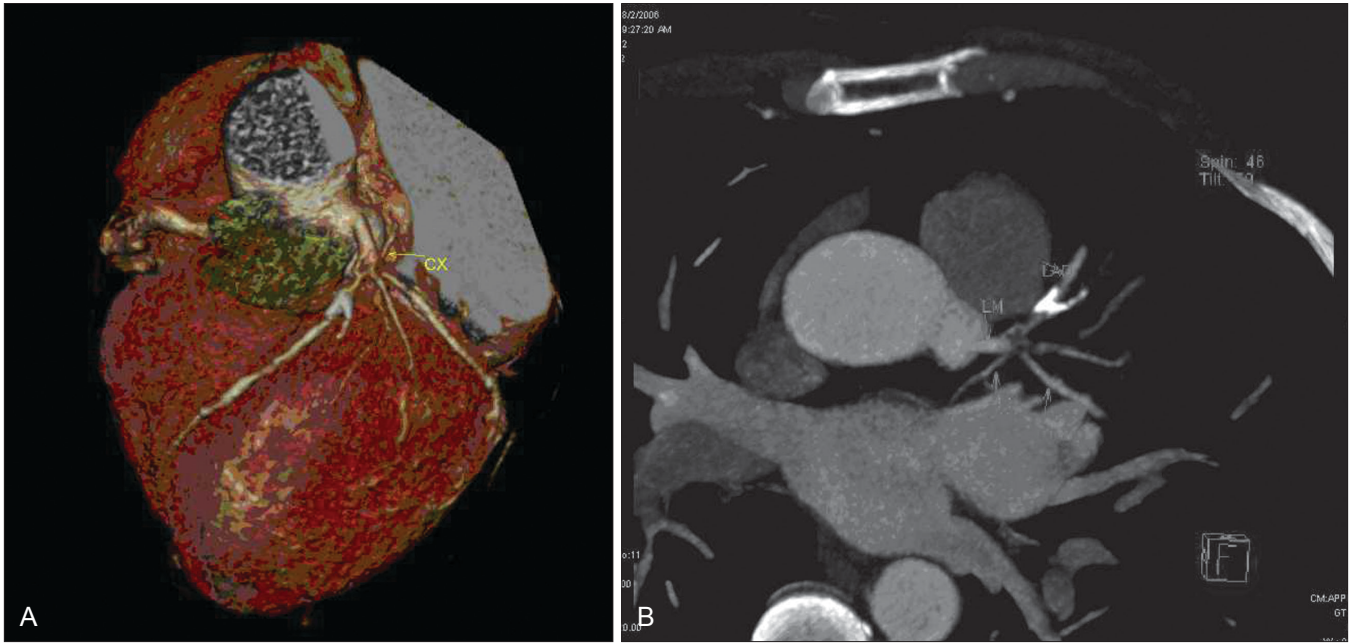
**Figure 3 (A-B):** RCA occlusion. Catheter angiogram (A) shows a mid-RCA occlusion (arrow). Its length however cannot be gauged on the angiogram. The CT angiogram (B) however, shows the length of the lesion and the presence and extent of calcification with ease (arrows)

to Feb 2007 [Table 1]. 48 patients had unacceptably high calcium scores above 400 and further study was discontinued. 362 patients had normal coronaries. Patients with mild and significant stenosis added up to 308 patients. We had a large number of poststent (70) and post-bypass (91) patients.

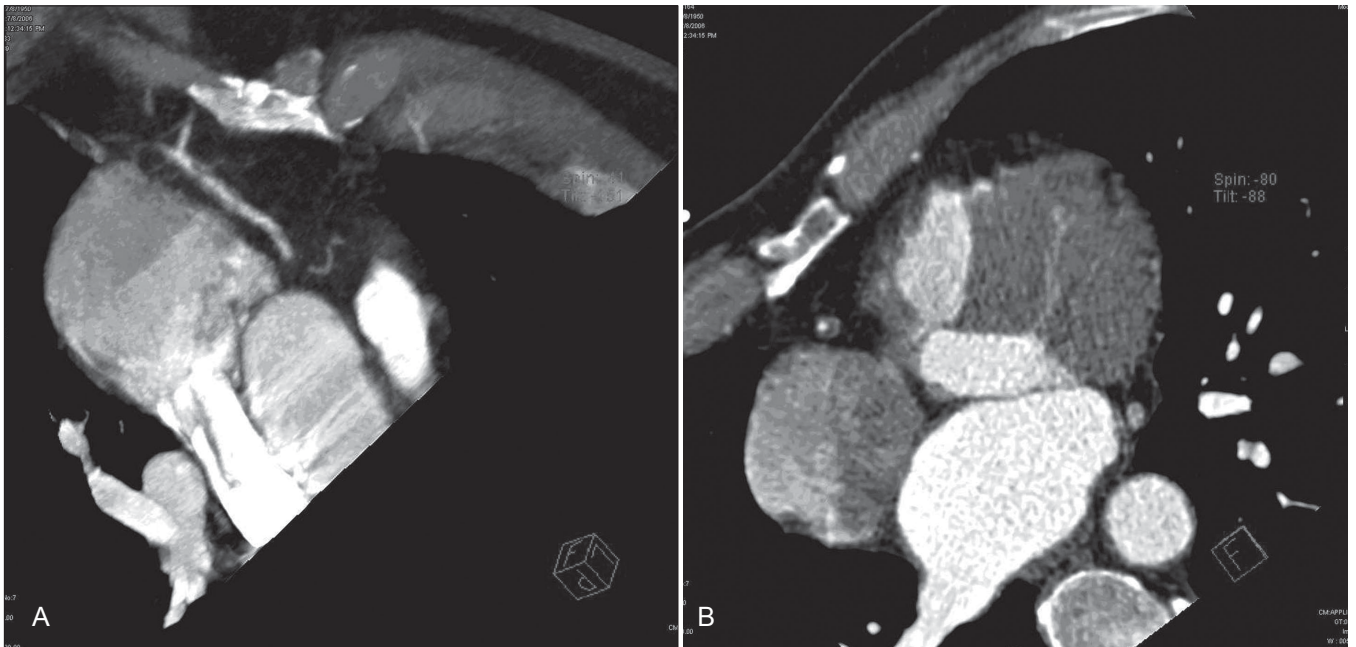
The risk factor profile and the symptom status at

**Table 1: CT scan profile**

	No. of patients
Normal study	362
Positive study	308
S/p PTCA	70
S/p CABG	91
High Ca score	48



**Figure 4 (A-B):** Distal LM stenosis. The CT angiogram shows the severe distal LM stenosis (arrows) well on the VRT (A) and MIP (B) images



**Figure 5 (A-B):** Thrombus. MIP image (A) shows a mid-RCA lesion (arrow), which on the raw-data axial image (B) is seen to be a large filling defect, in a patient who presented with an ACS

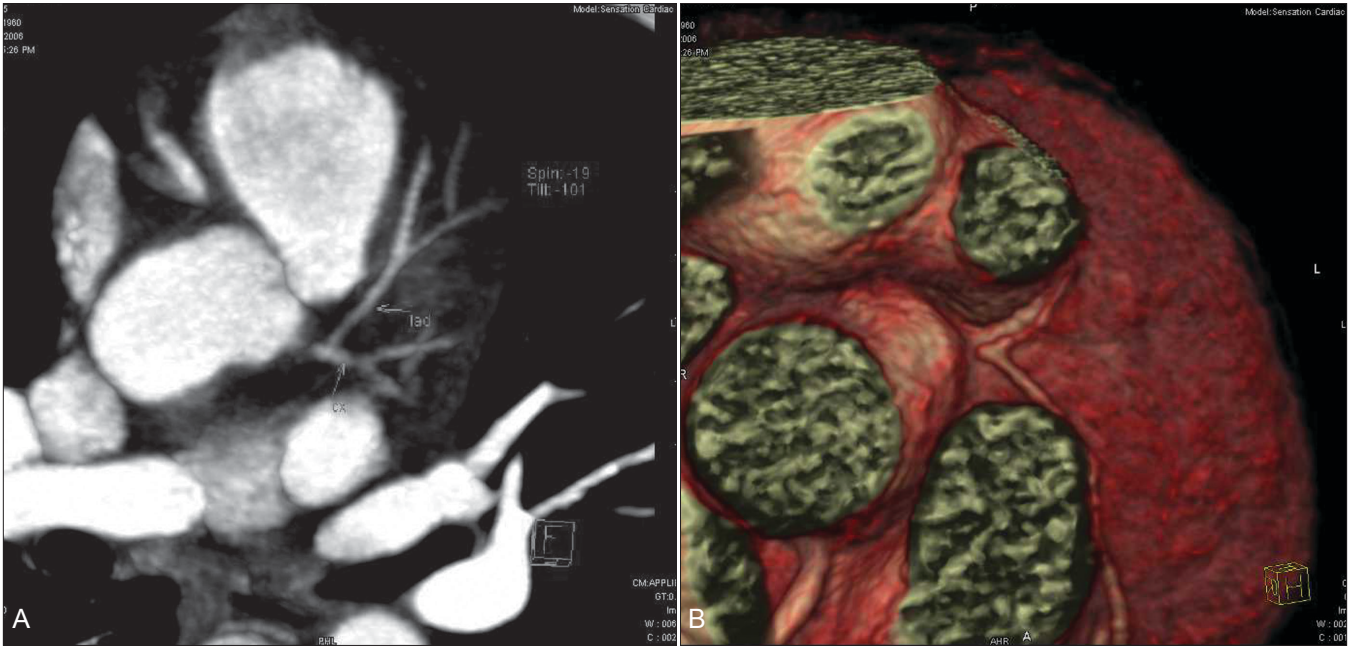
presentation of a sub-group (375 patients) are as mentioned below [Tables 2-3].

**Table 2: Risk factor profile**

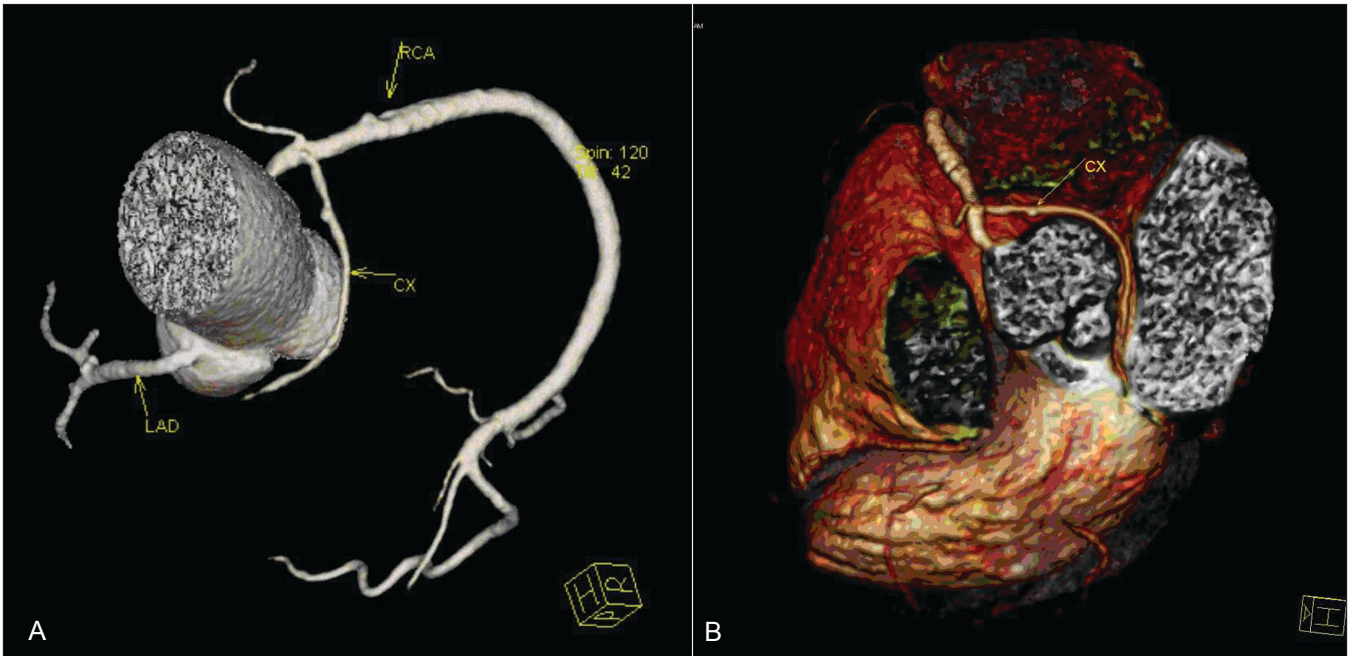
	No. of patients
Diabetes mellitus	132
Hypertension	206
Hyperlipidemia	213
Smoking	109
Family h/o coronary artery disease	121

In our experience, CT angiogram-based direct PTCA is eminently feasible with a high success rate [Figure 1]. Left main ostial lesions, additional lesions and distal small vessels may be missed and need to be looked for carefully and with greater attention to detail. In addition, dense calcification can mask critical underlying stenosis [Figure 2].

Apart from its greater sensitivity in picking up calcium, the length of total occlusion and the presence of thrombus can



**Figure 6 (A-B):** Severe LM ostial narrowing. This patient had a catheter angiogram elsewhere which showed a suspicious LM ostial lesion. A repeat angiogram was not performed and the lesion (arrow) was assessed with CT angiogram using VRT (A) and MIP (B) images



**Figure 7 (A-B):** Anomalous coronary artery origin. The circumflex (arrow) arises from the RCA (arrowhead) on these MIP (A) and VRT (B) images

be ascertained from the scan pictures. PTCA strategies can be planned in advance and the guiding catheter, guide wire and the balloon and stent can be selected based on the CT angiogram [Figure 3].

A single patient in our series also had a bypass based on CT angiogram alone [Figure 4]. He had a critical distal left main stenosis and the pictures were of good quality, which

emboldened us to request our surgeon to take him up for a bypass surgery. In our institute, the cardiothoracic surgeons are reasonably comfortable with the CT angiogram reports

Patients with unstable angina, non-ST elevated myocardial infarction (NSTEMI) and ST elevation myocardial infarction are grouped under the subset of acute coronary syndrome

**Table 3: Symptom status**

	No. of patients
Asymptomatic (Asymp)	107
Chronic stable angina (CSA)	54
Unstable angina (USA)	34
Recent STEMI (Re STEMI)	9
Old STEMI (Old STEMI)	17
Asymptomatic post MI (Asym PMI)	1
H/o Myocarditis (h/o Myc)	4
Atypical chest Pain (At CP)	71
Anginal equivalent (DOE)	50
Co Morbidity (COM)	1
Pre op Cardiac evaluation (Pre Op)	2

(ACS). Spontaneous rupture of a previously stable plaque due to unknown reasons compromises myocardial flow further and produces the constellation of what is called ACS.<sup>[3]</sup> CT angiogram may show the ruptured or ulcerated plaque along with a large thrombus load [Figure 5].

In patients with left main (LM) ostial lesions, in whom conventional angiography may not be possible, CT angiograms can be very useful [Figure 6].

CT angiograms are also very useful for diagnosing aberrant coronary arteries and anomalous coronary origin. A circumflex artery arising from the RCA may be missed

on conventional angiograms, but will be well seen on CT [Figure 7].

We were fortunate enough to have 48 patients in our series, who had conventional angiograms done after CT angiogram. CT angiogram accurately predicted the target lesion in 40 out of 48 patients. Eight patients had additional lesions, which were missed on cardiac CT. One patient had dense calcification in the proximal LAD, which prevented lesion visualization. Another patient had a left main ostial lesion, which was missed. The third patient had step artifacts in the proximal RCA and significant stenosis was missed. Five patients had lesions in small caliber distal vasculature, which were not picked up.

## References

1. Kiemeneij F, Laarman GJ, de Melker E. Transradial artery coronary angioplasty. *Am Heart J* 1995;129:1-7.
2. Leschka S, Alkadhi H, Plass A, Desbiolles L, Grunenfelder J, Marincek B, *et al.* Accuracy of MSCT coronary angiography with 64-slice technology: First experience. *Eur Heart J* 2005;26:1482-7.
3. Early effects of tissue-type plasminogen activator added to conventional therapy on the culprit coronary lesion in patients presenting with ischemic cardiac pain at rest. Results of the Thrombolysis in Myocardial Ischemia (TIMI IIIA) Trial. *Circulation* 1993;87:38-52.

## Advertisement

**BEST COMPLIMENTS**  
from  
**GE HEALTHCARE**