

Right coronary artery aneurysm

Narayan Vinchurkar, Manoj Chopda

Dept of Radiology, Vinchurkar Diagnostic Center, Nasik, Maharashtra, India

Correspondence: Dr. Narayan Vinchurkar, Vinchurkar Diagnostic Centre, Nasik, Maharashtra. E-mail: vinchurkar@yahoo.com

Introduction

Coronary artery aneurysm is an uncommon finding and usually detected incidentally during angiographies. We present a case of a coronary artery aneurysm evaluated with CT angiography (CTA) and catheter angiography.

Case Report

A 30-year-old man was admitted with an infero-posterior wall myocardial infarction and was thrombolysed. An echocardiogram showed an akinetic infero-posterior wall with mild left ventricular dysfunction and an ejection fraction of 42%. There was a 5.5 x 5.5 cm mass along the right atrial border.

An multidetector computed tomography (MDCT) angiogram was then performed using a 64-slice scanner (Somatom 64, Siemens AG Germany) with retrospective ECG gating, using a standard protocol. The proximal right coronary artery (RCA) showed good opacification and was seen entering an irregular, oval sac, 5.0 x 2.5 cm in ovoid dimensions, along the anterior-superior aspect of the right atrium with no distal continuity [Figure 1A]. No distal vessels were identified. An oval iso- to hypodense

nonenhancing thrombus was seen in the region of the right atrium bulging along the right heart border [Figure 1B]. The right atrial lumen was significantly effaced. The rest of the vessels were normal. These findings were suggestive of a large, partly thrombosed aneurysm of the RCA.

On the catheter angiogram, the RCA showed a proximal, enlarged stump with tapering [Figure 2].

The patient underwent open-heart surgery. A partly-thrombotic RCA aneurysm involving the proximal and mid-RCA was noted and was ligated. The distal RCA was grafted and the patient has been asymptomatic for the last one year.

Discussion

Morgagni first described a coronary artery aneurysm pathologically in 1761. A coronary artery aneurysm is defined as a dilated segment with a diameter greater than 1.5 times the normal adjacent artery segment and can be classified as fusiform or saccular.^[1]

Other causes include Kawasaki's disease, diagnostic or interventional coronary angiographies, inflammatory

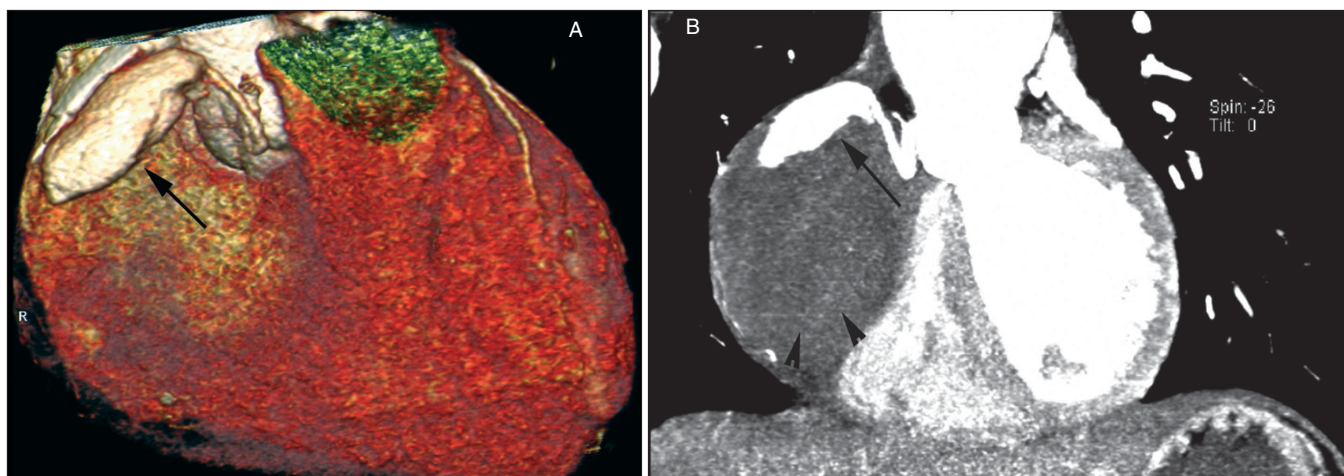


Figure 1: Volume rendered (A) and MIP (B) images, reveals a large fusiform proximal RCA aneurysm seen along the right heart border (arrow) with an extremely large peripheral thrombus (arrowheads)

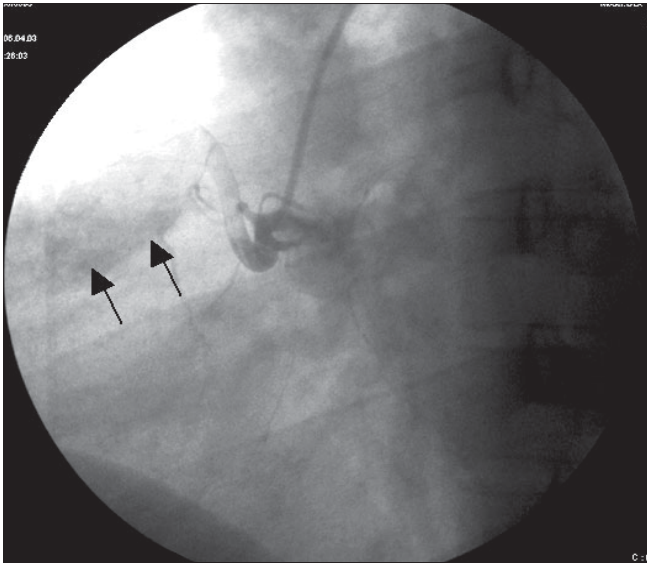


Figure 2: Catheter angiogram shows faint filling of the RCA aneurysmal sac with no distal opacification (arrows)

and infectious arteritis, connective tissue disease, aortic dissection, tumor metastases, trauma and congenital malformation.^[1]

The largest autopsy series, by Daoud *et al.*,^[2] showed a 1.4% incidence of coronary artery aneurysms in 694 patients. In the coronary artery surgery study (CASS) registry, the angiographic incidence of this abnormality was 4.9% in a group of 20,087 patients.^[3] In a prospective study of nearly 5,000 cardiac catheterizations, Hartnell *et al.*^[4] found coronary artery dilatation in 70 patients (1.4%). Fifty-eight of the 70 patients (83%) had significant coronary obstruction.

The right coronary artery is the most frequently involved artery, followed by the left anterior descending artery.^[1] Involvement of the left main is still rare. Patients with

coronary artery aneurysm can either be asymptomatic or symptomatic. The symptomatic group usually presents with ischemia or heart failure symptoms.^[4]

In a large study of 924 patients,^[4] 24 patients (2.6%) who had an infarct-related artery (IRA) with aneurysmal dilatation were retrospectively registered and constituted the patient population of this study. Angiographic findings demonstrated that the ectasia type (defined as diffuse dilatation of 50% or more of the length of the IRA) was found most frequently (70%), followed by the fusiform type (20%; defined as a spindle-shaped dilatation in the IRA) and the saccular type (10%; defined as a localized spherical-shaped dilatation in the IRA). The right coronary artery was the most frequently involved vessel (54.2%), followed by the left anterior descending (25.0%) and the left circumflex arteries (20.8%). Coronary angiography revealed that all of these aneurysmal IRAs filled with heavy thrombus (indicated as high-burden thrombus formation). The no-reflow phenomenon (defined as \leq TIMI-2 flow) and distal embolization after p-PCI were found in 62.5 and 70.8% of the IRA, respectively. The incidence of cardiogenic shock and the 30-day mortality rate were 25 and 8.3%, respectively. The survival rate was 90.9% (20/22) during a mean follow-up of 19 ± 30 months.^[4]

A giant coronary pseudoaneurysm of uncertain cause, arising from Vieussens' arterial ring^[5] and a giant coronary aneurysm arising from the sinus node artery^[6] have also reported. A large ruptured or thrombosed aneurysm generally presents as an intracardiac mass^[7] as seen in this case.

The long-term prognosis and optimal management of these patients is not certain. The altered blood flow in aneurysmal segments is thought to predispose to thrombosis or embolism and subsequent ischemia or infarction.^[8]

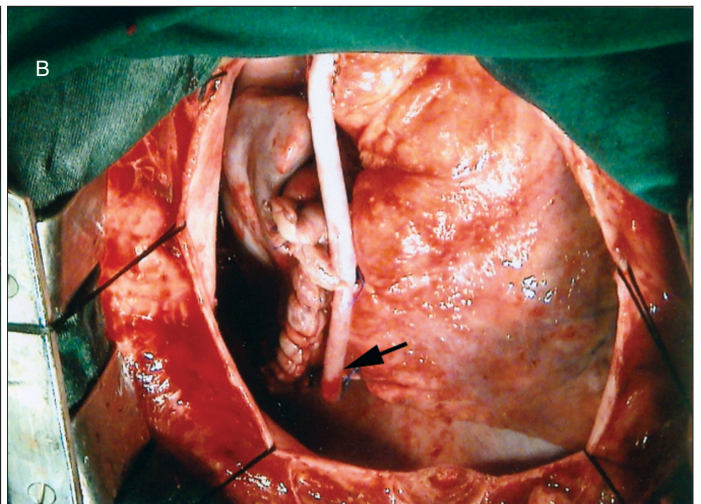
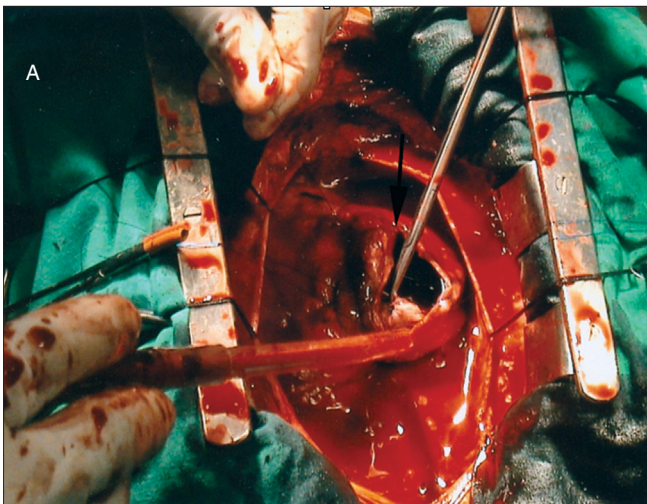


Figure 3: Surgical image (A) shows the aneurysmal sac dissected and open (arrow) with a postligated image (B) showing a graft to the distal RCA.

Because of the relatively uncommon nature of these aneurysms, management of these patients has been based on anecdotal reports and experience and has included anti-platelet and anti-coagulant medications. Nevertheless, it is generally agreed that coronary artery bypass surgery should be performed in patients who have aneurysmal disease concomitant with significant coronary stenosis.^[1] The indication for surgery on coronary artery aneurysms depends on the size and the risk of rupture, the presence of concomitant obstructive coronary artery disease and the presence and size of a fistula to one of the cardiac chambers.^[7]

Coronary artery aneurysm is an uncommon lesion that is sometimes associated with obstructive coronary artery disease or sudden death. MDCT appears to be an easy and reliable technique to confirm the diagnosis and plan treatment

References

1. Atherosclerotic coronary artery aneurysms: Eight-year angiographic follow-up. LaMotte LC, Mathur VS.
2. Daoud AS, Pankin D, Tulgan H, Florentin RA. Aneurysms of the coronary artery: Report of ten cases and review of literature. *Am J Cardiol* 1963;11:228-37.
3. Robertson T, Fisher L. Prognostic significance of coronary artery aneurysm and ectasia in the coronary artery surgery study (CASS) registry. In: Shulman ST, editor. *Kawaski disease. Proceedings of the second international symposium*. A.R. Liss: New York; 1987. p. 325-39.
4. Murthy PA, Mohammed TL, Read K, Gilkeson RC, White CS. MDCT of coronary artery aneurysms. *AJR Am J Roentgenol* 2005;184:S19-20.
5. Kocica MJ, Vranes MR, Djukic PL, Mikic ADj, Velinovic MM, Havelka M, et al. Giant pseudoaneurysm from vieussens' arterial ring. *Ann Thorac Surg* 2004;78:1833-6.
6. Kanemitsu N, Nakamura T, Okabe M, Tenpaku H, Wariishi S, Ohki A. Giant coronary artery aneurysm arising from sinus node artery. *Ann Thorac Surg* 2001;72:1373-4.
7. Hirsch GM, Casey PJ, Raza-Ahmad A, Miller RM, Hirsch KJ. Thrombosed giant coronary artery aneurysm presenting as an intracardiac mass. *Ann Thorac Surg* 2000;69:611-3.
8. Swaye PS, Fisher LD, Litwin P, Vignola PA, Judkins MP, Kemp HG, et al. Aneurysmal coronary artery disease. *Circulation* 1983;67:134-8.

Source of Support: Nil, **Conflict of Interest:** None declared.

Author Help: Reference checking facility

The manuscript system (www.journalonweb.com) allows the authors to check and verify the accuracy and style of references. The tool checks the references with PubMed as per a predefined style. Authors are encouraged to use this facility before submitting articles to the journal.

- The style as well as bibliographic elements should be 100% accurate to get the references verified from the system. A single spelling error or addition of issue number / month of publication will lead to error to verifying the reference.
- Example of a correct style
Sheahan P, O'leary G, Lee G, Fitzgibbon J. Cystic cervical metastases: Incidence and diagnosis using fine needle aspiration biopsy. *Otolaryngol Head Neck Surg* 2002;127:294-8.
- Only the references from journals indexed in PubMed would be checked.
- Enter each reference in new line, without a serial number.
- Add up to a maximum 15 reference at time.
- If the reference is correct for its bibliographic elements and punctuations, it will be shown as CORRECT and a link to the correct article in PubMed will be given.
- If any of the bibliographic elements are missing, incorrect or extra (such as issue number), it will be shown as INCORRECT and link to possible articles in PubMed will be given.