

# Chest

Kumar Jyoti, Kumar Atin

Department of Radiology, All India Institute of Medical Sciences, New Delhi, India

**Correspondence:** Dr. Atin Kumar, 175, Minakshi Garden, P.O. Tilak Nagar, New Delhi - 110 018, India.  
E-mail: dratinkumar@gmail.com

An 18-years old man presented with cough and expectoration with fever for three months. His medical history included asthma and Type II diabetes mellitus. He was a nonsmoker. Imaging of the chest was undertaken, initially with plain

radiographs [Figure 1] and subsequently with computed tomography [Figures 2 and 3].

**What is the diagnosis?**

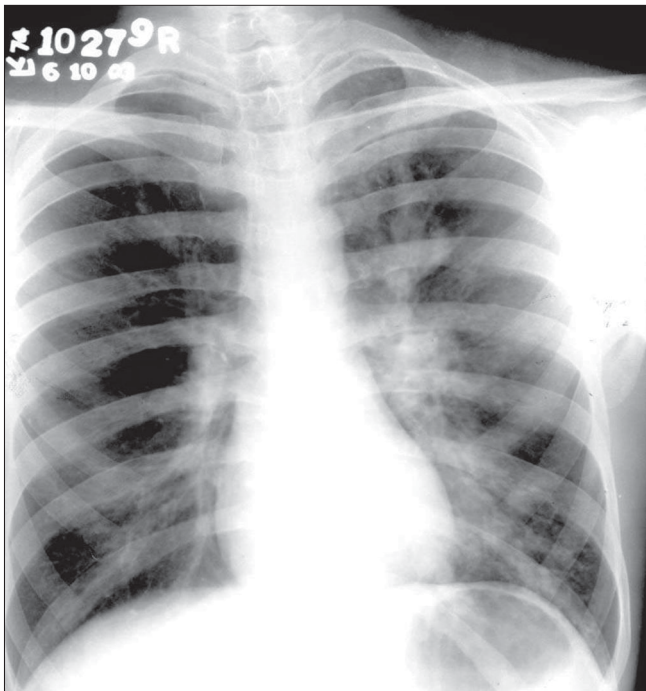


Figure 1: Chest radiograph – PA view

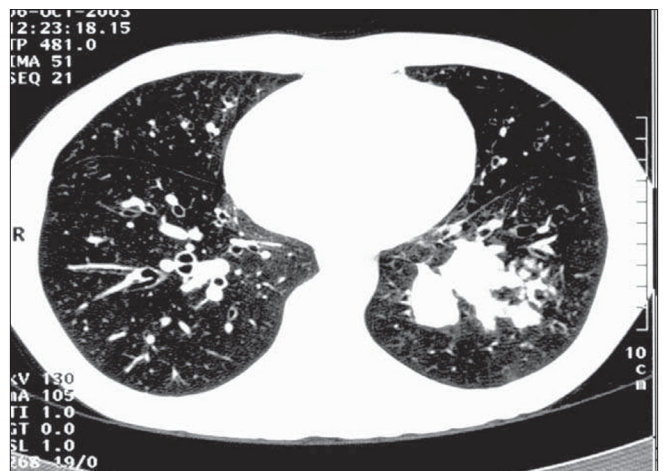


Figure 3: CT chest – lung windows

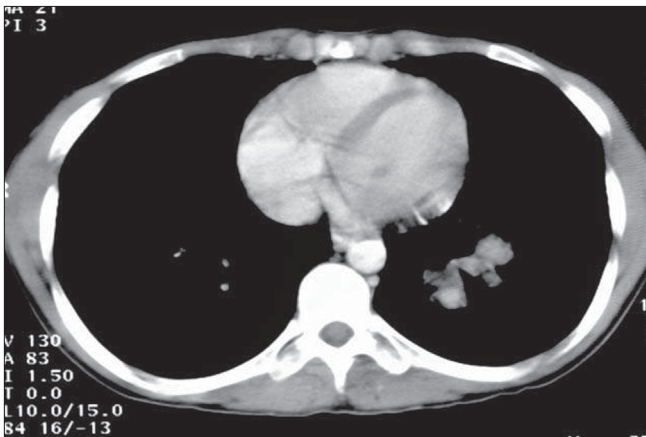


Figure 2: CT chest – mediastinal windows