Article published online: 2021-07-31

Case report: Right vocal cord paralysis detected by PET/CT in a case of esophageal cancer

NC Purandare, V Rangarajan, Sneha Shah
Bio-Imaging Unit, Tata Memorial Hospital, Dr Ernest Borges Road, Parel, Mumbai - 400 012, Maharashatra, India

Correspondence: Dr. Nilendu Purandare, Bio-Imaging Unit, Tata Memorial Hospital, Dr Ernest Borges Road, Parel, Mumbai - 400 012, Maharashtra, India. E-mail- nilpurandare@hotmail.com

Key words: Esophageal cancer, FDG PET–CT, hypermetabolism, recurrent laryngeal nerve, vocal cord

Case Report

A 50-years-old woman with a biopsy-proven mid-third esophageal cancer was referred for a PET–CT study as part of her diagnostic work-up. The study revealed increased flurodeoxyglucose (FDG) uptake in the primary mass in the mid-third of the esophagus [Figure 1]. Focal FDG uptake was seen at the root of the neck on the right side and also in the lower anterior neck in the midline [Figure 1].

On fusion PET–CT images, the uptake at the root of the neck was localized to an enlarged right, level IV lymph node, whereas the uptake in the lower anterior neck was localized to the left vocal cord [Figures 2 and 3]. On the basis of the FDG PET–CT findings, a diagnosis of metastatic right-sided cervical adenopathy from a primary esophageal cancer, with paralysis of the right vocal cord was made.

Biopsy of the neck node was performed, which confirmed metastatic nodal involvement. Laryngoscopic examination revealed right vocal cord paralysis. The right vocal cord was paralyzed due to nodal involvement of the right recurrent laryngeal nerve. The patient was offered palliative chemotherapy, which is the current standard of care for metastatic esophageal cancers.

Discussion

FDG accumulates in benign and malignant conditions with increased glucose consumption. The amount of glucose taken up is directly proportional to the degree of muscle work.[1]

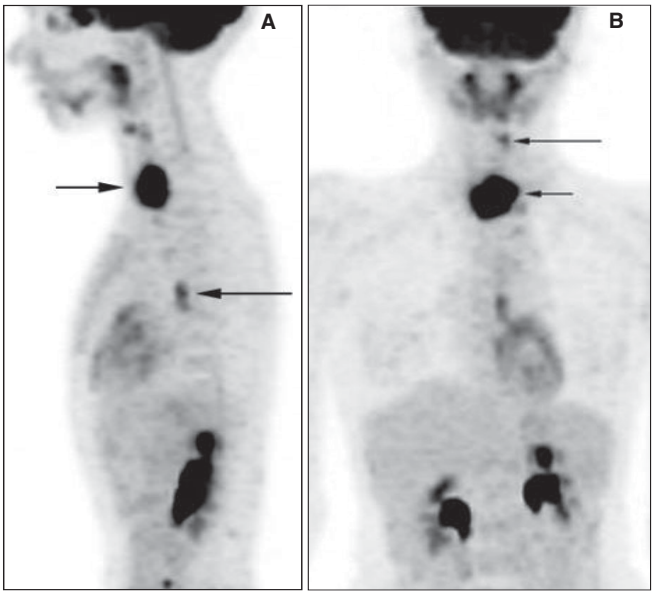

Figure 1 (A, B): Sagittal MIP (A) and coronal MIP (B) images show increased uptake in the primary mid-third esophageal mass (long black arrow in A), in the neck node (short black arrow in A and B), and in the region of the larynx (long black arrow in B).

The asymmetric FDG uptake seen in vocal cord paralysis is believed to be due to the lack of FDG activity in the paralyzed cord and compensatory activation of the contralateral (nonparalyzed) vocal cord. This increased workload of the nonparalyzed cord leads to increased glucose consumption (hypermetabolism) which is seen as a focal hot spot on FDG PET images.

Usually, while performing FDG PET or PET–CT scans,

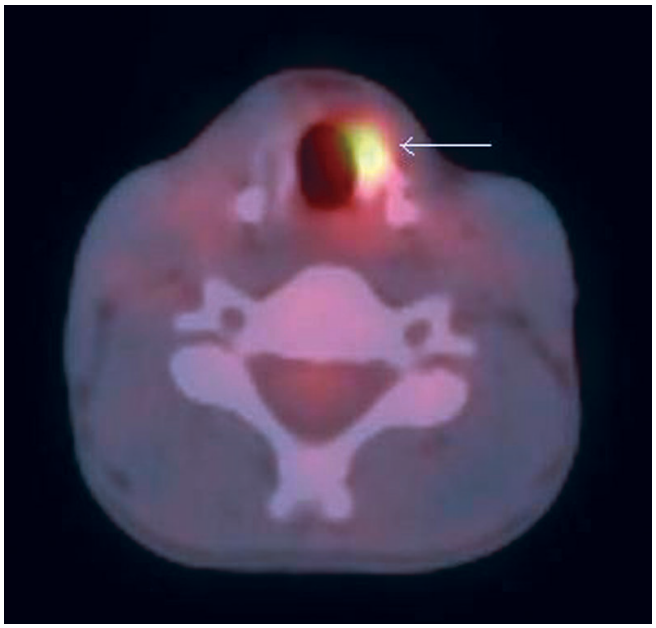

Figure 2: Coregistered transverse PET–CT fusion image of the neck shows increased FDG uptake (white arrow) in the left intrinsic laryngeal muscles (vocal cord).

Figure 3: Coregistered sagittal PET–CT fusion image shows increased uptake in the primary esophageal mass (long white arrow) and the neck node (short white arrow).

the patient is advised to rest, without any movement, and to refrain from talking during the uptake period of FDG (i.e., for about 30 min after administration of FDG). There can be normal glucose uptake in the tongue, pharyngeal musculature, and the larynx if the patient talks, coughs,

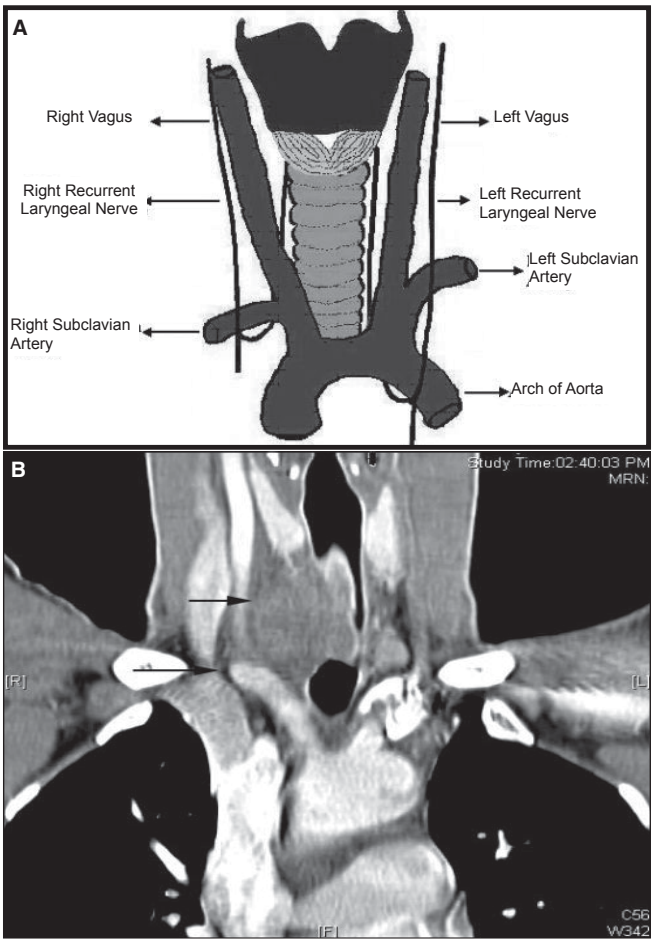

Figure 4 (A, B): Line diagram (A) showing the course of the recurrent laryngeal nerves. Coronal, reformatted, contrast-enhanced CT scan showing the right-sided neck node along the course of the right recurrent laryngeal nerve (short black arrow) and the right subclavian artery (long black arrow).

or chews after injection of the isotope.[2] This uptake can be mild, moderate, or intense in nature and is generally symmetric.

Asymmetric increased FDG uptake should always raise the suspicion of a primary neoplastic or inflammatory cord pathology. FDG PET has been found to be useful in identifying primary and recurrent laryngeal cancer.[3,4] Alternatively, asymmetric increased uptake can be caused by impaired movement or paralysis of the contralateral vocal cord.[5–9] When there is incidental detection of asymmetric vocal cord activity, the clinical history often proves to be useful. A history of hoarseness and prior surgery or intervention in the larynx, thyroid, neck, or mediastinum are pointers towards injury of one of the recurrent laryngeal nerves. Laryngoscopic examination will confirm impaired movement or paralysis of the contralateral vocal cord and, at the same time, will also exclude a primary pathology in the ipsilateral cord.

Pathologies arising along the course of the recurrent laryngeal nerves, such as masses or enlarged lymph nodes in the mediastinum or the root of the neck, can infiltrate the nerves, causing vocal cord paralysis.

Metastatic nodal involvement of the left recurrent laryngeal nerve is more common, due to its longer course through the aortopulmonary window. Hence, most descriptions of vocal cord paralysis detected on PET scan are due to left recurrent laryngeal nerve involvement. Kamel et al.[9] have reported six cases of lung cancer with recurrent laryngeal nerve palsy. All the patients had left laryngeal nerve involvement in their study.

The right recurrent laryngeal nerve arises from the vagus nerve as it passes in front of the right subclavian artery. It then curves below and behind the subclavian artery and angles medially as it courses superiorly in the tracheo-esophageal groove, behind the thyroid gland, toward the larynx. [Figure 4].

This particular case shows right vocal cord palsy due to nodal involvement of the right recurrent laryngeal nerve. Hypermetabolism was seen in the contralateral (left) vocal cord due to compensatory laryngeal muscle activation.

References

1. Fujimoto T, Itoh M, Tashiro M, Yamaguchi K, Kubota K, Ohmari H. Glucose uptake by individual skeletal muscles during running using whole body positron emission tomography. Eur J Appl Physiol 2000;83:297-302.
2. Kostakoglu L, Wong JC, Barrington SF, Cronin BF, Dynes AM, Maisey MN. Speech -related visualization of laryngeal muscles with Fluorine -18- FDG. J Nucl Med 1996;37:1771-3.
3. Lowe VJ, Kim Han, Boyd JH, Eisenbeis JF, Dumphy FR, Fletcher JW. Primary and recurrent early stage laryngeal cancer: Preliminary results of 2-(Fluorine 18) fluoro-2-deoxy-D-glusose PET imaging. Radiology 1999;212:799-802.
4. Truong MT, Erasmus JJ, Macapinlac HA, Podoloff DA. Teflon injection for vocal cord paralysis: False -positive finding on FDG PET-CT in a patient with non-small cell lung cancer. AJR Am J Roentgenol 2004;182:1587-9.
5. Heller MT, Meltzer CC, Fukui MB, Rosen CA, Chander S, Martinelli MA, *et al*. Superphysiologic FDG uptake in the non-paralyzed vocal cord. resolution of a false-positive PET result with combined PET-CT imaging. Clin Positron Imaging 2000;3:207-11.
6. Igerc I, Kumnig G, Heinisch M, Kresnik E, Mikosch P, Gallowitsch HJ, *et al*. Vocal cord muscle activity as a drawback to FDG-PET in the follow up of differentiated thyroid cancer. Thyroid 2002;12:87-9.
7. Chin BB, Patel P, Hammoud D. Combined positron emission tomography-computed tomography improves specificity for thyroid carcinoma by identifying vocal cord activity after laryngeal nerve paralysis. Thyroid 2003;13:1183-4.
8. Lee M, Ramaswamy MR, Lilien DL, Nathan CO. Unilateral vocal cord paralysis causes contralateral false-positive positron emission tomography scans of the larynx. Ann Otol Rhinol Laryngol 2005;114:202-6.
9. Kamel EM, Goerres GW, Burger C, von Schulthess GK, Steinert HC. Recurrent laryngeal nerve palsy in patients with lung cancer: Detection with PET-CT image fusion-Report of six cases. Radiology 2002;224:153-6.

Source of Support: Nil, **Conflict of Interest:** None declared.