

# Head and Neck

Prakash A Odedra, Shreedevi B Patel, Kirti G Goswami, Dhara D Patel

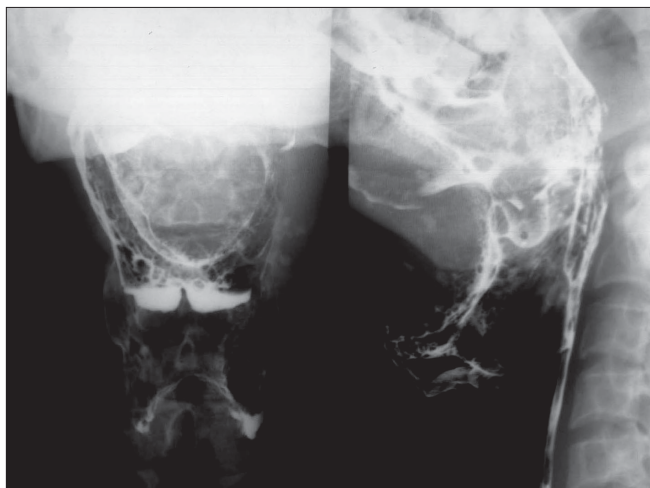Department of Radiology, The Gujarat Cancer and Research Institute, Civil Hospital Campus, Ahmedabad - 380 016, India

**Correspondence:** Dr. Prakash A. Odedra, Department of Radiology, The Gujarat Cancer and Research Institute, Civil Hospital Campus Ahmedabad - 380 016, India. E-mail: prakashodedra@yahoo.com

A 42-years-old man presented with a lobulated asymmetric enlargement of the tongue and fullness in the submental and upper neck region in the midline. The patient gave a history of having this problem since childhood with progressive slow enlargement. He had slowly developed difficulty in speech, tongue movement and deglutition. On local examination, there was a lobulated lump involving

the tongue and oral cavity. There was no ulcer in the buccal mucosa or oral cavity. There were no palpable neck nodes. Clinical examination of other major systems did not reveal any significant findings. Barium swallow was performed [Figure 1].

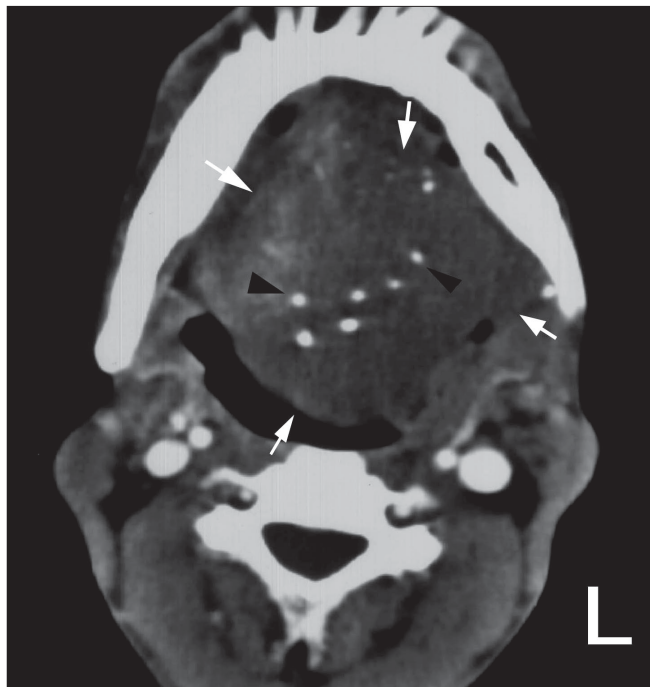
## What is your diagnosis?



**Figure 1:** Barium swallow frontal and lateral views

## Diagnosis: Cavernous Hemangioma of the tongue and oral cavity

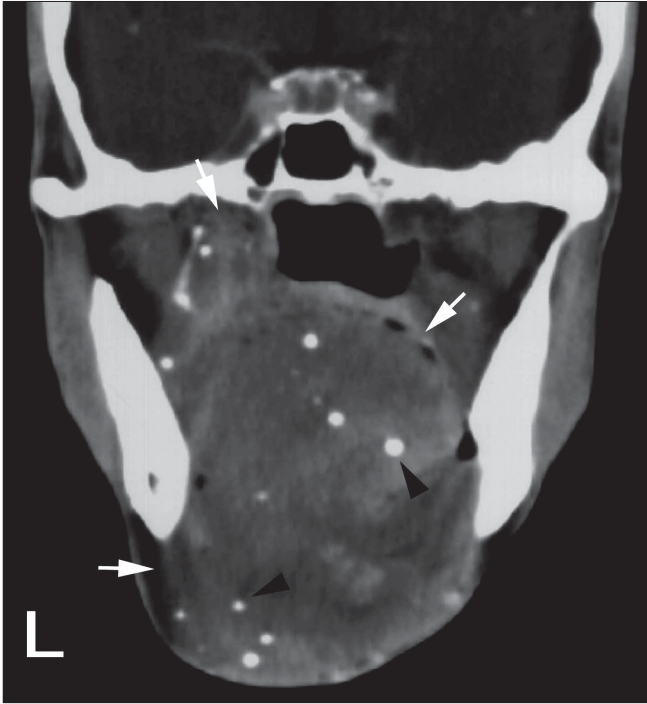
The frontal and lateral views of the barium swallow show the presence of a well-defined soft tissue opacity in the region of the base of the tongue, floor of the mouth and the left side of the upper neck, with phleboliths seen within the lesion [Figure 1]. There is no evidence of mucosal irregularity. Both vallecula and pyriform fossae appears normal. The pre-vertebral soft tissue space is normal. The axial and coronal contrast enhanced CT scan images of the oral cavity region show a diffuse hypodense lesion involving the tongue and its base and the floor of the mouth with extension into the left parapharyngeal space. The lesion is predominantly on the left and compromises the oral cavity. Multiple phleboliths are seen scattered within



**Figure 2:** Axial CT scan of the oral cavity showing a hypodense lesion (white arrows) involving the tongue with phleboliths (black arrowheads)

the lesion [Figures 2, 3].

Cavernous hemangioma is the term occasionally used for venous malformations.<sup>[1]</sup> In contrast to true hemangiomas, vascular malformations are not tumors, but rather true congenital vascular anomalies which are always present at birth, although they may not manifest clinically till late infancy or early childhood. These lesions demonstrate slow,



**Figure 3:** Coronal CT scan of the oral cavity showing a hypodense lesion (white arrows) involving the tongue and its base and floor of mouth with extension into the left parapharyngeal space with phleboliths (black arrowheads)

steady growth and neither regress nor involute. Vascular malformations are classified based on the predominant type of anomalous vessel involved, into capillary, venous, arterial and lymphatic malformations.<sup>[2,3]</sup> Venous malformations are the most common vascular malformations to affect the oral cavity. They may also involve the bones. They may attain enormous sizes and compromise the airway and cause difficulty in speech, mastication and deglutition. Although they are predominantly soft tissue masses, they may infiltrate deeply along fascial planes and rarely may be entirely intramuscular.<sup>[4]</sup> These lesions typically present as muscle density lesions on CT and manifest variable patterns of enhancement.

Venous malformations are slow flow lesions supplied by small arteries. On CT, they may not demonstrate sufficient enhancement to enable separation of their margins from the surrounding muscles, while angiographically one may not be able to identify their arterial supply.<sup>[5]</sup> The presence of phleboliths may be extremely helpful in suggesting the diagnosis of a venous malformation.<sup>[6]</sup> MRI study of vascular malformations offers a good depiction of vascular structures, permitting the differentiation between high-flow and low-flow vascular abnormalities. High flow lesions show typical signal flow voids both in T1W and T2W

sequences, with the appearance of serpentine images. Low flow lesions, on the other hand, also appear as meandering structures characterized by low signal on T1W images, but with moderate and homogeneous increased signal in T2W images. MR angiography techniques may help in the identification of the origin of the anomalous branches and provide an adequate pretherapeutic planning, when the possibility of embolization is considered.<sup>[7]</sup> Venous hemangiomas are encountered in the blue rubber bleb nevus syndrome and are also associated with multiple enchondromas in Maffucci's syndrome.<sup>[8]</sup>

Rapid enlargement of these lesions has been reported to occur in association with trauma, infection or endocrine changes (in puberty or pregnancy).<sup>[9]</sup> A variety of therapies has been used for the treatment of vascular malformations and hemangiomas with varying degrees of success. These include steroid administration, laser photocoagulation, sclerotherapy, embolization, subcutaneous interferon and surgical resection.<sup>[10]</sup>

## References

1. Mulliken JB. Classification of birth marks. *In:* Mulliken JB, Young AE, editors. *Vascular birthmarks, Hemangiomas and Malformations*. WB Saunders: Philadelphia; 1988. p. 24-37.
2. Chen JW, *et al.* Hemangiomas and vascular malformations. *BN1 Quart* 1994;10:19-25.
3. Baker LL, Dillion WP, Hieshima GB, Dowd CF, Frieden IJ. Hemangiomas and vascular malformations of head and neck: MR characterization. *AJNR* 1993;14:307-14.
4. Elahi MM, Parnes L, Fox A. Hemangioma of the masseter muscle. *J Otolaryngol* 1992;21:177-9.
5. Itoh K, Nishimura K, Togashi K, Fujisawa I, Nakano Y, Itoh H, *et al.* MR imaging of cavernous hemangioma of the face and neck. *J Comput Assist Tomogr* 1986;10:831-5.
6. Gelbert F, Riche MC, Reizine D, Guichard JP, Assouline E, Hodes JE, *et al.* MR imaging of head and neck vascular malformations. *J Magn Reson Imaging* 1991;1:579-84.
7. Cappabianca S, Del Vecchio W, Giudice A, Colella G. Vascular malformations of the tongue: MRI findings in three cases. *Dentomaxillofac Radiol* 2006;35:205-8.
8. Burrows PE, Laor T, Patel H, Robertson RL. Diagnostic imaging in the evaluation of vascular birthmarks. *Dermatol Clin* 1998;16:455-88.
9. Mulliken JB. Vascular malformations of the head and neck. *In:* Mulliken JB, Young AE, editors. *Vascular birthmarks, hemangiomas and malformations*. WB Saunders: Philadelphia; 1988. p. 24-37.
10. Som PM, Curtin HD. Head and neck imaging. *In:* Wendy RK, Smoker, *The oral cavity*. Missouri: Mosby; 4<sup>th</sup> ed. 2003. p. 1388.

**Source of Support:** Nil, **Conflict of Interest:** None declared.