

Torsion of the greater omentum: A rare preoperative diagnosis

Ankit Anil Tandon, Kian Soon Lim

Department of Diagnostic Radiology, Tan Tock Seng Hospital, 11 Jalan Tan Tock Seng – 308433, Singapore

Correspondence: Dr. Ankit Anil Tandon, Department of Diagnostic Radiology, Tan Tock Seng Hospital, 11 Jalan Tan Tock Seng – 308433, Singapore. E-mail: tandon_ankieth@yahoo.co.in

Abstract

Torsion of the greater omentum is a rare acute abdominal condition that is seldom diagnosed preoperatively. We report the characteristic computed tomography (CT) scan findings and the clinical implications of this unusual diagnosis in a 41-year-old man, who also had longstanding right inguinal hernia. Awareness of omental torsion as a differential diagnosis in the acute abdomen setting is necessary for correct patient management.

Key words: Conservative management; CT whirl sign; inguinal hernia; omental torsion

Introduction

We report the case of a 41-year-old Malay man with secondary omental torsion due to longstanding inguinal hernia. A contrast-enhanced CT scan of the abdomen showed a heterogeneous fat-density mass, with a characteristic whirling pattern of concentric streaks within the greater omentum. On the basis of this preoperative diagnosis, the patient underwent a successful trial of conservative management. There have only been a few reported cases of successful nonsurgical management of this rare acute abdominal condition.^[1,2] Moreover, the characteristic CT whirl sign as seen in our case has rarely been illustrated in literature.

Case Report

A 41-year-old Malay man initially presented to our Emergency Department with nonspecific abdominal pain. He had an eight-year history of untreated right inguinal hernia. On this occasion, the patient's symptoms settled with conservative treatment and he was discharged. He returned the following day with pain localized over the site of the inguinal hernia, and hence, was referred to the surgical team. A plain radiograph of the abdomen was unremarkable. *Ultrasonography* (USG) of the right inguinal region and scrotum was ordered, which confirmed the

presence of an uncomplicated right inguinoscrotal hernia, and an elective hernia repair was planned after 10 days.

On the day of admission for hernia repair, the patient complained of fever (37.9°C) and he had been having right iliac fossa pain for four to five days. Local examination showed no abdominal guarding or tenderness over the site of the hernia, which was still reducible. Blood investigations revealed an elevated total white cell count of $13.5 \times 10^9/l$, with neutrophil predominance ($10.2 \times 10^9/l$).

An urgent CT scan of the abdomen and pelvis was performed to exclude acute appendicitis. A CT scan revealed a hazy fat-density mass in the right side of the abdomen with a whirling pattern of concentric streaks [Figure 1, Video 1]. This mass was seen displacing the small bowel loops [Figure 2].

The patient was empirically treated with intravenous antibiotics and the elective hernia repair was deferred. Thereafter, the patient's signs and symptoms improved, with a corresponding decline in the white blood cell counts. Unilateral herniorrhaphy was performed a few days later. Exploratory laprotomy and omentectomy were not performed, as the patient had no abdominal complaints by then and there was no intraoperative evidence of omental or bowel herniation.

Discussion

Torsion of omentum is a rare acute condition in which

DOI: 10.4103/0971-3026.73540

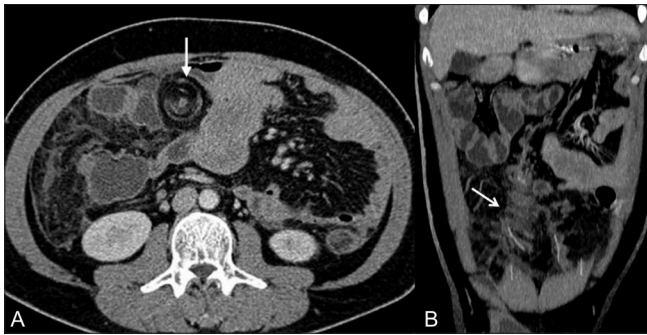


Figure 1 (A, B): Axial (A) and coronal (B) contrast-enhanced CT scans show a hazy fat-density mass in the right side of the abdomen, with concentric linear strands (white arrow) in the greater omentum. These strands represent blood vessels twisted around a central vascular pedicle

the organ twists around its long axis.^[3,4] The characteristic whirl pattern as seen in our case may not always be evident, especially when the axis of rotation is not perpendicular to the transverse scanning plane.^[5]

Omental torsion is classified as primary or secondary,^[3,4,6] the latter being more common. Primary torsion is usually seen in children above four years of age.^[7,8] Although its exact etiology is unknown,^[3] primary torsion is seen in patients with anatomical variations such as tongue-like projections from the free edge of the omentum, bifid omentum, and accessory omentum.^[5] Judy *et al*, concluded that obesity is an important risk factor for omental torsion in children.^[7] Primary omental torsion should also be suspected in children with negative laparotomy for acute appendicitis or Meckel diverticulitis, especially in the presence of serosanguinous peritoneal fluid.^[3,6]

Secondary omental torsions are usually seen in the presence of a bulky abdominal tumor,^[4,5,8] hernia,^[4,5,8] or as sequelae of a surgical procedure like Roux-en-Y gastric bypass.^[5] These pathological conditions may cause focal scarring and adhesions within the greater omentum, predisposing the remainder of the mobile omentum to twist around this pivot.

Although the etiologies may be different in primary and secondary torsions, the precipitating factors are similar and include either a sudden increase in the intra-abdominal pressure due to exertion, coughing or sneezing, or the occupational use of vibrating tools.^[4,5,8] These events may lead to a sudden shift of omentum, resulting in torsion.^[5]

The pathological process begins with omental congestion due to venous obstruction, which leads to an inflammatory response, adhesion formation, and finally, necrosis as a result of both venous and arterial obstruction.^[4-8] Thus, torsion leads to omental infarction, which presents as abdominal pain. Omental infarction can also occur in

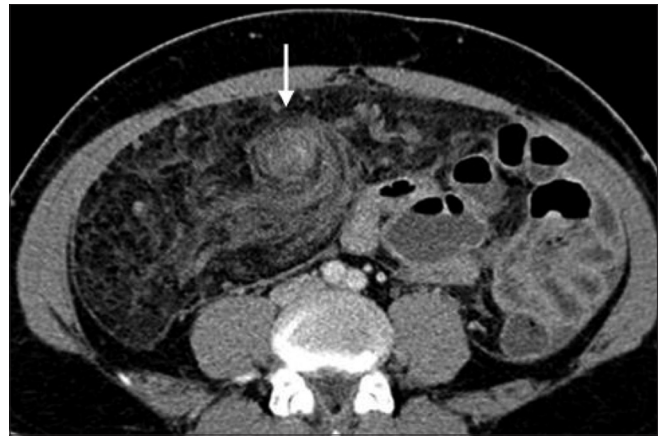

Figure 2: A contrast-enhanced CT scan shows a hazy right side of the greater omentum, with concentric hyperdensity (white arrow) and displacement of the bowel loops

the absence of torsion, when it is described as primary idiopathic segmental infarction.^[6] Spontaneous derotation of omental torsion is also possible and may explain the nonspecific omental adhesions sometimes found during laparotomy.^[3]

Clinically, torsion of the omentum often mimics other more common acute abdominal conditions such as, appendicitis, cholecystitis, cecal diverticulitis, appendagitis, twisted ovarian cyst, and so on.^[4,6] The higher frequency of the right-sided omental torsion, which is due to its greater length and mobility,^[4,5] only adds to the confusion.^[5]

A CT scan shows either an inflamed fat-containing mass with concentric streaks around a vascular pedicle or a whirling pattern of fibrous and fatty folds^[6,8,9] within the greater omentum. The USG diagnosis of this condition may be limited due to the presence of bowel gases or due to operator dependency.^[6,8]

Complications of omental torsion include omental necrosis,^[3] peritonitis,^[3] bowel obstruction,^[3,6] adhesion formation,^[8] and sepsis,^[8] which makes its early diagnosis critical. However, the diagnosis of omental torsion is seldom made preoperatively.^[3,5,8] Furthermore, even the intraoperative diagnosis of omental torsion is not easy through a McBurney incision or any other infraumbilical incision.^[8] However, this is likely to change with the increasing use of the CT scan in the diagnosis of acute abdominal conditions.^[5,6]

Traditionally, omentectomy has been the treatment of choice^[6] for omental torsion and only a few cases of successful conservative management have been reported. Nonsurgical management was possible in our case due to the preoperative diagnosis and the absence of any significant complication.^[5,6]

In summary, an accurate diagnosis of greater omental torsion can be made with a CT scan. Although it is a rare acute abdominal condition, torsion of the omentum should be carefully excluded in patients with known predisposing factors, such as an inguinal hernia.

References

1. Miguel Perelló J, Aguayo Albasini JL, Soria Aledo V, Aguilar Jiménez J, Flores Pastor B, Candel Arenas MF, *et al.* Omental torsion: Imaging techniques can prevent unnecessary surgical interventions. *Gastroenterol Hepatol* 2002;25:493-6.
2. Naffaa LN, Shabb NS, Haddad MC. CT findings of omental torsion and infarction: Case report and review of the literature. *Clin Imaging* 2003;27:116-8.
3. Tamamoto F, Ishizaki H, Takanashi T, Shimoji K, Okamura T, Yoshimura T, *et al.* Omental torsion with right-sided inguinal hernia. *Radiat Med* 2005;23:566-9.
4. Xavier S, John P. Torsion of the greater omentum with inguinal hernia. *Indian J Gastroenterol* 2003;22:194-6.
5. Hirano Y, Oyama K, Nozawa H, Hara T, Nakada K, Hada M, *et al.* Left sided omental torsion with inguinal hernia. *World J Gastroenterol* 2006;12:662-4.
6. Breunung N, Strauss P. A diagnostic challenge: Primary omental torsion and literature review - a case report. *World J Emerg Surg* 2009;4:40.
7. Theriot JA, Sayat J, Franco S, Buchino JJ. Childhood obesity: A risk factor for omental torsion. *Pediatrics* 2003;112:460.
8. Al Tokhais TI, Bokhari AA, Noureldin OH. Primary omental torsion: A rare cause of acute abdomen. *Saudi J Gastroenterol* 2007;13:144-6.
9. Aoun N, Haddad-Zebouni S, Slaba S, Noun R, Ghossain M. Left-sided omental torsion: CT appearance. *Eur Radiol* 2001;11:96-8.

Source of Support: Nil, Conflict of Interest: None declared.

Video available at www.ijri.org

New features on the journal's website

Optimized content for mobile and hand-held devices

HTML pages have been optimized of mobile and other hand-held devices (such as iPad, Kindle, iPod) for faster browsing speed.

Click on [**Mobile Full text**] from Table of Contents page.

This is simple HTML version for faster download on mobiles (if viewed on desktop, it will be automatically redirected to full HTML version)

E-Pub for hand-held devices

EPUB is an open e-book standard recommended by The International Digital Publishing Forum which is designed for reflowable content i.e. the text display can be optimized for a particular display device.


Click on [**EPub**] from Table of Contents page.

There are various e-Pub readers such as for Windows: Digital Editions, OS X: Calibre/Bookworm, iPhone/iPod Touch/iPad: Stanza, and Linux: Calibre/Bookworm.

E-Book for desktop

One can also see the entire issue as printed here in a 'flip book' version on desktops.

Links are available from Current Issue as well as Archives pages.

Click on  View as eBook