

# Pictorial essay: Interventional radiology in the management of hemodialysis vascular access - A single-center experience

Suraj Mammen, Shyamkumar N Keshava, Vinu Moses, Surendra Babu, Santhosh Varughese<sup>1</sup>

Departments of Radiology and <sup>1</sup>Nephrology, Christian Medical College, Vellore, Tamil Nadu, India

**Correspondence:** Dr. Suraj Mammen, Department of Radiology, Christian Medical College, Vellore, Tamil Nadu, India.

E-mail: drsurajmammen@yahoo.co.in

## Abstract

Chronic kidney disease (CKD) is a worldwide public health problem and is associated with high morbidity and mortality. The majority of patients with CKD stage 5 (CKD-5), who cannot undergo renal transplant, depend on maintenance hemodialysis by surgically created access sites. Native fistulae are preferred over grafts due to their longevity. More than half of these vital portals for dialysis access will fail over time. Screening procedures to select high-risk patients before thrombosis or stenosis appears have resulted in aggressive management. These patients are referred for angiographic evaluation and/or therapy. We present the patterns of dialysis-related interventions done in our institution.

**Key words:** Hemodialysis access intervention; vascular access management; angioplasty

## Introduction

Chronic kidney disease (CKD) is a worldwide public health problem and is associated with high morbidity and mortality.<sup>[1,2]</sup> Unfortunately, the absence of a comprehensive registry makes it impossible to exactly quantify the burden of the disease in a developing country like India. Renal transplantation is the most desirable and definitive treatment of CKD but this option is not available to many patients because of the cost and complexity of the treatment.<sup>[1]</sup> The majority of patients with CKD stage 5 (CKD-5) who cannot undergo renal transplant depend on maintenance hemodialysis by surgically created access sites.<sup>[3]</sup> Hemodialysis shunts are surgically created communications between arteries and veins. There are two shunt systems: direct communications, termed as native arteriovenous fistulae, and interposition of prosthetic

material as a communicating medium between an artery and a vein, called an arteriovenous graft.<sup>[4]</sup> Native fistulae are preferred over grafts due to their longevity.<sup>[5,6]</sup> Unfortunately, more than half of these vital portals for dialysis access will fail within 2 years.<sup>[7]</sup>

Reports indicate a decreasing interval between placement of a vascular access and the need for a surgical procedure to restore patency; moreover, restoration of patency involves significant costs. Hence, many institutions have adopted aggressive screening procedures to select high-risk patients who can be administered prophylactic treatment before thrombosis or stenosis appears and leads to malfunction of the hemodialysis access.<sup>[8]</sup> Screening methods currently used include physical examination (a change in the bruit, thrill, pulse, etc.),<sup>[9]</sup> access recirculation, dynamic venous dialysis pressures, static venous pressures, intra-access flows, and duplex and color Doppler USG.<sup>[3]</sup> Abnormal screening results have been attributed to the presence of venous stenosis in 80–90% of cases. These patients are hence referred for angiographic evaluation and/or therapy.<sup>[8]</sup> We present the patterns of dialysis-related interventions done at a tertiary care center in India.

## Materials and Methods

A retrospective analysis of the data from our institution,

### Access this article online

#### Quick Response Code:



Website:  
www.ijri.org

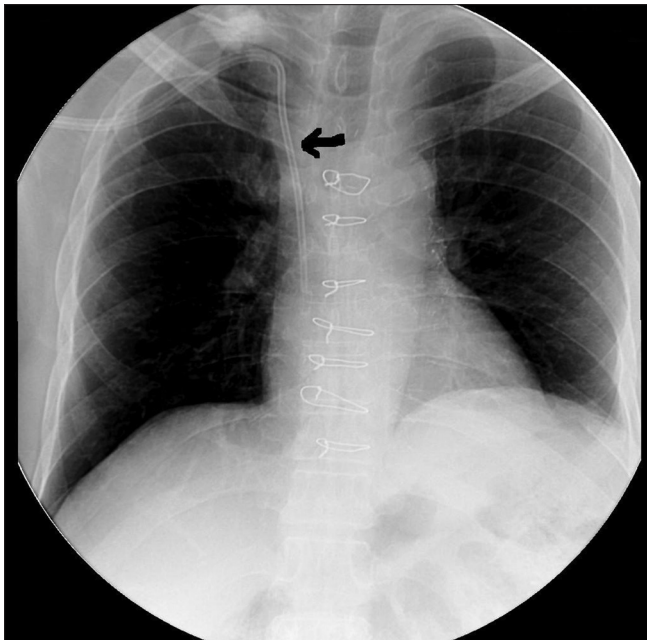
DOI:  
10.4103/0971-3026.95397

which is a tertiary care center in India, over the past decade (2000–2010), showed 171 interventional procedures done for dialysis vascular access. The procedures were performed in the digital subtraction angiography (DSA) suite, under local anesthesia and aseptic precautions using a Siemens Multistar<sup>®</sup> DSA machine. Informed consent was obtained prior to all procedures. The types and the number of procedures done are displayed in Table 1.

**a. Venous access:** This was performed when the case was referred by the attending nephrologists for unsuccessful or difficult access to the venous catheter due to an anatomical variation. The usual dialysis catheter includes a 12F bi-lumen internal jugular vein [IJV] catheter (Quinton<sup>™</sup>) or a Permcath<sup>™</sup> (Quinton<sup>™</sup>) [Figure 1]. The access created was usually through the right or left internal jugular veins. Whenever tunneling was required for a cuffed catheter, it was usually done under local anesthesia.

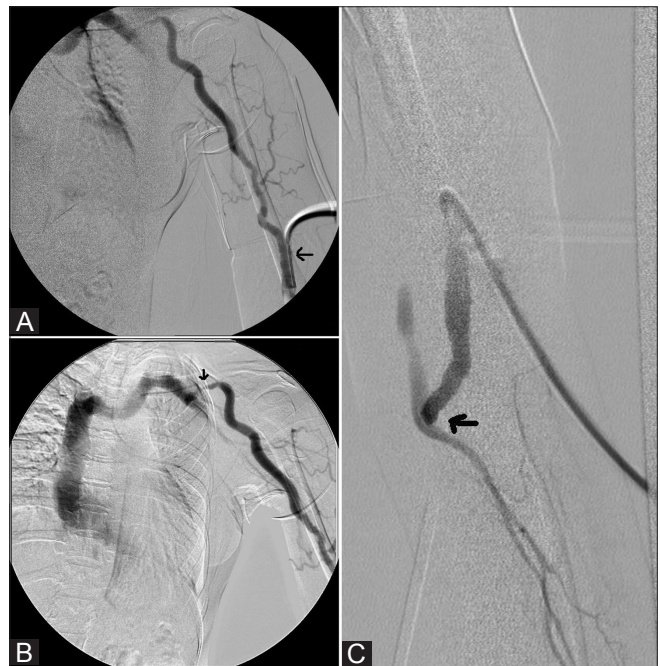**Table 1: The list and types of dialysis-related interventions done over a period of one decade**

Type of procedure	Number of cases
Venous access	53
Fistulogram	56
Venoplasty/stenting of the central veins	17
Venoplasty of the peripheral veins	11
Venoplasty in dialysis fistulae	3
Fibrin sheath stripping	9
Venogram	16
Access catheter repositioning	11
Total	171



**Figure 1:** A 45-year-old man with CKD presurgical fistula creation underwent Permcath<sup>™</sup> insertion (arrow)

- b. Fistulogram:** This was performed by placing a 16G cannula on the arterial side of the vein, just above the anastomosis, and demonstrating the runoff veins to the superior vena cava (SVC)–right atrial junction [Figure 2]. The arterial inflow and anastomosis of the fistula or graft connection were demonstrated by applying a sphygmomanometer cuff on the arm and inflating the cuff well above the patient's systolic blood pressure. The major category of hemodialysis patients referred for angiographic evaluation and therapy comprise patients with a clinical manifestation of access failure or impending access failure suspected because of decreased blood flow. The most common reported presentation is a thrombosed access.<sup>[10]</sup> Other clinical manifestations include extremity edema, prolonged postdialysis bleeding, poor dialysis flow rates, difficult needle cannulation of the access, and "inefficient dialysis" manifested as decreased urea reduction ratios.
- c. Venoplasty in the dialysis fistulae:** Long-term indwelling catheters and arterialized blood flow may lead to the development of venous neointimal hyperplastic stenoses, thrombosis and occlusion of the venous anastomoses, within the graft, in the venous outflow tract, or in the central veins.<sup>[1]</sup> Venoplasty is performed when there is a functionally significant stenosis (more than 50% reduction in the normal vessel diameter), accompanied by hemodynamic and clinical abnormalities like abnormal recirculation values, elevated venous pressure during dialysis, detection of



**Figure 2 (A-C):** A 42-year-old lady with a brachiocephalic AVF, with poor dialysis flow rate demonstrated on fistulogram. A 16G cannula was placed on the cephalic vein (arrow), a few centimeters above the surgical scar (A). Frontal venogram (B) shows a short segment focal stenosis (arrow) distally. Frontal spot radiograph (C) shows the A-V fistula (arrow)

reduced blood flow, swollen limb or an unexplained cause for reduced small-solute clearance (lower Kt/V by urea kinetic modeling).<sup>[8,11,12]</sup>

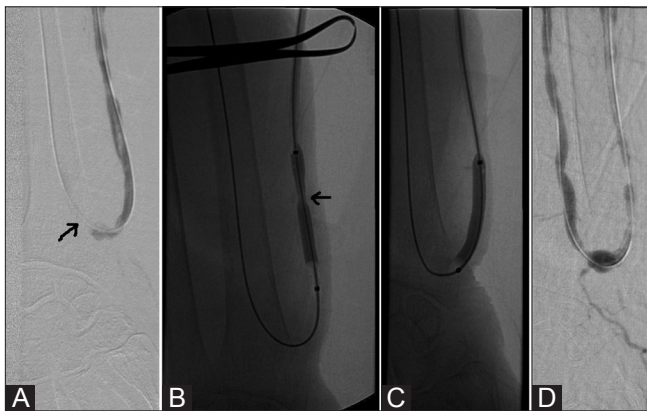
Percutaneous treatment is defined as the restoration of an acceptable lumen diameter and resolution of the functional abnormality. Stenoses are treated by balloon angioplasty. Because the fibrotic, rubbery nature of the hemodialysis access-related stenoses may lead to incomplete dilatation and early or delayed elastic recoil, a cutting balloon is often used to overcome this problem [Figure 3].

**d. Venoplasty/Stenting in the central/peripheral veins:**

The treatment of central venous stenoses and occlusions has been performed for prolonging the viability of upper extremity hemodialysis access sites and for the treatment of symptomatic upper extremity edema. Percutaneous balloon angioplasty can successfully treat central/peripheral venous stenoses with excellent hemodynamic results. However long-term primary patency is poor. In cases of incomplete dilatation and to avoid early or delayed elastic recoil some authors favor primary stent placement for the treatment of central venous occlusions. In our institution, we manage central venous occlusion by primary stent placement [Figures 4 and 5] and peripheral venous stenoses by venoplasty [Figures 6 and 7] with good medium-term patency rate.

**e. Venogram:** This is performed by obtaining an IJV access with an 18G Insyte™ and demonstrating the draining veins, i.e., from the IJV to the SVC–right atrial junction.

**f. Fibrin sheath stripping:** Long-term indwelling catheters may result in the formation of a fibrin sheath around the outlet of the catheter at the cavoatrial junction, resulting in poor inflow/outflow during dialysis exchange. The fibrin sheath is stripped by accessing the catheter tip



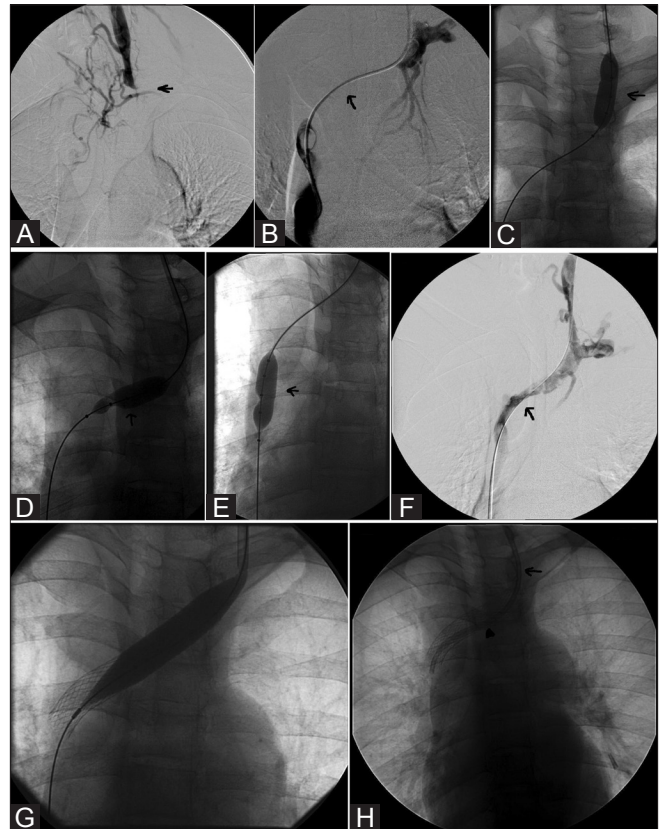
**Figure 3 (A-D):** A 70-year-old man with stenosis of the arteriovenous fistula demonstrated on venogram followed by balloon angioplasty. Frontal venogram (A) shows mild stenosis of the arteriovenous fistula, with a wire (arrow) across the stenosis. The sequential cutting balloon angioplasty of the stenotic cephalic vein and arteriovenous fistula (arrow) is seen (B-C). Venogram (D) shows good restoration and flow across the lumen (arrow)

from the femoral venous route with the help of a goose-neck snare [Figure 8].

## Discussion

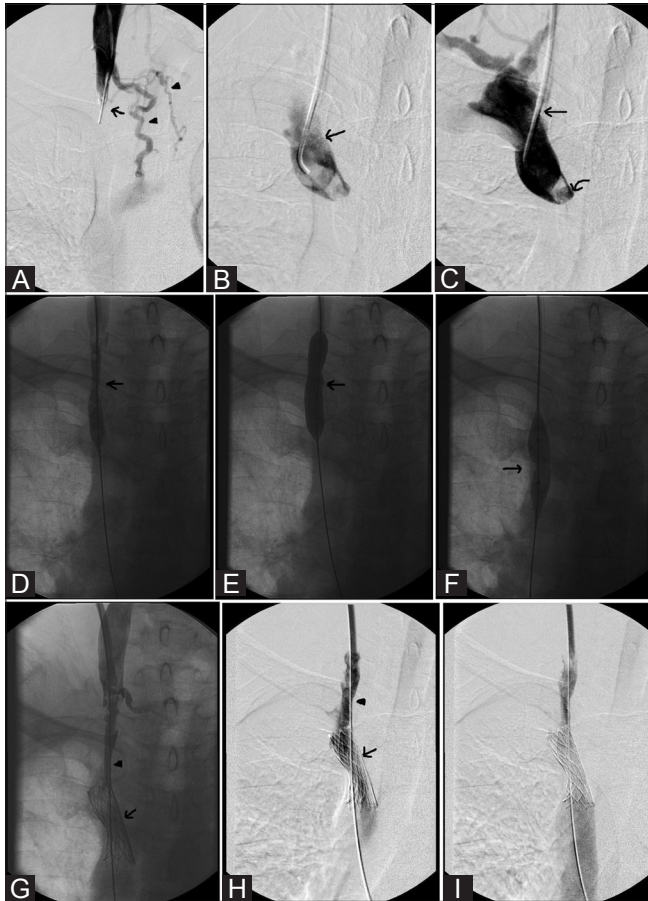Technological progress in the fields of interventional radiology and device manufacturing has allowed a large segment of the dialysis population to be treated without the need for open surgery. Percutaneous procedures can salvage both fistulas and central veins without sacrificing venous outflow, thus prolonging the usage and overall life of the access.

The primary patency rate is defined as the uninterrupted patency after intervention until the next access failure or reintervention. Secondary patency rate after intervention is defined as the patency until the access is surgically declotted, revised, or abandoned, or until the patient undergoes renal transplantation or is lost to follow-up. Complications are most frequently related to the access, and include puncture




**Figure 4 (A-H):** A 33-year-old man with subclavian venous stenosis demonstrated on venogram. He underwent successful angioplasty and stenting of the brachiocephalic–SVC segment and a PermCath™ insertion. Frontal venograms (A) show the occlusion (arrow). Subsequent venogram (B) shows the occlusion crossed with a pigtail catheter across the occlusion (arrow). The sequential balloon pigtail angioplasty (arrow) is seen (C-E). Venogram (F) shows the restoration of the lumen (arrow) with recoil. The stent is seen deployed in the brachiocephalic–SVC segment with balloon remodeling in G. Frontal spot radiograph (H) shows a fully expanded stent (arrow) with PermCath™ (arrowhead) *in situ*

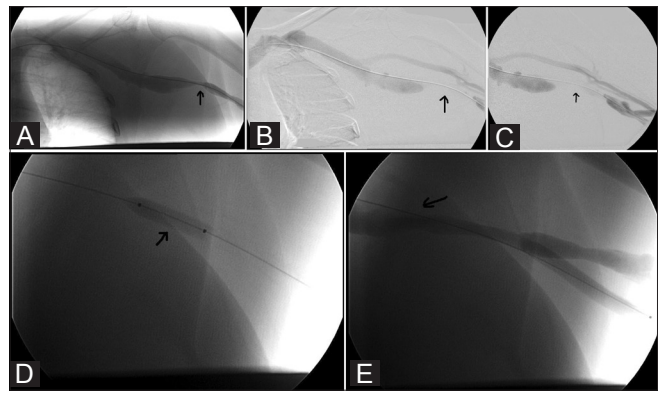
site bleeding, venous occlusion/thrombosis, and vascular perforation. There was only one documented immediate complication due to thrombosis following fistuloplasty. The main limitation of our study was that, due to various



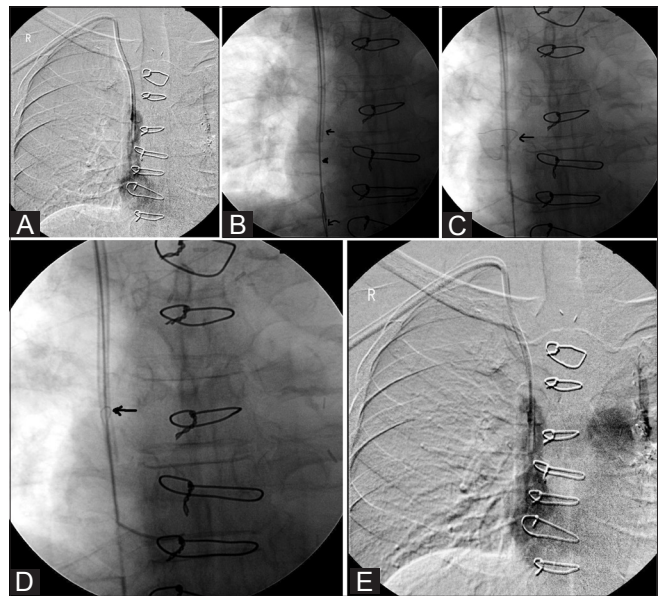
**Figure 5 (A-I):** A 54-year-old man with right IJV thrombosis causing SVC syndrome. Venogram (A) shows complete occlusion of the right IJV (arrow), with draining collaterals (arrow head). Recanalization venograms (B,C) show an irregular filling defect in the SVC (arrow) and a tight web at the cavo-atrial junction (curved arrow in C). Sequential balloon plasty of the right IJV and SVC (arrow) is seen (D-F). Venogram (G) shows restoration of the lumen, with SVC stenting done due to elastic recoil (arrow). Persistent brachiocephalic recoil (arrowhead) is seen. Frontal spot radiographs (H,I) show good restoration of the lumen, poststenting balloon remodeling (arrowhead), with the SVC stent in situ (arrow)



**Figure 6 (A-C):** A 48-year-old lady with a left upper limb dialysis fistula and venous stenosis of the cephalic vein demonstrated on a fistulogram, successfully treated with cutting balloon angioplasty. Frontal radiograph (A) shows irregular stenosis, with a glide wire across the stenosis (arrow). Subsequent (B) cutting balloon angioplasty being performed at the site of stenosis (arrow). Frontal venogram (C) shows complete restoration of the lumen



**Figure 7 (A-E):** A 65-year-old lady with focal stenosis of the junction of the left basilic vein–axillary vein underwent cutting balloon angioplasty. Frontal venograms (A–C) show critical stenosis of a short segment of the axillary vein, with a glide wire across the stenosis (arrow); followed by (D) balloon angioplasty of the stenosis (arrow). Subsequent postvenoplasty venogram (E) shows complete restoration of the lumen (arrow)



**Figure 8 (A-E):** A 54-year-old man with a Permcath, with poor dialysis flow through the catheter, demonstrated on venogram. Frontal venogram (A) shows poor contrast outflow from the catheter. The sequential stripping procedure (B-D) performed with a guide wire (arrowhead) passed through the central lumen of the Permcath (arrow) and a gooseneck snare passed from the femoral access (curved arrow). Frontal spot radiograph (E) shows prompt flow of contrast through the catheter

reasons, we did not have long-term follow-up of the primary patency rate. With this study we aim to highlight the need for a prospective study on dialysis-related interventions and to create awareness about the various patterns of these interventions among young interventionalists.

## References

1. Agarwal SK, Dash CS, Irshad M, Raju S, Singh R, Pandey RM. Prevalence of chronic renal failure in adults in Delhi, India. *Nephrol Dial Transplant* 2005;20:1638-42.
2. Schieppati A, Remuzzi G. Chronic renal diseases as a public health problem: Epidemiology, social, and economic implications. *Kidney Int* 2005;68:S7-10.
3. Henry ML. Routine surveillance in vascular access for hemodialysis. *Eur J Vasc Endovasc Surg* 2006;32:545-8.
4. National Kidney Foundation. K/DOQI Clinical Practice Guidelines for Vascular Access, 2000. *Am J Kidney Dis* 2001;37 Suppl 1:S137-81.
5. Hyland K, Cohen RM, Kwak A, Goldberg RD, Soulen MC, Patel AA, *et al.* Preoperative mapping venography in patients who require hemodialysis access: Imaging findings and contribution to management. *J Vasc Interv Radiol* 2008;19:1027-33.
6. Huijbregts HJ, Blankestijn PJ. Dialysis access-Guidelines for current practice. *Eur J Vasc Endovasc Surg* 2006;31:284-7.
7. Forauer AR, Hoffer EK, Homa K. Dialysis access venous stenosis: Treatment with balloon angioplasty-1-versus 3- minutes inflation times. *Radiology* 2008;249:375-81.
8. Gray RJ, Sacks D, Martin LG, Trerotola SO. Reporting standards for percutaneous interventions in dialysis access. *J Vasc Interv Radiol* 2003;14:S433-42.
9. Haage P, Gunther RW. Radiological intervention to maintain vascular access. *Eur J Vasc Endovasc Surg* 2006;32:84-9.
10. Cooper SG, Sofocleous CT. Dialysis access. *Semin Roentgenol* 2003;37:327-42.
11. National Kidney Foundation. K/DOQI Clinical Practice Guidelines for Hemodialysis Adequacy, 2000. *Am J Kidney Dis* 2001;37 Suppl 1:S7-64.
12. Aruny JE, Lewis CA, Cardella JF, Cole PE, Davis A, Drooz AT. Quality improvement guidelines for percutaneous management of the thrombosed or dysfunctional dialysis access. *J Vasc Interv Radiol* 1999;10:491-8.

**Cite this article as:** Mammen S, Keshava SN, Moses V, Babu S, Varughese S. Pictorial essay: Interventional radiology in the management of hemodialysis vascular access - A single-center experience. *Indian J Radiol Imaging* 2012;22:14-8.

**Source of Support:** Nil, **Conflict of Interest:** None declared.

## Announcement

### "Quick Response Code" link for full text articles

The journal issue has a unique new feature for reaching to the journal's website without typing a single letter. Each article on its first page has a "Quick Response Code". Using any mobile or other hand-held device with camera and GPRS/other internet source, one can reach to the full text of that particular article on the journal's website. Start a QR-code reading software (see list of free applications from <http://tinyurl.com/yzlh2tc>) and point the camera to the QR-code printed in the journal. It will automatically take you to the HTML full text of that article. One can also use a desktop or laptop with web camera for similar functionality. See <http://tinyurl.com/2bw7fn3> or <http://tinyurl.com/3ysr3me> for the free applications.