

# Acute visual loss as the initial presentation in a child with systemic Burkitt lymphoma

Maria Kourti,  
Elpidoforos Mantadakis<sup>1</sup>,  
Athanassia Anastasiou<sup>2</sup>,  
Dimitrios Koliousskas

Department of Pediatric Oncology,  
and <sup>1</sup>Radiology, Hippokraton  
General Hospital, Thessaloniki,  
Greece, <sup>2</sup>Department of Pediatrics,  
Dimokritus University of Thrace,  
Alexandroupolis, Greece

## Address for correspondence:

Dr. Maria Kourti,  
Sakellaridi 25,  
Thessaloniki, Greece.  
E-mail: makourti@med.auth.gr

## ABSTRACT

Non-Hodgkin lymphoma (NHL) accounts for 10% of pediatric malignancies and is the third most common malignancy in childhood. We report a previous healthy 3-year-old boy with stage IV Burkitt lymphoma presenting with acute visual loss. In funduscopy his pupils were fixed at 6 mm in diameter without light perception. He started therapy according to the UKCCSG 9003 protocol. The boy didn't show any visual improvement but some slight light perception despite his partial remission after CYVE II. He died of neutropenic septicemia before his scheduled radiotherapy. In conclusion, loss of vision is a rare presenting sign in NHL. Differential diagnosis is crucial as early diagnosis and effective treatment are important for survival as well as for visual restoration.

**Key words:** *Blindness, Burkitt lymphoma, childhood*

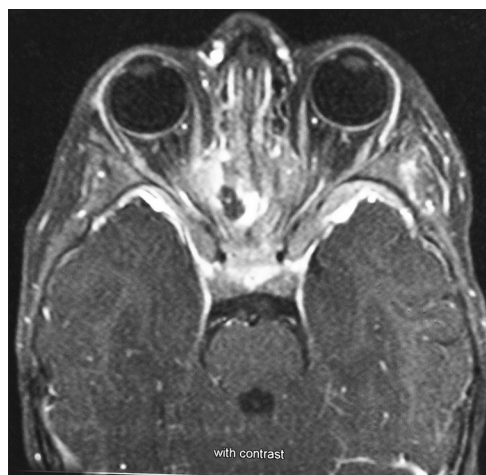
## INTRODUCTION

Non-Hodgkin lymphoma (NHL) accounts for 10% of pediatric malignancies and is the third most common malignancy in childhood. Central nervous system (CNS) involvement in NHL is uncommon occurring in about 10% of cases.<sup>[1]</sup> Ocular involvement in NHL occurs as primary ocular, central nervous system lymphoma or isolated intraocular lymphoma, but optic nerve and chiasmal disease is very rare. At the time of presentation, signs and symptoms depend on the site and degree of involvement, the stage of the malignancy and the histological subtype of the disease. Although the head and neck region is a common site for extranodal involvement, acute loss of vision is a rare presenting symptom of NHL and only 9 cases are reported.<sup>[2]</sup>

## CASE REPORT

We report a case of a 3-year-old boy with acute visual loss in both eyes, who had been diagnosed with stage IV NHL with bone marrow, abdominal and CNS involvement.

The child was admitted with complaint of acute blindness in both eyes without a remarkable past medical history. In funduscopy, his pupils were fixed at 6 mm in diameter without light perception. Cranial magnetic resonance imaging (MRI) demonstrated masses arising within the sphenoid sinus and invading the orbits and ethmoidal sinuses causing bilateral compression on optic nerves [Figure 1] The diagnosis of B-NHL was defined cytologically and immunologically in the bone marrow aspirates and cerebrospinal fluid (CSF). Abdominal computed tomography also depicted tumoral infiltration of the kidneys and abdominal lymphadenopathy. His acute



**Figure 1:** Cranial magnetic resonance imaging (MRI) demonstrating masses arising within the sphenoid sinus and invading the orbits and ethmoidal sinuses causing bilateral compression on optic nerves

## Access this article online

### Quick Response Code:



Website:  
[www.ijmpo.org](http://www.ijmpo.org)

DOI:  
10.4103/0971-5851.116188

blindness was attributed to optic nerve compression in addition to the high proliferation rate characteristic of Burkitt lymphoma. Once the diagnosis was established, he started therapy according to the UKCCSG 9003 protocol. Response to chemotherapy was monitored by appropriate restaging investigations after COP and CYVE II. The boy did not show any visual improvement but some slight light perception despite his partial remission after CYVE II as depicted in restaging investigations. Unfortunately, he relapsed in the CNS and died secondary to neutropenic septicemia 6 months after diagnosis before his scheduled radiotherapy without ever achieving complete remission.

## DISCUSSION

This report describes a patient with systemic Burkitt lymphoma illustrating an important point that loss of vision may be the presenting symptom in systemic NHL at diagnosis. Previous reports have documented optic neuropathy with CNS involvement in adult patients with systemic lymphoma in clinical remission.<sup>[3]</sup> Although series of pediatric ocular and orbital lymphomas have been reported, optic nerve infiltration from systemic NHL in the pediatric age group at diagnosis are extremely limited.<sup>[4]</sup> Optic nerve involvement has been associated with lymphomatous infiltration, infections, vincristine-related neuropathy, neurotoxic drugs, radionecrosis and paraneoplasia.<sup>[5]</sup> Nasal–paranasal oropharyngeal lymphoma affects elderly individuals most commonly. However, it can also occur in children, with a median age of 5 years. In their majority, primary tumors of the paranasal sinuses present with pain and cranial nerve palsies.<sup>[6]</sup> The diagnosis of paranasal lymphoma involving the optic nerves should also be included in the differential diagnosis of sudden visual loss. Of the nine previous cases already reported, seven children had bilateral blindness and their visual ability improved in only two cases. Mean age of the reported cases was 8.1 years (range 4-16 years old) with our patient being the youngest.

Differential diagnosis is essential since early diagnosis and appropriate treatment are important factors for survival. Optic nerve involvement by systemic lymphoma is thought to occur from direct invasion by tumor cells, which tend to infiltrate cranial and spinal nerves or it may develop

as a complication of leptomeningeal lymphomatosis or orbital lymphoma.<sup>[7]</sup> Although, CNS involvement in NHL is regarded as a bad prognostic factor by using high-dose methotrexate and intrathecal chemotherapy, event-free survival rates have significantly increased up to 75%.<sup>[8,9]</sup> Radiotherapy even for CNS involvement is probably no further beneficial in addition to chemotherapy. Nevertheless, it is an option usually confined to exceptional circumstances like persistent disease after chemotherapy, like ours.

In conclusion, acute blindness is an extremely rare presenting sign in NHL in children. Neuroimaging is a helpful tool in establishing the diagnosis. Early recognition and prompt management is essential to preserve or maximize visual function.

## REFERENCES

1. Sandlund JT, Downing JR, Crist WM. Non-Hodgkin's lymphoma in childhood. *N Engl J Med* 1996;334:1238-48.
2. Emami N, Daniel SJ. Acute bilateral blindness as a presenting symptom of Non-Hodgkin's lymphoma. *Int J Pediatr Otorhinolaryngol* 2012;76:740-1.
3. Lee LC, Howes EL, Bhisitkul RB. Systemic non-Hodgkin's lymphoma with optic nerve infiltration in a patient with AIDS. *Retina* 2002;22:75-9.
4. Zaman AG, Graham EM, Sanders MD. Anterior visual system involvement in Hodgkin's lymphoma. *Br J Ophthalmol* 1993;77:184-7.
5. Bakhshi S, Sidhu T. Pediatric orbital and ocular lymphomas. *Pediatr Blood Cancer* 2008;50:940-1.
6. Evans LS, Hancock BW. Non-Hodgkin lymphoma. *Lancet* 2003;362:139-46.
7. Chamberlain MC. Current concepts in leptomeningeal metastasis. *Curr Opin Oncol* 1992;4:533-9.
8. Patte C, Auperin A, Michon J, Behrendt H, Leverger G, Frappaz D, *et al.* The Société Française d'Oncologie Pédiatrique LMB89 protocol: Highly effective multiagent chemotherapy tailored to the tumor burden and initial response in 561 unselected children with B-cell lymphomas and L3 leukemia. *Blood* 2001;97:3370-9.
9. Atra A, Gerrard M, Hobson R, Imeson JD, Ashley S, Pinkerton CR. Improved cure rate in children with B-cell acute lymphoblastic leukaemia (B-ALL) and stage IV B-cell non-Hodgkin's lymphoma (B-NHL)-results of the UKCCSG 9003 protocol. *Br J Cancer* 1998;77:2281-5.

**How to cite this article:** Kourti M, Mantadakis E, Anastasiou A, Kolioukas D. Acute visual loss as the initial presentation in a child with systemic Burkitt lymphoma. *Indian J Med Paediatr Oncol* 2013;34:99-100.

**Source of Support:** Nil, **Conflict of Interest:** None declared.