

Giant mediastinal carcinoid

A 25-year-old male was presented with cough. Computed tomography (CT) scan showed anterior mediastinal mass [Figure 1] encasing the aortic arch and left brachiocephalic vein with compression of the superior vena cava. CT-guided biopsy showed neuroendocrine tumor staining with chromogranin, synaptophysin, and neuron specific enolase. Postchemoradiotherapy positron emission tomography-CT scan revealed static disease [Figure 2]. At surgery, the mass could be dissected off the major vessels; the thrombosed left brachiocephalic vein was resected. Good collaterals obviated the need for vascular reconstruction. The patient recovered after a stormy postoperative course. Histopathology report showed neuroendocrine carcinoma, mitotic rate of 10/10 HPF, and MIB-1 proliferation index of 8-10%. On 5-year follow-up, the patient is asymptomatic and disease-free on CT scan.

Thymic carcinoids are rare, accounting for 2% of all carcinoids; often invading locally and metastasizing distantly. Complete surgical resection is potentially curative. Prognosis is correlated with the degree of differentiation and completeness of resection.

Sabita Jiwnani, George Karimundackal, C. S. Pramesh

*Division of Thoracic Surgery and Oncology,
Tata Memorial Hospital, Mumbai, Maharashtra, India*

Address for correspondence:

Dr. C. S. Pramesh,
Department of Surgical Oncology, Division of Thoracic Surgery,
Tata Memorial Hospital, Mumbai - 400 012, Maharashtra, India.
E-mail: cspramesh@gmail.com

Access this article online

Quick Response Code:



Website:

www.ijmpo.org

DOI:

10.4103/0971-5851.166764

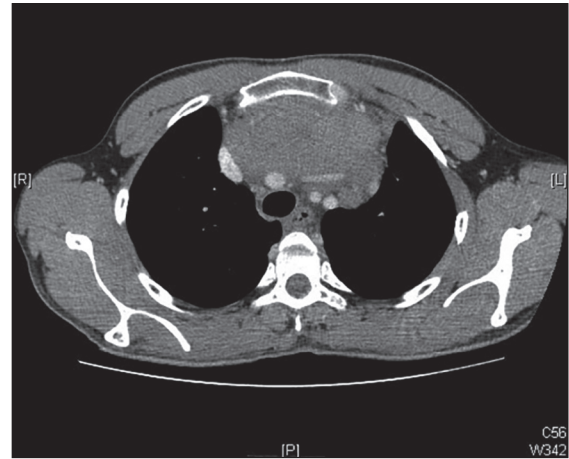


Figure 1: Anterior mediastinal mass encasing arch aorta, left brachiocephalic vein, and compressing superior vena cava

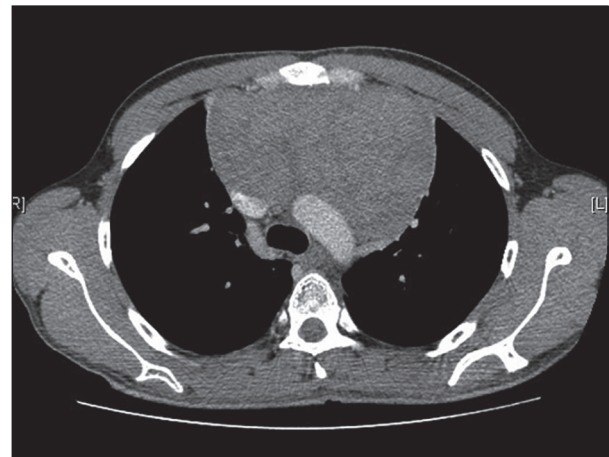


Figure 2: Static disease post chemoradiotherapy

This is an open access article distributed under the terms of the Creative Commons Attribution-NonCommercial-ShareAlike 3.0 License, which allows others to remix, tweak, and build upon the work non-commercially, as long as the author is credited and the new creations are licensed under the identical terms.