

Isolated bone marrow carcinomatosis: A rare presentation of poorly differentiated adenocarcinoma of the stomach in a young male

A 30-year-old man came with complaints of generalized body pain, fatigability, dyspepsia, anorexia, weight loss, and exertional breathlessness for 6 months with no history of chronic illness, addiction or blood loss from any site in body. His vitals were stable. The conjunctiva was pale. Lymph nodes were not enlarged. Hemogram showed bicytopenia with hemoglobin of 4.2 g/dL, leukocytes 15,500/mm³ and platelets of 62,000/mm³. The peripheral blood film showed leukoerythroblastic picture. The bone marrow biopsy revealed infiltration with malignant cells [Figure 1a, and b]. Gastroscopy showed an ulcerated hypertrophic mass lesion along the greater curvature of the stomach (3 cm × 3 cm). Histology of the gastric tissue showed poorly differentiated adenocarcinoma of the stomach, which stained positive for pan-cytokeratin applied with immunohistochemistry [Figure 1c and d]. The liver was normal on contrast enhanced computerized tomography. The serum alkaline phosphatase (ALP) value was 220 IU/L, serum lactate dehydrogenase (LDH), 250 IU/L, and serum calcium was 9.2 mg/dL. The liver and renal function tests, serum carcinoembryonic antigen, carbohydrate antigen-19-9, and coagulation profile was within normal limit. He tested negative for HIV, hepatitis B virus, hepatitis C virus, and coombs test. The chest X-ray, electrocardiogram, colonoscopy, digital X-ray of spine and echocardiogram were normal. He expired after 50 days of admission on supportive treatment in the form of blood product transfusion.

The solid malignancies which commonly metastasise to bone marrow are breast, prostate, and rarely gastric cancer. The patients with bone marrow metastasis of gastric cancer are often younger and present with refractory anemia, cytopenias, elevated ALP, LDH, osteolytic lesions, and lower incidence of hypercalcemia with poorly differentiated adenocarcinoma being most common type. To conclude, case presenting with leukoerythroblastic picture on peripheral blood film, should be evaluated for the infiltrative pathology of the bone marrow. Isolated bone marrow carcinomatosis of poorly differentiated gastric adenocarcinoma in a young male is rare and associated with poor prognosis.

Financial support and sponsorship

Nil.

Conflicts of interest

There are no conflicts of interest.

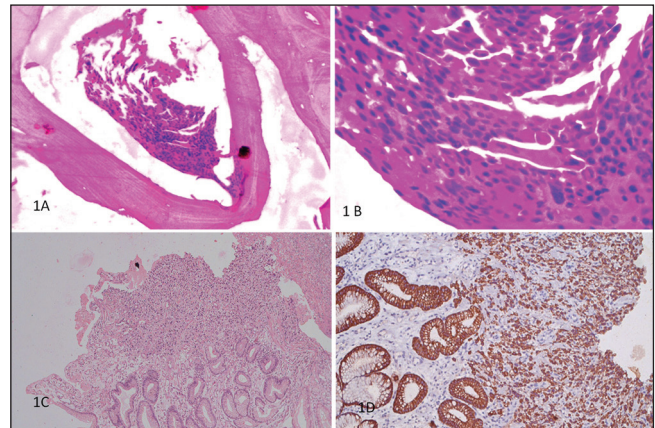


Figure 1: (a) Bone marrow biopsy showing infiltration of malignant cells on $\times 10$; (b) On $\times 40$; (c): Histopathological examination of the gastric tissue showed poorly differentiated adenocarcinoma of the stomach on $\times 20$; (d): These cells stained positive for pan-cytokeratin applied with immunohistochemistry on $\times 20$

*Manoj Lakhotia, Hans Raj Pahadiya, Ronak Gandhi,
Akanksha Choudhary, Ramesh Chand Purohit',
Sukhdev Choudhary*

*Department of Medicine, Dr. Sampurnanand Medical
College, Department of Pathology, 'Rudraksh Histopath Lab,
Jodhpur - 342 001, Rajasthan, India.*

Address for correspondence:

Dr. Hans Raj Pahadiya,
Department of Medicine, Dr. Sampurnanand Medical College,
Jodhpur - 342 001, Rajasthan, India.
E-mail: drhans05sms@gmail.com

This is an open access article distributed under the terms of the Creative Commons Attribution-NonCommercial-ShareAlike 3.0 License, which allows others to remix, tweak, and build upon the work non-commercially, as long as the author is credited and the new creations are licensed under the identical terms.

Access this article online

Quick Response Code:



Website:
www.ijmpo.org

DOI:
10.4103/0971-5851.177040

How to cite this article: Lakhotia M, Pahadiya HR, Gandhi R, Choudhary A, Purohit RC, Choudhary S. Isolated bone marrow carcinomatosis: A rare presentation of poorly differentiated adenocarcinoma of the stomach in a young male. *Indian J Med Paediatr Oncol* 2016;37:67.