

# Juvenile granulosa cell tumor associated with Ollier disease

Abhilasha Ashok Sampagar,

Rahul R. Jahagirdar,

Vibha Sanjay Bafna,

Sandip P. Bartakke

Department of Pediatrics, Division of Pediatric Oncology, Bharati Vidyapeeth Medical College and Hospital, Pune, Maharashtra, India

## Address for correspondence:

Dr. Abhilasha Sampagar,  
Department of Pediatrics,  
Bharati Hospital, 3<sup>rd</sup> Floor,  
Katraj, Dhanakwadi, Pune,  
Maharashtra, India.  
E-mail: abhilasha.pedia@gmail.com

## ABSTRACT

Juvenile granulosa cell tumor (JGCT) is a rare neoplasm of childhood. Interestingly, it is known to be associated with Ollier disease, which is a rare bone disease characterized by multiple enchondromatosis. There is paucity of literature about the co-occurrence of these two conditions. However, this association is noteworthy because these two conditions share a common pathogenesis. We report a case of JGCT in a 2.5-year-old female child in which multiple enchondromas mimicking bony metastasis were an incidental finding during routine workup for tumor staging, thus leading to a diagnosis of Ollier disease.

**Key words:** *Enchondroma, juvenile granulosa cell tumor, Maffucci syndrome, Ollier disease*

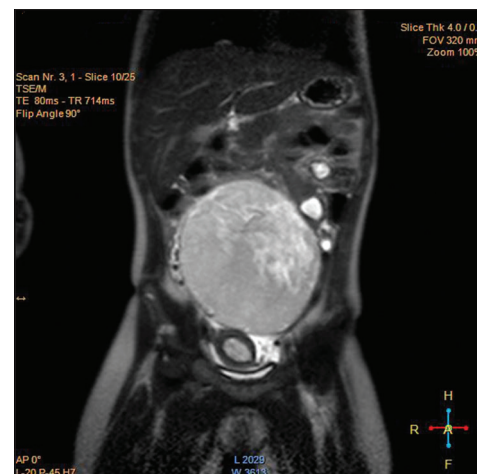
## INTRODUCTION

Ovarian juvenile granulosa cell tumor (JGCT) is an extremely rare sex cord-stromal tumor of the ovary that accounts for 2%–5% of malignant ovarian neoplasms.<sup>[1]</sup> Its association with Ollier disease has rarely been described in the literature.<sup>[2]</sup> Enchondromatosis or Ollier disease, which has an estimated prevalence of 1 in 100,000, is a condition of mesodermal dysplasia characterized by the derangement of cartilaginous growth resulting in incorporation of fragments of the epiphyseal plate within mature bone which subsequently develop into multiple enchondromas within the metaphysis.<sup>[3]</sup> When enchondromatosis is associated with hemangiomas or lymphangiomas, then the condition is known as Maffucci syndrome.<sup>[4,5]</sup> Chondrosarcoma is a frequently encountered malignancy in Ollier disease with an estimated risk of 30%–50%, but its association with JGCT draws attention toward the fact that there is a generalized mesodermal dysplasia in patients with enchondromatosis.<sup>[6,7]</sup> This case report is an attempt to address the fact that patients with Ollier disease should be screened for mesodermal neoplasms.

## CASE REPORT

A 2.5-year-old female child presented with precocious puberty. Sexual maturity rating by tanner staging was Stage 2. On abdominal palpation, a hard mass was felt in the right hypochondrium. Magnetic resonance imaging (MRI) of abdomen and pelvis revealed a well-defined right ovarian mass measuring 10 cm × 5 cm × 11 cm with cystic and

necrotic areas [Figure 1]. Another incidental finding noted on T2-weighted MRI study was multiple small lobulated foci of increased signal intensity separated by a background mesh of decreased signal intensity in the right femoral neck, greater and lesser trochanter, and the right iliac blade which were reported as metastatic lesions. These incidental MRI findings were correlated with the skeletal radiographs which showed expansile lytic lesions with thinning of the cortex [Figure 2]. No other site apart from



**Figure 1:** Ovarian tumor with multiple small lobulated foci of increased signal intensity in the right femur

This is an open access article distributed under the terms of the Creative Commons Attribution-NonCommercial-ShareAlike 3.0 License, which allows others to remix, tweak, and build upon the work non-commercially, as long as the author is credited and the new creations are licensed under the identical terms.

**For reprints contact:** reprints@medknow.com

**How to cite this article:** Sampagar AA, Jahagirdar RR, Bafna VS, Bartakke SP. Juvenile granulosa cell tumor associated with Ollier disease. *Indian J Med Paediatr Oncol* 2016;37:293-5.

## Access this article online

### Quick Response Code:



Website:  
www.ijmpo.org

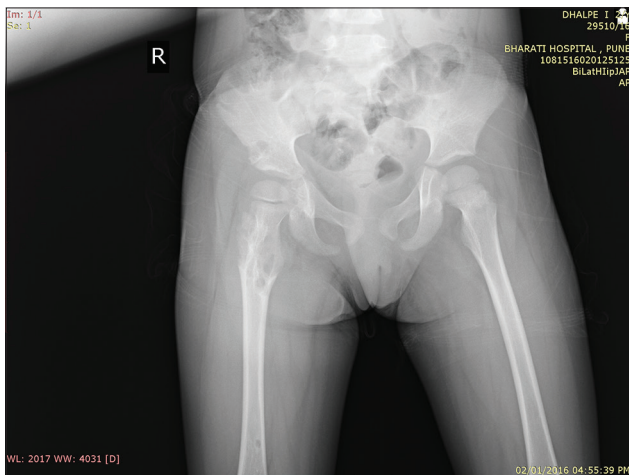
DOI:  
10.4103/0971-5851.195749

those seen in the MRI was involved, thus confirming the unilateral distribution of the lesions. The ovarian tumor was surgically removed [Figure 3]. Tumor microscopy revealed macrofollicles lined by 2–3 layers of granulosa cells. The islands of granulosa cells showed Call-Exner bodies [Figure 4]. Tumor cells expressed inhibin, calretinin, melan-A (focal), and cytokeratin. Although the tumor was well localized but peritoneal aspirate was positive for malignant cell but the omental biopsy specimen was not involved. Thus, the diagnosis of JGCT 1C3 (as per new FIGO staging) was established. Bone scan was done to confirm metastasis, but there was no evidence of osteoblastic skeletal metastasis. She was further subjected to biopsy of the bone lesions to find out the nature of lytic lesions. The biopsy specimen contained cartilaginous elements which were reported as enchondromas [Figure 5]. Hence, the final diagnosis was Ollier disease with JGCT. A significant regression of the breast size and pubic hair was noted few weeks after the surgery. The patient was

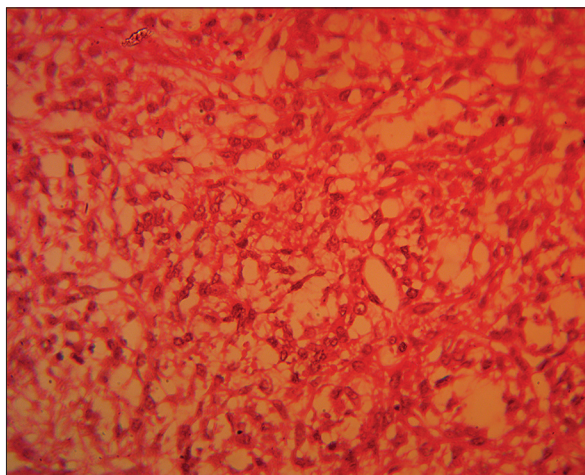
put on chemotherapy as per germ cell tumor protocol, and parents were counseled about the risk for the development of chondrosarcoma and the need for regular follow-up.

## DISCUSSION

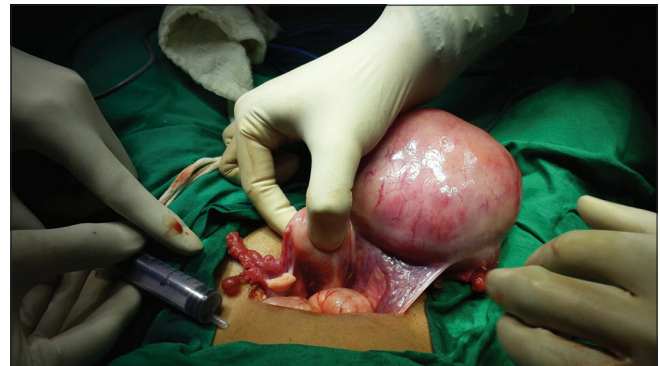The present case describes unusual association of two rare conditions. Ollier disease is a nonfamilial disorder.<sup>[8]</sup> There are very few case reports of this association, and these enchondromas were an incidental finding. According to the literature, the mean age of presentation of JGCT is 13 years.<sup>[9]</sup> The common clinical manifestation of Ollier disease is limb length discrepancy due to its characteristic involvement of one hemiskeleton or enchondromas in the phalanges and metacarpals.<sup>[10]</sup> However, in our case, Ollier disease was diagnosed on the basis of imaging and biopsy findings, even though the patient had not developed the clinical manifestation of the disease. Although this is an unusual association it emphasizes generalized mesodermal dysplasia in enchondromatosis and points toward the risk of development of ovarian neoplasms in addition to the commonly encountered chondrosarcomas which usually manifest in the second decades of life.<sup>[8]</sup> Another very interesting aspect of this case was maternal history of intake of ovulation-inducing drugs for a prolonged period



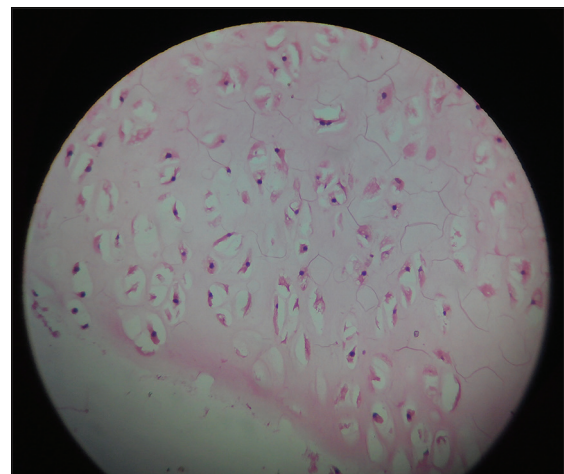
**Figure 2:** Lytic lesions in the right femur in the X-ray



**Figure 4:** High-power view of the granulosa cells with call-exner bodies (granulosa cells tend to form primitive follicle seen as empty spaces between granulosa cells)



**Figure 3:** Surgical removal of the ovarian tumor



**Figure 5:** Enchondromas

of 2 years as a part of infertility treatment before this conception. Hence, this case supports the fact that intake of estrogen containing compounds is an etiological factor for the development of granulosa cell tumors.<sup>[11]</sup>

#### Financial support and sponsorship

Nil.

#### Conflicts of interest

There are no conflicts of interest.

#### REFERENCES

1. Kottarathil VD, Antony MA, Nair IR, Pavithran K. Recent advances in granulosa cell tumor ovary: A review. *Indian J Surg Oncol* 2013;4:37-47.
2. Tamimi HK, Bolen JW. Enchondromatosis (Ollier's disease) and ovarian juvenile granulosa cell tumor. *Cancer* 1984;53:1605-8.
3. Fletcher CD, Unni KK, Mertens F. World Health Organization Classification of Tumours: Pathology and Genetics of Tumours of Soft Tissue and Bone. Lyon, France: IARC Press; 2002.
4. Auyeung J, Mohanty K, Tayton K. Maffucci lymphangioma syndrome: An unusual variant of Ollier's disease, a case report and a review of the literature. *J Pediatr Orthop B* 2003;12:147-50.
5. Yuan JQ, Lin XN, Xu JY, Zhu J, Zheng WL. Ovarian juvenile granulosa cell tumor associated with Maffucci's syndrome: Case report. *Chin Med J (Engl)* 2004;117:1592-4.
6. Horvai A, Unni KK. Premalignant conditions of bone. *J Orthop Sci* 2006;11:412-23.
7. Bükte Y, Necmioglu S, Nazaroğlu H, Kilinc N, Yılmaz F. A case of multiple chondrosarcomas secondary to severe multiple symmetrical enchondromatosis (Ollier's disease) at an early age. *Clin Radiol* 2005;60:1306-10.
8. Silve C, Jüppner H. Ollier disease. *Orphanet J Rare Dis* 2006;1:37.
9. Heo SH, Kim JW, Shin SS, Jeong SI, Lim HS, Choi YD, *et al.* Review of ovarian tumors in children and adolescents: Radiologic-pathologic correlation. *Radiographics* 2014;34:2039-55.
10. Khoo RN, Peh WC, Guglielmi G. Clinics in diagnostic imaging (124). Multiple enchondromatosis in Ollier disease. *Singapore Med J* 2008;49:841-5.
11. Frazier AL, Billmire D, Amatruda J. Pediatric germ cell tumors. In: Orkin SH, Fisher DE, Ginsburg D, Look AT, Lux SE, Nathan DG, editors. *Nathan and Oski's Hematology and Oncology of Infancy and Childhood*. 8<sup>th</sup> ed. Philadelphia: Elsevier Saunders; 2015. p. 2056-98.