

Squamous Cell Carcinoma *In situ* of the Cervix with Superficial Intraepithelial Extension to the Endometrium of Lower Uterine Segment: A Rare Presentation

Abstract

Carcinoma of the cervix is the most common malignancy in women in India. Squamous cell carcinoma accounts for more than 70% of the cervical malignancies. Carcinoma of the cervix generally invades the uterine wall by direct extension with or without parametrial involvement, however, rarely can spread superficially to the inner surface of the uterus replacing the endometrium. It is an uncommon phenomenon for an *in situ* lesion of the cervix to have contiguous superficial spread to the endometrium. We report a case of cervical *in situ* squamous cell carcinoma in a 45-year-old female with contiguous extension to the endometrium of the lower uterine segment.

Keywords: Carcinoma *in situ*, carcinoma of cervix, CD138, lower uterine segment, superficial spreading

Introduction

Carcinoma of cervix is the most common gynecological malignancy caused by persistent infection with carcinogenic types of human papilloma virus (HPV). The proportion with squamous histology is around 70%. Cervical squamous cell carcinoma can directly invade the uterine wall with or without parametrial involvement or by lymphatic invasion. Direct extension to the endometrium replacing it without myometrial invasion is very uncommon.^[1] A case of carcinoma *in situ* of cervix with contiguous extension to the endometrium of the lower uterine segment is reported hereby with emphasis on immunohistochemistry.

Case Report

A 45-year-old female (para three, live three) presented with lower abdominal pain and excessive bleeding per vaginam. She got married at the age of 18 years and has three full-term spontaneous vaginal deliveries. Her first child was born at the age of 20 years. There was no significant past medical or surgical history. She has not undergone cervical smear examination until now. Pelvic examination revealed a firm cervix. Ultrasound imaging revealed

a small myoma in the anterior wall. With the provisional clinical diagnosis of myoma uterus, total abdominal hysterectomy with bilateral salpingectomy was performed. On gross examination, the uterus and cervix measured 9 cm × 5 cm × 4 cm with granular appearance of ectocervix. The endometrial surface was thin and smooth.

Microscopically, the ectocervix was lined by squamous epithelium with full thickness dysplasia with nuclear atypia, loss of polarity, and hyperchromasia [Figure 1a]. Basement membrane was lost in some foci. Invasion into the stroma beneath or stromal desmoplasia was not seen. There was contiguous extension of the dysplastic squamous epithelium into the lower uterine segment replacing the endometrium [Figure 1b]. There was no myometrial invasion. Endometrium lining the uterine body, and the fallopian tubes were free of tumor spread. Leiomyoma was identified in the anterior myometrium.

Immunohistochemical analysis with CD138 revealed strong and diffuse expression in the dysplastic squamous epithelium in the cervix [Figure 1c] and in the lower uterine segment [Figure 1d] in its full thickness including the basal layers.

Rajeshwari K Muthusamy, Sangita S Mehta

From the Department of Pathology, Kovai Medical Center and Hospital, Coimbatore, Tamil Nadu, India

Address for correspondence:

Dr. Rajeshwari K Muthusamy, Department of Pathology, Kovai Medical Center and Hospital, Coimbatore - 641 014, Tamil Nadu, India.
E-mail: drrajipranav@gmail.com

Access this article online

Website: www.ijmpo.org

DOI: 10.4103/0971-5851.203509

Quick Response Code:



How to cite this article: Muthusamy RK, Mehta SS. Squamous cell carcinoma *in situ* of the cervix with superficial intraepithelial extension to the endometrium of lower uterine segment: A rare presentation. Indian J Med Paediatr Oncol 2017;38:88-9.

This is an open access article distributed under the terms of the Creative Commons Attribution-NonCommercial-ShareAlike 3.0 License, which allows others to remix, tweak, and build upon the work non-commercially, as long as the author is credited and the new creations are licensed under the identical terms.

For reprints contact: reprints@medknow.com

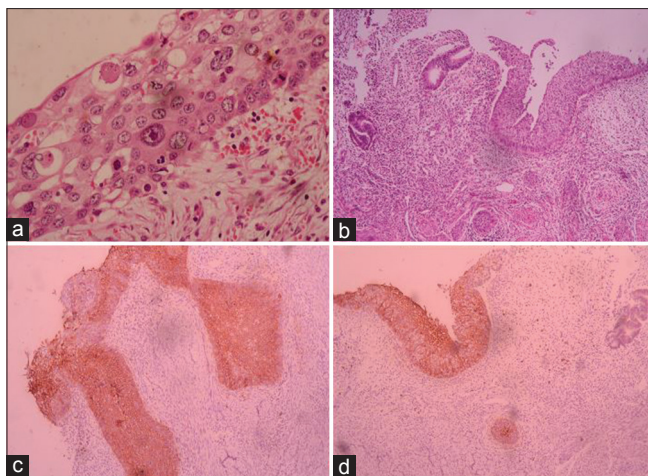


Figure 1: (a) Cervical intraepithelial neoplasia III of the uterine cervix with nuclear atypia ($\times 100$). (b) *In situ* tumor sweeps over the endometrium of the lower uterine segment ($\times 40$). (c) Strong expression of CD138 in the cervix *in situ* tumor ($\times 40$). (d) strong expression of CD138 in the *in situ* tumor in the lower uterine segment ($\times 40$)

Discussion

Squamous cell carcinoma of cervix is the most common tumor of the female genital tract, accounting for about 70% of the cervical malignancies.^[2] Cervical carcinoma spreads generally upward to the parametrium and through lymphatic invasion to the uterine wall. The presence of squamous cell carcinoma *in situ* of the cervix with squamous carcinoma *in situ* of the endometrium of the lower uterine segment suggests a superficial spread of carcinoma cells originating from the cervical mucosa. Although initial studies cited the role of radiation in pathogenesis,^[3] the present studies found monoclonal neoplasia originating from the cervical mucosa with loss of heterozygosity analysis.^[4] The superficial spread of cancer to the endometrium may be evident on gross examination as “cake icing” or “Zukerguss” where the tumor sweeps over to replace the endometrium.^[1]

The clinicopathological features of the previously described cases of superficial spreading carcinoma of cervix revealed older age at presentation with various predisposing factors, such as early marriage, early first sexual intercourse, multiparity, and HPV infection. Few of these factors were seen in our patient as well.

The histology of the cervical neoplasia in the previously reported cases was ranging from squamous cell carcinoma *in situ*, microinvasive squamous cell carcinoma, invasive squamous cell carcinoma to adenosquamous carcinoma. Although contiguous spread of tumor was restricted to the endometrium, few studies reported spread of tumor to the fallopian tube and or ovaries as well.^[1,5,6] Moreover, the pattern of tumor spread in the endometrium was either *in situ* as in our case or with invasive component in contiguous with the cervical malignancy.

In our case, the age at presentation was 5 years earlier to those described in literature with early marriage, early

first sexual intercourse, and multiparity. Ishida and Okabe demonstrated strong expression of CD138 in carcinoma cells that participate in superficial spreading by regulating cell to cell interactions while cells in the invasive focus lack CD138 expression.^[7] CD138 in our case also showed intense expression of the *in situ* component in the cervix and lower uterine segment without loss of expression in the deeper layers of the epithelium.

Conclusion

The superficial spread of squamous cell carcinoma *in situ* of cervix to the endometrium is a rare event, with few cases reported in the literature. The International Federation of Gynaecology and Obstetrics staging has not included such an entity in the staging of cancer cervix. The World Health Organization in its classification of tumors of the cervix has not described such a phenomenon. The prognostic significance and management guidelines for such type of unusual spread of carcinoma cervix are also lacking. It is hoped that the increase in reporting of such rare phenomenon will help in recognition of this entity with etiopathogenesis and formulating the management guidelines.

Financial support and sponsorship

Nil.

Conflicts of interest

There are no conflicts of interest.

References

1. Agashe SR, Kulkarni MP, Momin YA, Sulhyan KR. Superficial extension of squamous cell carcinoma *in situ* of cervix involving endometrium, bilateral fallopian tubes and ovaries: A case report. *Indian J Pathol Microbiol* 2007;50:375-7.
2. Tan GC, Isa MR, Ng SP, Jamil YM. Unusual form of superficial spreading microinvasive squamous cell carcinoma of uterine cervix involving the endometrium of uterus. *J Obstet Gynaecol Res* 2004;30:363-7.
3. Gupta S, Gupta IM, Tiwari PV. *In-situ* carcinoma of the uterine cervix showing superficial endometrial spread. *Acta Obstet Gynecol Scand* 1979;58:507-8.
4. Kushima M, Fujii H, Murakami K, Ota H, Matsumoto T, Motoyama T, *et al.* Simultaneous squamous cell carcinomas of the uterine cervix and upper genital tract: Loss of heterozygosity analysis demonstrates clonal neoplasms of cervical origin. *Int J Gynecol Pathol* 2001;20:353-8.
5. Pins MR, Young RH, Crum CP, Leach IH, Scully RE. Cervical squamous cell carcinoma *in situ* with intraepithelial extensions to the upper genital tract and invasion of tubes and ovaries: Report of a case with human papilloma virus analysis. *Int J Gynecol Pathol* 1997;16:272-8.
6. Gungor T, Altinkaya SO, Ozat M, Akbay S, Mollamahmutoglu L. Unusual form of superficial spreading squamous cell carcinoma of cervix involving the endometrium, bilateral tubes and ovaries: A case report with literature review. *Arch Gynecol Obstet* 2011;283:323-7.
7. Ishida M, Okabe H. Superficial spreading squamous cell carcinoma of the uterine cervix involving the endometrium: Report of two cases with emphasis on the likely molecular mechanism. *Oncol Lett* 2013;5:31-4.