

Pediatric Osteosarcoma: An Updated Review

Abstract

Osteosarcoma (OS), the most common type of primary malignant bone tumor, is defined by the presence of malignant mesenchymal cells producing osteoid or immature bone. The peak incidence of the most frequent type of OS, i.e., high-grade central OS, occurs in the second decade of life during the adolescent growth spurt. Most patients suffer from the pain and swelling in the involved region and, usually, seek medical attention. Diagnosis is carried out by conventional radiographs, computed tomography, and magnetic resonance image (MRI). In addition, three-phase bone scans, thallium scintigraphy, dynamic MRI, and positron emission spectroscopy are new innovative promising tools. OS can be treated with surgery, radiotherapy, and chemotherapy. There is a clear need for newer effective agents for patients with OS, especially for patients who afflicted with metastatic and recurrence tumor. Monoclonal antibodies directed against OS may prove useful as treatment, either for drug delivery or for radiopharmaceuticals.

Keywords: Bone tumor, childhood malignancy, musculoskeletal tumor, osteosarcoma, radioresistance

Introduction

Malignant tumors that arise in tissues such as the bones, cartilage, and muscle are called sarcoma. Osteosarcoma (OS), the most common type of primary malignant bone tumor, is defined by the presence of malignant mesenchymal cells producing osteoid or immature bone. It accounts for 30%–80% of the primary skeletal sarcomas and is the most common bone malignancy.^[1] The population affected is predominantly children, teenagers, and young adults aged 10–30 years.^[2] Males are more affected than females. The peak incidence of the most frequent type of OS, i.e. high-grade central OS, is occurring in the second decade of life during the adolescent growth spurt. If left untreated, OS may run a relentless course with local and systemic disease progression and leads to death within a matter of months. The outcome for patients with OS was poor before the use of effective chemotherapy, with 2-year overall survival rates of 15%–20% following surgical resection and/or radiotherapy.^[3]

Epidemiology

In general, bone tumors in children are rare, with an estimated 8.7 per million in children

younger than 20 years of age,^[4] representing 650–700 new bone cancer patients a year. OS has a bimodal age distribution, with a first peak during the second decade of life (during the adolescent growth spurt; modal age: 16 years in girls and 18 years in boys) and the second peak in older adults. Boys are reported to be affected more frequently in most series, and the incidences of OS in African-American children are slightly higher than that in Caucasians. It is extremely rare before 5 years of age. At initial diagnosis, 15%–20% patients present with overt lung metastases whereas 40% patients develop metastases at a later stage. Based on the clinical outcomes of patients without overt metastasis at diagnosis during the prechemotherapy area, approximately 90% of patients developed lung metastasis 6–36 months later. It is presumed that the vast majority of apparently nonmetastatic patients actually have the micrometastatic disease at diagnosis. It originates more frequently in the metaphyseal region of tubular long bones, with 42% occurring in the femur, 19% in the tibia, and 10% in the humerus. About 8% of all cases occur in the skull and jaw, and another 8% in the pelvis.^[4]

The incidence of childhood cancer in the world ranges from 75 to 150 per million children per year.^[5] However, the reported

**Shachi Jain Taran,
Rakesh Taran¹,
Nagraj B Malipatil²**

From the Departments of Pediatrics, ¹Medical Oncology, Sri Aurobindo Medical College and Postgraduate Institute, Indore, Madhya Pradesh, ²Clinical Pharmacologist, Bangalore, Karnataka, India

Address for correspondence:

*Dr. Rakesh Taran,
Department of Medical
Oncology, Sri Aurobindo
Institute of Medical Sciences,
Sanwar Road, Indore - 452 015,
Madhya Pradesh, India.
E-mail: rakeshtaran@yahoo.
com*

Access this article online

Website: www.ijmpo.org

DOI: 10.4103/0971-5851.203513

Quick Response Code:



How to cite this article: Taran SJ, Taran R, Malipatil NB. Pediatric osteosarcoma: An updated review. *Indian J Med Paediatr Oncol* 2017;38:33-43.

This is an open access article distributed under the terms of the Creative Commons Attribution-NonCommercial-ShareAlike 3.0 License, which allows others to remix, tweak, and build upon the work non-commercially, as long as the author is credited and the new creations are licensed under the identical terms.

For reprints contact: reprints@medknow.com

age of the standardized incidence rate for India ranges from 38 to 124 per million children per year [Table 1]. The highest incidence is reported from Chennai and the lowest from rural Ahmedabad. OS and germ cell tumor have a slight female preponderance in India.^[5]

Pathology

In most patients, the etiology of OS remains obscure. The predilection of OS for the age of the pubertal growth spurt and the sites of maximum growth suggests a correlation with rapid bone proliferation. A minority of OSs is caused by radiation exposure. It takes approximately 10–20 years after receiving radiotherapy to develop OS, so radiation-related instances are more common in adults. Exposure to alkylating agents may also contribute to OS development.^[6]

High-grade OS is most likely derived from mesenchymal stem cells with at least partial osteoblastic lineage commitment although the exact cell of origin is unclear.^[6] Patients with hereditary retinoblastoma, Rothmund–Thomson syndrome, Li-Fraumeni syndrome, and Werner syndrome are predisposed to the development of the OS, suggesting that alterations in the genes associated with these disorders (RB1, RECQL4, TP53, and WRN, respectively) may play a role in the pathogenesis of OS [Table 1].^[7] However, the vast majority of OSs arises in patients with no known germline abnormalities. A wide variety of serological markers has been associated with pediatric OS [Table 2]. These may be broadly divided into several groups. Markers are most commonly grouped by chemical structure or by the biological function they have in the organism.^[8-10] Chemically, markers can be divided into glycoproteins, polypeptides, carbohydrate determinants of glycoproteins, glycolipids, proteins, polyamines, and immunoglobulins.^[11-14] In terms of biological function, markers can be divided into oncofetal antigens, enzymes, hormones, receptors, and compounds with an yet unclear function.^[15-17] Tumor markers involved in angiogenesis, cell adhesion, apoptosis, and the cell cycle have been shown recently to play an important role in OS growth, differentiation, and metastasis.^[18-21] Over the coming years, the new markers may be able to prognosticate pediatric OS patients at baseline as well as to serve as therapeutic

targets and thereby further improve survival rates.^[22-24] No OS-specific marker, more particularly pediatric OS-specific marker, has been found thus far, so where lies the future of pediatric OS biomarker research? At the cytogenetic level, OSs have highly complex karyotypes with many numerical and structural abnormalities; a consistent cytogenetic abnormality has not been identified.^[25] Three major subtypes of conventional OS are recognized: Osteoblastic, chondroblastic, and fibroblastic reflecting the predominant form of tumor matrix.^[25] Treatment and outcome of these subtypes are not different. Parosteal OS, central low-grade OS, and periosteal OS are morphologically and clinically distinct OS subtypes with an improved prognosis and constitute <5% of cases of OS.^[26,27] The age at presentation for parosteal and periosteal OS is usually in the fourth and fifth decades of life (patients are usually in the 30–40 years age range). The microscopic diagnosis of OS rests on the identification of production of the osteoid matrix by the neoplastic cells [Figure 1]. There are no ancillary immunohistochemical or molecular genetic studies that are of value in the diagnosis of OS.^[26]

Clinical Features

Most patients with OS present with pain and swelling in the involved region and usually seek medical attention

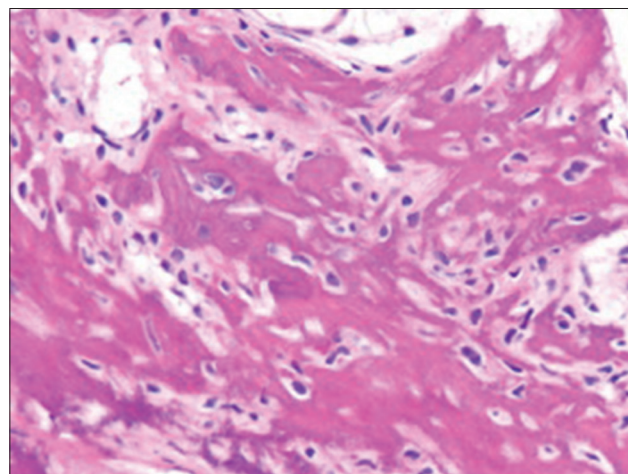


Figure 1: Photomicrograph of osteosarcoma showing production of lacelike neoplastic osteoid by hyperchromatic spindle cells

Table 1: Genetic alterations in osteosarcoma

Gene	Percentage affected	Tumor suppressors	References
Tumor suppressors			
p53	20-50 (or more)	Li-Fraumeni	McIntyre <i>et al.</i> , Lonardo <i>et al.</i> , Gokgoz <i>et al.</i> , Hauben <i>et al.</i>
Rb	Up to 70	Retinoblastoma	Eng <i>et al.</i>
p16INK4A/p14ARF	~10%	Dysplastic nevus syndrome	Lopez-Guerrero <i>et al.</i> , Shimizu <i>et al.</i>
Oncogenes			
MDM2	6-14	SNP309 of MDM2 have accelerated tumor formation	Bond <i>et al.</i>
AP-1 (c-jun/c-fos)	40-60 for both c-fos and c-jun	None known	David <i>et al.</i>
Notch	Unknown	No	Engin <i>et al.</i>

Table 2: List of candidate serum markers for pediatric osteosarcoma and their possible clinical utility

Serum marker	Observation for POS	Assessed clinical utility for POS	References
Free polyamines	POS development is accompanied by disorders of polyamine metabolism spurring their intensive release from cells into biological fluids	Informative indicator of a malignant process in POS	Ladanyi <i>et al.</i>
IGF-1 and IGFBP-3	IGF-1/IGFBP-3 levels correlate with the presence of metastatic disease, histologic response, event-free survival	Promising predictive factor of development or clinical characteristics of POS	Rodriguez-Galindo <i>et al.</i>
Anti-ki57 antibody	Increased levels anti-ki57 antibody associated with extent of biological activity of tumor and clinical course of POS	Prognostic factor for POS progression	Petrosyan <i>et al.</i>
TNF- β and sTNF-R	In high-grade POS, high levels of TNF- β correlated with bad response to neoadjuvant chemotherapy	Marker for monitoring of response to neoadjuvant chemotherapy in POS	Holzer <i>et al.</i>
ANG	Expression of ANG correlates with an increase in local density of blood vessels in tumor tissue, with development of pulmonary metastasis and poor prognosis	Diagnostic and prognostic factor of primary POS	Kushlinskii <i>et al.</i>
Bone formation/resorption	Decreased production of PICP, OC, ICTP associated with bone metabolism in POS	Risk factor for pathologic bone fractures in POS	Gajewska <i>et al.</i>
T3	Increased levels T3 associated with poor/good disease-free survival	Marker of good and poor POS prognosis	Sidorenko <i>et al.</i>
CD44	No significant difference was observed between serum CD44 levels of children with sarcoma and healthy children	Serum CD44 levels were not found to be of value in diagnosis or prognosis for POS	Kebudi <i>et al.</i>
VEGF	Increased VEGF levels correlates with tumor stage and disease-free survival	Prognostic factor in POS	Koznetsova <i>et al.</i>
SAA	Increased SAA levels associated with type of tumor and high-risk POS development	Differentiates malignant bone cancer from benign bone tumors and detects POS in high-risk children	Krizkova <i>et al.</i>
BALP	Increased BALP levels associated with development of POS	Marker for late detecting, monitoring, and assessment of the efficacy of therapy in POS	Ambroszkiewicz <i>et al.</i>
CXC chemokines	Increased CXCL4, CXCL6, and CXCL12 levels associated with poor disease-free survival	Prognostic factor for POS outcomes	Li <i>et al.</i>
IL-2, IL-4, IL-8, IFN- γ , TNF- α	Analysis of cytokine concentration showed large statistically significant differences between POS and control group for IL-4 and IL-8	Markers for individual reaction of organism to the development of POS	Markiewicz <i>et al.</i>

Source: Savitskaya, *et al.* Clin Sarcoma Res 2012;2:9. POS – Pediatric osteosarcoma; TNF – Tumor necrosis factor; VEGF – Vascular endothelial growth factor; SAA – Serum amyloid A; IL – Interleukin; BALP – Bone alkaline phosphatase; OC – Osteocalcin; PICP – Propeptide of type I collagen; IFN – Interferon; IGF-1 – Insulin-like growth factor 1; IGFBP-3 – IGF binding protein-3; sTNF-R – Soluble TNF-receptor; ANG – Angiogenesis

following trauma or vigorous physical exercise, both of which are common in this population.^[28] Patients generally have symptoms for several months (average, 3–4 months, but frequently exceeding 6 months) before a diagnosis is made. The pain is constant and tends to worsen over time. The patients may have limps due to the pain when bearing weight. However, in the early stages, the tumor cannot be palpated and may not even show up on X-ray images.

If the pain is in a recently traumatized area, the diagnosis can be delayed because the pain is attributed to the trauma. Unless the force was significant, for instance, enough to cause a fracture, most pain due to trauma will get better with time. However, if the pain worsens over the next few weeks, OS may be suspected. If the patient has normal body temperature, but the tender area is warming, swollen, and has a larger diameter than the other side, this means that the tumor is significantly enlarged. The area with the

tumor is brittle, which can cause fractures and acute pain. Although OS can occur in any bone, it is most common in the metaphysis of long bones. The most common primary sites are the distal femur, proximal tibia, and proximal humerus, with approximately 50% of cases originating around the knee area.^[28] However, OS can also occur in the axial skeleton (<10% of cases in the pediatric age group), most commonly the pelvis.^[28] Plain X-rays, bone scans, and magnetic resonance images (MRIs) are all necessary for diagnosis. The diagnosis is confirmed by a biopsy of the lesion. Approximately 15%–20% of patients present with radiographically detectable metastases.^[29] However, since about 80% of patients with localized OS develop metastatic disease following surgical resection,^[29] virtually all patients are presumed to have subclinical, microscopic metastases.^[29] The most frequent site for metastatic presentation is the lung.^[30] Plain X-rays of the chest may not show small lesions, so a chest computed tomography (CT) is necessary to rule out metastases. Respiratory symptoms only develop with extensive involvement. However, metastases can also occur in other bones and soft tissues.^[30] Arguably, presentations with multiple bone metastases may actually represent multifocal primary tumors. When OS is widely metastatic, more frequently at recurrence than at the time of initial diagnosis, it can spread to the central nervous system or other sites. Death from OS is usually the result of progressive pulmonary metastasis with respiratory failure due to widespread disease.^[30]

The evaluation of a patient with suspected OS begins with a full history, physical examination, and plain radiographs. The history is usually remarkable for the presence of pain and swelling at the primary tumor site. The presence of pain at other sites may suggest the presence of metastatic involvement. Physical examination usually reveals a soft-tissue mass at the primary tumor site, and laboratory workup is seldom remarkable except for elevations of alkaline phosphatase and lactate dehydrogenase, which have been reported with prognostic significance.^[31]

Management

Surgery

The goal of OS surgery must always be complete tumor removal. Margins should be at least wide, according to Enneking's definition [Table 3],^[32] meaning that the tumor, including the biopsy scar, has to be removed surrounded by an inviolate cuff of healthy tissue. Advances in imaging techniques, and in biomedical engineering, as well as the positive effects of preoperative chemotherapy have led to a major shift away from amputation toward limb salvage surgery.^[32] Options for reconstruction after limb-sparing tumor resections are manifold and include endoprosthetic devices, biological reconstruction, or a combination of both. Rotationplasty, another well-established biological reconstruction method for tumors around the knee, can result in functional and psychological outcomes equal or

Table 3: Enneking's criteria for surgical margins in musculoskeletal tumors

Margin	Dissection
Intralesional	Within the lesion
Marginal	Through the pseudocapsule or reactive tissue
Wide	Lesion (including biopsy scar), pseudocapsule and/or reactive zone, and an unviolated cuff of normal tissue completely surrounding the mass removed as a single block
Radical	Entire anatomic compartment containing the tumor removed as one block

even superior to endoprosthetic reconstruction^[32] but is cosmetically challenging.

Surgery of sarcomas of the axial skeleton remains particularly challenging, both because local recurrence poses a great hazard and because complications after reconstruction are frequent. It is essential that surgeons should aware of all surgical techniques and implement the most appropriate one for each patient after consultation within the multidisciplinary OS team. More recent advances include total *en bloc* spondylectomy for vertebral tumors and hip transposition for pelvic sarcomas.^[32]

Extracorporeal irradiation (ECI) consists of *en bloc* removal of the tumor-bearing bone part, exclusion of the tumor from the bone, irradiation, and finally reimplantation back in the body.^[33] Limb preservation surgery requires special attention to evade future limb length discrepancy in pediatric patients. ECI can effectively prevent the growth of discrepancy frequently observed in prosthetic replacement by evading resection of the normal growth plate and interstitial bone growth from surrounding healthy bones.^[34] The main benefit of ECI is the specific structural fit of reimplanted bone part and conservation of joint flexibility.^[33,34] The reimplantation of the irradiated bone averts some difficulties associated with allograft such as the accessibility of right graft from a bone bank, particularly for pediatric patients, graft rejection, and hazard of viral infection.^[34] An autograft is defined as tissue grafted into a new position in the body of the same individual.^[35] The patient's autogenous bones, such as tibia, fibula, rib, and iliac crest, may be used as optimal material for reconstruction of small resected part of bone.^[36] The best application of the autograft in pediatric patients is for vascularized fibular transplant. The method is best suitable for an intercalary long bone defect with allograft supplementation as well as for proximal humeral osteoarticular reconstruction.^[37]

Radiotherapy

OS was long considered a radioresistant tumor; thus, the experience with radiotherapy in the local treatment of OSs is limited.^[32] However, recent data suggest that the administration of radiotherapy may be useful in patients treated with multiagent chemotherapy who are unable

to undergo complete resection or who have microscopic residual tumor foci following attempted resection. Retrospective studies suggest that it may be helpful in some cases, including in those with close or positive surgical margins^[13] or in the palliative setting. High doses, including those up to 80 Gy, are thought to be required to achieve some tumor kill. Localized proton beam therapy may be useful to achieve high tumor doses and spare normal surrounding tissue for unresectable lesions.^[14] The use of targeted radiotherapy with samarium-153-ethylenediamine tetramethylene phosphonate may also be considered in selected situations. The bone-seeking isotope, samarium-153-EDTMP, may be helpful for palliation of metastases positive on bone scan findings, but this treatment requires hematopoietic stem cell rescue due to its hematologic toxicity.^[15] Although the role of this treatment modality is not well defined, its definition would require further evaluation in controlled clinical trials.^[32]

Chemotherapy

Successful treatment of OS requires the use of systemic chemotherapy. Early results following treatment with either surgery or radiation therapy provided 2-year overall survival rates of 15%–20%.^[38] Almost all patients have microscopic metastases at the time of diagnosis, as evidenced by the fact that 80%–90% develop metastatic recurrence if treated with surgical resection and/or radiotherapy.^[38] Two different studies definitively proved the need for adjuvant chemotherapy to improve outcome for patients with localized extremity OS.^[39] The most active agents include cisplatin,^[40] doxorubicin,^[41] and high-dose methotrexate,^[42] and the management of these patients involves the use of these three agents along with surgical resection with adequate margins.^[42] The best method of local control involves surgery with adequate margins since this tumor is relatively radioresistant. However, a recent study suggests that patients with microscopically positive margins following resection or those unable to undergo surgical resection may benefit from the use of high-dose radiotherapy, as evidenced by a superior outcome in that series for patients given radiotherapy compared with patients who did not receive radiotherapy ($P = 0.0033$).^[43]

Early, nonrandomized trials suggested that systemic chemotherapy produced better outcomes in OS patients compared with historical controls.^[44]

However, not all investigators were convinced that the better outcome resulted from the use of chemotherapy. At that time, most trials were limited to patients without clinically detectable metastases, and the superior outcome could have been the result of the selection of a cohort of patients with better outcomes. In addition, it could also be explained by earlier diagnosis resulting from the routine use of CT to assess for pulmonary metastasis or improvements in surgical techniques.^[45] In the early 1980s, investigators at the Mayo Clinic carried out the first randomized trial

of adjuvant chemotherapy for OS. In that study, following surgical resection, patients were randomly assigned to either observation or chemotherapy group. There was no difference in the outcome between the two groups, and the disease-free survival (DFS) rate was 40%, suggesting that the natural history of the disease had changed and that this accounted for the difference in outcomes observed in the adjuvant chemotherapy trials. That particular study was raised substantial controversy as it suggested that historical controls were not valid and that randomized trials were essential.^[45] However, other investigators vehemently resisted this idea and argued that historical controls were appropriate and that it was unethical to conduct a randomized trial that included observation following surgery.^[45]

Two subsequent randomized studies clarified this controversy.^[46] Link *et al.* developed a randomized study of observation and adjuvant chemotherapy. Patients treated with surgery alone had a 2-year relapse-free survival (RFS) probability of 17%, versus 66% for those receiving adjuvant chemotherapy. With longer follow-up, the 6-year RFS rate for the observation group was 11%, while for those receiving adjuvant therapies, it remained at 66%.^[45] An overall survival advantage with adjuvant chemotherapy also became apparent in accordance with the RFS rate.^[47] Eilber *et al.* reported similar results, definitively proving that adjuvant chemotherapy produced higher DFS rates for patients with nonmetastatic OS.^[46]

Rosen *et al.* introduced the concept of chemotherapy administration before definitive surgery.^[48] This approach offered the opportunity to develop a custom endoprosthesis for limb salvage procedures and offered the theoretical advantage of early treatment of micrometastases while facilitating the surgical procedure. It also provided the opportunity to examine the histologic response of the tumor to preoperative therapy and assess its effectiveness. A strong correlation between the degree of necrosis (Huvos grade) and subsequent DFS was observed,^[48] which has been confirmed in a number of subsequent clinical trials.^[48] A theoretical concern with this approach is that the delay in removal of the bulk tumor could lead to the emergence of chemotherapy resistance. However, a prospective, Children's Oncology Group trial demonstrated no difference between treatment using immediate definitive surgery and treatment with neoadjuvant chemotherapy followed by definitive surgery.^[49] Given the advantages in facilitating limb salvage procedures and assessing chemotherapy response, the use of preoperative chemotherapy has become the standard approach to treatment.

An advance in the technology of histopathologic evaluation of the tumor necrosis rate has demonstrated to be a reliable prognostic tool. The Huvos necrosis grading system is extensively used for the assessment of chemotherapy in OS [Table 4]. On the basis of the percentage of tumor

Table 4: Huvos necrosis grading system

Grade	Parameter
I	Little or no evidence of necrosis
II	Necrosis of 50%-90%
III	Necrosis between 90% and 99%
IV	100% necrosis

necrosis after chemotherapy, patients can be classified as a poor responder or good responder, which is an important parameter to predict long-term prognosis. Grades I and II were considered a poor response to chemotherapy while Grades III and IV were considered a good therapeutic response.^[50] Thus, this system is useful for physicians to determine further prescription of the patient.

The identification of the prognostic value of the degree of necrosis following chemotherapy led to the suggestion that chemotherapy be modified for patients with less necrosis (currently referred as either standard or poor responders, and variably defined as <90% through <98% tumor necrosis or the persistence of more than rare viable tumor cells or clumps) in an attempt to increase the probability of DFS. Investigators at Memorial Sloan Kettering Cancer Center, using the T-10 protocol, reported an improved outcome for patients with poor histologic responses following a change in postoperative therapy.^[48] Longer follow-up of that patient population, however, showed no benefit to therapy intensification.^[49] Numerous other investigators have undertaken studies using a similar strategy, delivering a variety of intensified regimens to patients with standard responses in an attempt to improve their outcomes. However, the majority of these studies have not been able to reproduce the initial results reported by Rosen *et al.*^[48] Intensification of therapy during preoperative treatment to increase the number of patients with good responses (favorable responders) likewise did not change the long-term outcomes of these patients,^[51] and when preoperative therapy is lengthened, histologic response loses its prognostic value.^[51] The specific roles of various chemotherapeutic agents in the treatment of OS have been the subject of many studies. For example, the role of high-dose methotrexate remains controversial, with a few randomized studies reporting it not to be an important component of therapy, while others reported that it was.^[51] Unfortunately, the European study^[51] was compromised by the study design, and the overall outcome was markedly inferior to that of other contemporary studies. However, in spite of these pitfalls, the standard chemotherapy for the European Osteosarcoma Intergroup (EOI) has continued to be the two-drug combination of cisplatin and doxorubicin,^[52] since there was no survival advantage to the use of more complex regimens observed in their studies. In addition, although the use of bleomycin, cyclophosphamide, and actinomycin-D was common in OS, subsequent studies have demonstrated the combination to be ineffective,^[52] and these drugs are no longer included in the treatment of OS.

Intra-arterial administration of chemotherapy offers the theoretical advantage of maximizing drug delivery to the tumor vasculature,^[53] and pharmacokinetic studies demonstrate high local drug concentrations with dramatic clinical responses.^[53] Although theoretically appealing, and effective in inducing responses, the use of this approach in the context of multiagent chemotherapy does not appear to offer a significant advantage over systemic chemotherapy.^[53]

Ifosfamide has, relatively recently, been shown to have activity in OS,^[54] and when incorporated either alone or in combination with etoposide into the treatment of patients with metastatic disease, the results appear promising.^[54] The last national North American randomized study (INT-0133) was designed to address whether the addition of ifosfamide and muramyl tripeptide phosphatidylethanolamine (MTP-PE) to the three other agents used in the standard treatment of OS (doxorubicin, cisplatin, and high-dose methotrexate) could improve DFS. MTP, a component of the *bacillus* Calmette-Guerin cell wall, is conjugated to PE and encapsulated in liposomes to improve delivery to the reticuloendothelial system. The rationale supporting the use of this immune adjuvant was the encouraging results obtained in a prospective randomized trial of this compound in canines as well as its apparent efficacy in relapsed patients.^[55] Preliminary results of the INT-0133 trial did not demonstrate a survival advantage for patients treated with either ifosfamide or MTP-PE alone. However, there appeared to be an interaction between ifosfamide and MTP-PE, and further investigations, which attempt to exploit this interaction, are ongoing.

Parallel to the North American developments in OS, the EOI conducted a series of studies based on six cycles of the two-drug regimen of cisplatin and doxorubicin.^[56] The German–Austrian–Swiss Cooperative Osteosarcoma Study Group (COSS) also performed a series of studies incorporating multiagent chemotherapy and surgical resection. The best results for this group resulted from the use of methotrexate, cisplatin, doxorubicin, and ifosfamide, with a 10-year survival rate of 71%.^[56] The Scandinavian Sarcoma Group (SSG) has also performed various nonrandomized neoadjuvant chemotherapy trials for high-grade OS. Their second OS trial, using a three-drug combination of high-dose methotrexate, doxorubicin, and cisplatin up front and replacement with ifosfamide and etoposide for poor responders, resulted in a 5-year overall survival rate of 74%. Although the ifosfamide/etoposide combination failed to improve outcome, this drug pair replaced the standard agents postoperatively, making it difficult to determine whether the addition of this combination improved outcome.

The event-free survival time for patients treated by COSS investigators was superior when ifosfamide was incorporated into the standard three-drug regimen, and a previous nonrandomized Italian trial reported that

the addition of ifosfamide and etoposide to standard chemotherapy for patients with poor histologic responses resulted in an outcome for those patients that was similar to that reported for patients with good histologic responses.^[55]

In addition, although the INT-0133 trial concluded that the addition of ifosfamide did not improve outcome, this drug was administered at a lower dose than the one administered to patients with metastatic OS, and studies in those patients suggested the presence of a dose-dependent effect. Taken together, these findings suggest that the combination of ifosfamide and etoposide has significant activity and might improve the outcome for patients with poor histologic responses. Although a few studies have evaluated the role of altering postoperative therapy in poor histologic responders, the role of high-dose ifosfamide and etoposide in this setting has not been investigated in a large controlled trial. The North American Children's Oncology Group (COG) has recently completed a series of three pilot studies using a backbone of cisplatin, doxorubicin, and high-dose methotrexate. The purpose of these pilots was to develop a chemotherapy regimen that could subsequently be tested in a randomized study. The pilots evaluated three different strategies. Pilot 1 was based on the premise that doxorubicin is an essential component of OS therapy,^[56] and its use has been limited by the potential for cardiotoxicity. This complication appears to be at least partially ameliorated with dexrazoxane. Hence, pilot 1 evaluated the feasibility of increasing doxorubicin dose intensity by administering dexrazoxane. Pilot 2 evaluated the feasibility of combining standard-dose ifosfamide with dose-intensive doxorubicin with dexrazoxane and pilot 3 evaluated the feasibility of increasing the dose intensity of ifosfamide and etoposide.

It appears that we have reached the limit in the survival of OS patients achievable with currently available chemotherapy. Since further improvements in outcome will depend on refinements of therapy, the impact of which will be assessable only in large patient groups, four major research groups in OS, COG, COSS, EOI, and SSG, have agreed on trying to conduct an intergroup randomized study. The power of such collaboration lies in the ability to conduct large trials with rapid accrual, allowing investigation of new agents quickly and effectively. Acknowledging the difficulties that face the establishment of such collaboration and recognizing that there are no available new agents, the group has agreed on a relatively simple randomized study to determine whether ifosfamide and etoposide improve the outcome for patients with poor histologic responses.

Patients with good histologic responses have a 3-year event-free survival rate of 75%, and the use of ifosfamide and etoposide results in an increased risk of late sequelae. In these patients, the group proposes to determine, in a randomized comparison, whether interferon- α improves

event-free survival. The rationale for using interferon- α is to maintain remission in a significant proportion of patients who have previously had good responses to chemotherapy. The *in vitro* effects of interferon- α on OS cells were demonstrated more than 20 years ago, and observations since have consistently supported its growth inhibitory effect on OS both in cell lines and in animal models.^[57] Although interferon- α has not been widely tested in clinical trials in OS, its role as maintenance in other tumors has been extensively studied.^[57] Most information on patients with OS comes from a Scandinavian series in which 64 patients received interferon- α as a single adjuvant to surgery, and 69% remained in complete remission.^[57] A pegylated preparation of interferon- α , with an extended half-life, offers the advantages of less frequent administration and improved dose delivery.^[57] The tolerability of this preparation has now been demonstrated, and there are additional extensive data on the tolerability of interferon- α in children treated for chronic hepatitis.^[57]

Although adjuvant chemotherapy is effective in the setting of localized OS, the outcome for patients with clinically detectable metastases at diagnosis continues to be suboptimal.^[58] The standard management of these patients follows the same principles as the management of those patients who present with localized disease and with this approach; a small subset of patients achieves prolonged DFS.^[58] The treatment of patients who develop recurrent OS depends on the initial therapy, time to recurrence, and the site and number of recurrent tumors. With aggressive treatment, as many as 40% of patients who develop lung metastases survived more than 5 years after relapse.^[58] Patients, who relapse following the use of modern treatment approaches, including chemotherapy and surgery, have a significantly lower probability of survival.

Therapy-related sequelae

Unfortunately, the use of multiagent treatment for OS is associated with acute and long-term toxicities. These include the potential for hearing loss and hypomagnesemia^[59] associated with the administration of cisplatin. Therefore, it is essential to obtain baseline audiograms before initiation of treatment to monitor for hearing loss. It is also important to monitor electrolytes secondary to the potential for abnormalities even years after treatment completion.^[59]

Other treatment-related complications include anthracycline-induced cardiomyopathy,^[60] which is typically observed with high cumulative doses.^[60] To monitor for this complication, patients usually have baseline cardiac evaluations with an echocardiogram or radionuclide scan. Cardiac function is usually followed closely during treatment. Since doxorubicin appears to be an important component of therapy, methods to minimize the potential for this complication are under evaluation. These include the use of dexrazoxane, continuous-infusion doxorubicin,

and pegylated liposomal doxorubicin.^[60] Both pegylated liposomal doxorubicin and dexrazoxane appear effective at minimizing acute cardiac toxicity, but there is limited information regarding their long-term efficacy. In addition, postpubertal males should be given the opportunity to carry out sperm banking since chemotherapy for OS has the potential to produce sterility. Although newer techniques for maintaining fertility in women are under development, their indications are not well established.

Prognosis

- Patients with the periosteal type of OS have a more favorable outcome. In an analysis of 119 patients, the overall survival was 83% at 10 years^[59]
- The prognosis for patients with conventional high-grade OS primarily depends on whether metastases are detectable at diagnosis. Patients who present with metastases or with a multifocal disease have a poor prognosis, with long-term survival rates of <25%
- For patients with the initially localized disease, the prognosis depends mainly on 2 variables: Resectability and the response to chemotherapy. Those who have the completely resectable disease and those whose tumors have an excellent histologic response to neoadjuvant chemotherapy have the best likelihood for a cure
- Before the 1970s, the 5-year survival rate of patients with nonmetastatic OS was <20%, even with aggressive surgery (mostly amputations)
- The fact that most relapses occurred at metastatic sites (primarily the lung) attests to the fact that most patients have the undetectable metastatic disease at diagnosis (i.e., micrometastatic disease)
- With the introduction of postoperative (adjuvant) chemotherapy, survival rates began to improve
- According to data from the NCI SEER program, the 5-year survival rate from 1975 to 1984 was 49% and from 1985 to 1994 was 63%.^[3] For the latter period, female patients fared slightly better than male patients (5-year survival rates of 70% vs. 59%)
- In a small dataset of patients younger than 5 years, the outcome appeared to be similar to that of older patients^[4]
- Results of the most recent cooperative group trial conducted by the COG suggest that the addition of ifosfamide to standard three-drug regimen was not helpful; however, that the addition of the immune-enhancing drug muramyl tripeptide increased 6-year overall survival from 70% to 78% for localized disease.^[54,60] The use of MTP-PE requires further investigation before becoming standard therapy
- Surgical resection of recurrent disease can achieve cure in about 25% of patients^[61]
- In a cohort study of 733 long-term (>5 years) survivors of OS, Nagarajan *et al.* reported overall survival of 88.6% at 20 years. Of interest in this group were the incidence of second malignancy (5.4%), those who

reported at least one chronic medical condition (86.9%), and those who reported activity limitations (29.1%). The cohort includes a larger number of patients with amputations than would be seen in recently treated patients^[60]

- Improving the survival rate and functional outcome and minimizing the short- and long-term adverse effects remain goals of clinical trials for OS
- The major challenge is curing patients with the unresectable metastatic disease
 - o Strategies currently under consideration include dose intensification (e.g., anthracycline dose escalation facilitated by dexrazoxane cardioprotection), immune modulators, monoclonal antibodies targeting tumor cell antigens (e.g., human epidermal growth factor receptor 2/neu), and antiangiogenic agents that target components of the tumor vascular supply
 - o High-dose administration of the bone-seeking radioisotope samarium is also under investigation (with autologous stem-cell support) for safety and efficacy in metastatic or nonresectable OS limited to bone
 - o Finally, the role of the emerging field of oncolytic viruses for the treatment of OS is currently being explored (ClinicalTrials.gov, NCT00503295, and NCT00931931).

Future directions

The major goals of cancer biology studies are to identify prognostic factors and therapeutic targets. Future needs and directions to study the molecular pathology of OS include as follows: Incorporating the current lists of genetic alterations into functionally related groups of genetic alterations (hyperproliferative, cell cycle control, apoptosis, DNA damage response); gaining a better understanding of the timing and relationship of common oncogenic events; developing a comprehensive analysis of the p53 and Rb pathways in a large set of OS samples; gaining a better understanding of different “equivalent” oncogenic events (preferential 12q13 amplification in low-grade/surface OS, preferential p53 missense mutation in adult OS); gaining a better understanding of the paradox of carcinoma-type cytogenetics in the setting of a younger age range; and defining the biologic/genetic subsets of OS according to karyotypic complexity. Gene and protein expression array data may soon provide customized information on tumor prognosis and metastatic potential as well as indications of possible tumor targets for selective therapy.

Increasing the understanding of the basic biology of OS has been a high priority in recent years. Since therapy intensification after a poor histologic response has not generally resulted in improved outcome and the prognostic factors available are limited, efforts are

directed at identifying biological factors that predict the outcome. Examples include studies of P-glycoprotein expression, DNA ploidy, human epidermal growth factor receptor 2 overexpression, cDNA expression profiling, and comparative genomic hybridization. Many molecular markers are also currently under study, but sufficient data have not yet been accrued to allow any to be recommended as prognostic factors.^[61]

Another area of active research has been the use of radiographic studies as predictors of chemotherapy response at surgical resection. Although several methods have been tested, none thus far have been sufficiently sensitive or reliable. Assessments by conventional radiographs, CT, and MRI show definite changes in response to presurgical chemotherapy, but the changes do not correlate reliably with histologic response. Various studies suggest that three-phase bone scans and thallium scintigraphy may predict a histologic tumor response. Dynamic MRI and positron emission spectroscopy are also promising. Ultimately, if radiographic studies are effective at determining the degree of necrosis at surgical resection, serial evaluation of tumor response could be performed, and these radiographic studies could then serve as a prognostic factor or a determinant of therapeutic efficacy.^[62]

Recently, antiangiogenic therapy becomes a highly promising therapeutic approach for the treatment of cancer. Vascular endothelial growth factor (VEGF) and fibroblast growth factor have been recognized as the two most potent positive regulators of angiogenesis.^[63] The Food and Drug Administration (FDA) approved bevacizumab (a monoclonal antibody targeting VEGF) as the first antiangiogenic drug in 2004 for the treatment of colon cancer. More than forty antiangiogenic agents are being tested in cancer patients in clinical trials worldwide.^[64] The clinical practice with Bevacizumab in pediatric patients is inadequate. It has activity in pediatric malignancies, but large multicenter trials are needed to assess the effect of the drug in childhood malignancies. The ongoing clinical trial of bevacizumab includes evaluation against OS and malignant fibrous histiocytoma of bone.^[65] Small molecule inhibitors such as sorafenib and sunitinib acts on multiple intracellular and receptor protein kinases (e.g., VEGF receptors, PDGFR, FLT3, RET, BRAF, and KIT) that are components of signaling pathways controlling tumor growth and angiogenesis.^[66] The U.S. FDA approved both agents for the treatment of advanced renal cell carcinoma in adults.^[67] Currently, sorafenib is being evaluated in high-grade OS.^[68]

There is a clear need for newer effective agents for patients with OS, especially for patients who present with metastatic disease or develop disease recurrence. Those patients are candidates for participation in clinical trials of novel agents. Monoclonal antibodies directed against OS may prove useful as treatment, either for drug delivery or as radiopharmaceuticals. Trastuzumab, which targets the epidermal growth factor receptor 2, is currently under

investigation in OS. Monoclonal antibodies specific for the ganglioside GD2, a cell surface antigen expressed by human neuroblastomas, also recognize human OSs and could be considered for therapy. Other biologic approaches, such as the use of inhaled granulocyte-macrophage colony-stimulating factor and interferon- α , are under investigation, while interleukin-12 and interferon- γ are being investigated *in vitro*. Insulin-like growth factor has been found to be expressed on OS cells, suggesting growth hormone antagonists may be an effective treatment. Bone-seeking isotopes such as samarium may allow the delivery of extremely high doses of local irradiation, perhaps providing an appropriate treatment approach for sites of mineralized disease.^[62] Adenoviral gene therapy using selective promoters, such as the promoter that drive osteocalcin expression, controlling a suicide gene (thymidine kinase) are under development. Investigation of new agents such as trimetrexate and imatinib is also an active area of research in OS. For patients presenting with localized OS, increasing the dose intensity may increase the efficacy of currently available agents.

Acknowledgement

Author would like to acknowledge Mr. Amit Pawar, and Dr. Madanrao Mane from Karmic Lifesciences LLP, Mumbai, for writing the manuscript.

Financial support and sponsorship

Nil.

Conflicts of interest

There are no conflicts of interest.

References

1. Link MP, Eilber F. Paediatric oncology: Osteosarcoma. In: Pizzo PA, Poplack DG, editors. Principles and Practice of Paediatric Oncology. Philadelphia, PA: Lippincott; 1989.
2. Bielack SS, Bernstein ML. Osteosarcoma. In: Cancer in Children: Clinical Management. 5th ed. New York: Oxford University Press; 2005.
3. Carrle D, Bielack SS. Current strategies of chemotherapy in osteosarcoma. *Int Orthop* 2006;30:445-51.
4. Mirabello L, Troisi RJ, Savage SA. Osteosarcoma incidence and survival rates from 1973 to 2004: Data from the surveillance, epidemiology, and end results program. *Cancer* 2009;115:1531-43.
5. Arora RS, Eden TO, Kapoor G. Epidemiology of childhood cancer in India. *Indian J Cancer* 2009;46:264-73.
6. Mohseny AB, Szuhai K, Romeo S, Buddingh EP, Briaire-de Bruijn I, de Jong D, *et al.* Osteosarcoma originates from mesenchymal stem cells in consequence of aneuploidization and genomic loss of Cdkn2. *J Pathol* 2009;219:294-305.
7. Gorlick R. Current concepts on the molecular biology of osteosarcoma. *Cancer Treat Res* 2009;152:467-78.
8. Ambroszkiewicz J, Gajewska J, Klepacka T, Chelchowska M, Laskowska-Klita T, Wozniak W. Clinical utility of biochemical bone turnover markers in children and adolescents with osteosarcoma. *Adv Med Sci* 2010;55:266-72.
9. Pandha HS, Waxman J. Tumour markers. *QJM* 1995;88:233-41.

10. Perkins GL, Slater ED, Sanders GK, Prichard JG. Serum tumor markers. *Am Fam Physician* 2003;68:1075-82.
11. Ambroszkiewicz J, Gajewska J, Klepacka T, Chelchowska M, Laskowska-Klita T, Wozniak W. A comparison of serum concentrations of biochemical bone turnover markers in patients with osteosarcoma with good and poor prognosis. *Pol Merkur Lekarski* 2010;29:19-26.
12. DuBois S, Demetri G. Markers of angiogenesis and clinical features in patients with sarcoma. *Cancer* 2007;109:813-9.
13. Kager L, Zoubek A, Dominkus M, Lang S, Bodmer N, Jundt G, *et al.* Osteosarcoma in very young children: Experience of the Cooperative Osteosarcoma Study Group. *Cancer* 2010;116:5316-24.
14. Del Mare S, Kurek KC, Stein GS, Lian JB, Aqeilan RI. Role of the WWOX tumor suppressor gene in bone homeostasis and the pathogenesis of osteosarcoma. *Am J Cancer Res* 2011;1:585-94.
15. Markiewicz K, Zeman K, Kozar A, Golebiowska-Wawrzyniak M. Evaluation of selected cytokines in children and adolescents with osteosarcoma at diagnosis – Preliminary report. *Med Wieku Rozwoj* 2011;15:25-31.
16. Mikulic D, Ilic I, Cepulic M, Orlic D, Giljevic JS, Fattorini I, *et al.* Tumor angiogenesis and outcome in osteosarcoma. *Pediatr Hematol Oncol* 2004;21:611-9.
17. Roulston JE, Leonard RC. Serological Tumour Markers: An Introduction. Edinburgh, Scotland: Churchill Livingstone; 1993.
18. Folkman J. Angiogenesis in cancer, vascular, rheumatoid and other disease. *Nat Med* 1995;1:27-31.
19. Folkman J. Clinical applications of research on angiogenesis. *N Engl J Med* 1995;333:1750-7.
20. Folkman J. Tumor angiogenesis and metastasis: Correlation in invasive breast carcinoma. *N Engl J Med* 1991;324:1-8.
21. Saab R, Rao BN, Rodriguez-Galindo C, Billups CA, Fortenberry TN, Daw NC. Osteosarcoma of the pelvis in children and young adults: The St. Jude Children's Research Hospital experience. *Cancer* 2005;103:1468-74.
22. Aziz K. Tumour markers: Current status and future applications. *Scand J Clin Lab Invest Suppl* 1995;221:153-5.
23. Barak V, Goike H, Panaretakis KW, Einarsson R. Clinical utility of cytokeratins as tumor markers. *Clin Biochem* 2004;37:529-40.
24. Savitskaya YA, Rico G, Linares L, Mendez T, Martinez E, Estrada E, *et al.* Circulating biomarker-IgM complexes in the serum of paediatric patients with osteosarcoma and Ewing's tumor. *Ann Rheum Dis* 2011;70 Suppl 3:189.
25. Guillou L, Aurias A. Soft tissue sarcomas with complex genomic profiles. *Virchows Arch* 2010;456:201-17.
26. Kurt AM, Unni KK, McLeod RA, Pritchard DJ. Low-grade intraosseous osteosarcoma. *Cancer* 1990;65:1418-28.
27. Zhu L, McManus MM, Hughes DP. Understanding the biology of bone sarcoma from early initiating events through late events in metastasis and disease progression. *Front Oncol* 2013;3:230.
28. Dahlin DC, Unni KK, editors. Osteosarcoma. In: Bone Tumors: General Aspects and Data on 8542 Cases. Springfield, IL: Charles C. Thomas; 1986. p. 269-307.
29. Meyers PA, Gorlick R. Osteosarcoma. *Pediatr Clin North Am* 1997;44:973-89.
30. Kaste SC, Pratt CB, Cain AM, Jones-Wallace DJ, Rao BN. Metastases detected at the time of diagnosis of primary pediatric extremity osteosarcoma at diagnosis: Imaging features. *Cancer* 1999;86:1602-8.
31. Link MP, Goorin AM, Miser AW, Green AA, Pratt CB, Belasco JB, *et al.* The effect of adjuvant chemotherapy on relapse-free survival in patients with osteosarcoma of the extremity. *N Engl J Med* 1986;314:1600-6.
32. Ritter J, Bielack SS. Osteosarcoma. *Ann Oncol* 2010;21 Suppl 7:vii320-5.
33. Sharma DN, Rastogi S, Bakhshi S, Rath GK, Julka PK, Laviraj MA, *et al.* Role of extracorporeal irradiation in malignant bone tumors. *Indian J Cancer* 2013;50:306-9.
34. Hong AM, Millington S, Ahern V, McCowage G, Boyle R, Tattersall M, *et al.* Limb preservation surgery with extracorporeal irradiation in the management of malignant bone tumor: The oncological outcomes of 101 patients. *Ann Oncol* 2013;24:2676-80.
35. Fritz J, Fishman EK, Corl F, Carrino JA, Weber KL, Fayad LM. Imaging of limb salvage surgery. *AJR Am J Roentgenol* 2012;198:647-60.
36. Yasin NF, Ajit Singh V, Saad M, Omar E. Which is the best method of sterilization for recycled bone autograft in limb salvage surgery: A radiological, biomechanical and histopathological study in rabbit. *BMC Cancer* 2015;15:289.
37. Weisstein JS, Goldsby RE, O'Donnell RJ. Oncologic approaches to pediatric limb preservation. *J Am Acad Orthop Surg* 2005;13:544-54.
38. Friedman MA, Carter SK. The therapy of osteogenic sarcoma: Current status and thoughts for the future. *J Surg Oncol* 1972;4:482-510.
39. Link MP, Goorin AM, Miser AW, Green AA, Pratt CB, Belasco JB, *et al.* The effect of adjuvant chemotherapy on relapse-free survival in patients with osteosarcoma of the extremity. *N Engl J Med* 1986;314:1600-6.
40. Baum ES, Gaynon P, Greenberg L, Krivit W, Hammond D. Phase II trial cisplatin in refractory childhood cancer: Children's Cancer Study Group Report. *Cancer Treat Rep* 1981;65:815-22.
41. Pratt CB, Shanks EC. Doxorubicin in treatment of malignant solid tumors in children. *Am J Dis Child* 1974;127:534-6.
42. Jaffe N, Frei E 3rd, Traggis D, Bishop Y. Adjuvant methotrexate and citrovorum-factor treatment of osteogenic sarcoma. *N Engl J Med* 1974;291:994-7.
43. Ozaki T, Flege S, Kevric M, Lindner N, Maas R, Delling G, *et al.* Osteosarcoma of the pelvis: Experience of the Cooperative Osteosarcoma Study Group. *J Clin Oncol* 2003;21:334-41.
44. Pratt CB, Rivera G, Shanks E, Kumar AP, Green AA, George S. Combination chemotherapy for osteosarcoma. *Cancer Treat Rep* 1978;62:251-7.
45. Lange B, Levine AS. Is it ethical not to conduct a prospectively controlled trial of adjuvant chemotherapy in osteosarcoma? *Cancer Treat Rep* 1982;66:1699-704.
46. Eilber F, Giuliano A, Eckardt J, Patterson K, Moseley S, Goodnight J. Adjuvant chemotherapy for osteosarcoma: A randomized prospective trial. *J Clin Oncol* 1987;5:21-6.
47. Link MP. The multi-institutional osteosarcoma study: An update. *Cancer Treat Res* 1993;62:261-7.
48. Rosen G, Murphy ML, Huvos AG, Gutierrez M, Marcove RC. Chemotherapy, *en bloc* resection, and prosthetic bone replacement in the treatment of osteogenic sarcoma. *Cancer* 1976;37:1-11.
49. Goorin AM, Schwartztruber DJ, Devidas M, Gebhardt MC, Ayala AG, Harris MB, *et al.* Presurgical chemotherapy compared with immediate surgery and adjuvant chemotherapy for nonmetastatic osteosarcoma: Pediatric Oncology Group Study POG-8651. *J Clin Oncol* 2003;21:1574-80.
50. Huvos AG. Bone Tumors: Diagnosis, Treatment, and Prognosis. 2nd ed. London, UK: W.B. Saunders; 1991.
51. Bacci G, Picci P, Ferrari S, Ruggieri P, Casadei R, Tienghi A, *et al.* Primary chemotherapy and delayed surgery for nonmetastatic osteosarcoma of the extremities. Results in 164 patients preoperatively treated with high doses of

- methotrexate followed by cisplatin and doxorubicin. *Cancer* 1993;72:3227-38.
52. Lewis IJ, Nooij M, European Osteosarcoma Intergroup. Chemotherapy at standard or increased dose intensity in patients with operable osteosarcoma of the extremity: A randomised controlled trial conducted by the European Osteo Sarcoma Intergroup (ISRCTN 86294690). *Proc Am Soc Clin Oncol* 2003;22:816.
 53. Jaffe N, Robertson R, Ayala A, Wallace S, Chuang V, Anzai T, *et al.* Comparison of intra-arterial cis-diamminedichloroplatinum II with high-dose methotrexate and citrovorum factor rescue in the treatment of primary osteosarcoma. *J Clin Oncol* 1985;3:1101-4.
 54. Pratt CB, Horowitz ME, Meyer WH, Etcubanas E, Thompson EI, Douglass EC, *et al.* Phase II trial of ifosfamide in children with malignant solid tumors. *Cancer Treat Rep* 1987;71:131-5.
 55. Kleinerman ES, Meyers PA, Raymond AK, Gano JB, Jia SF, Jaffe N. Combination therapy with ifosfamide and liposome-encapsulated muramyl tripeptide: Tolerability, toxicity, and immune stimulation. *J Immunother Emphasis Tumor Immunol* 1995;17:181-93.
 56. Bramwell VH, Burgers M, Sneath R, Souhami R, van Oosterom AT, Voûte PA, *et al.* A comparison of two short intensive adjuvant chemotherapy regimens in operable osteosarcoma of limbs in children and young adults: The first study of the European Osteosarcoma Intergroup. *J Clin Oncol* 1992;10:1579-91.
 57. Strander H, Einhorn S. Effect of human leukocyte interferon on the growth of human osteosarcoma cells in tissue culture. *Int J Cancer* 1977;19:468-73.
 58. Kager L, Zoubek A, Pötschger U, Kastner U, Flege S, Kempf-Bielack B, *et al.* Primary metastatic osteosarcoma: Presentation and outcome of patients treated on neoadjuvant Cooperative Osteosarcoma Study Group protocols. *J Clin Oncol* 2003;21:2011-8.
 59. Hayes FA, Green AA, Senzer N, Pratt CB. Tetany: A complication of cis-dichlorodiammineplatinum (II) therapy. *Cancer Treat Rep* 1979;63:547-8.
 60. Nagarajan R, Kamruzzaman A, Ness KK, Marchese VG, Sklar C, Mertens A, *et al.* Twenty years of follow-up of survivors of childhood osteosarcoma: a report from the Childhood Cancer Survivor Study. *Cancer* 2011;117:625-34.
 61. Tarkkanen M, Karhu R, Kallioniemi A, Elomaa I, Kivioja AH, Nevalainen J, *et al.* Gains and losses of DNA sequences in osteosarcomas by comparative genomic hybridization. *Cancer Res* 1995;55:1334-8.
 62. Schulte M, Brecht-Krauss D, Werner M, Hartwig E, Sarkar MR, Keppler P, *et al.* Evaluation of neoadjuvant therapy response of osteogenic sarcoma using FDG PET. *J Nucl Med* 1999;40:1637-43.
 63. Al-Husein B, Abdalla M, Trepte M, Deremer DL, Somanath PR. Antiangiogenic therapy for cancer: An update. *Pharmacotherapy* 2012;32:1095-111.
 64. Bid HK, Houghton PJ. Targeting angiogenesis in childhood sarcomas. *Sarcoma* 2011;601514. [Doi: 10.1155/2011/601514].
 65. Benesch M, Windelberg M, Sauseng W, Witt V, Fleischhack G, Lackner H, *et al.* Compassionate use of bevacizumab (Avastin) in children and young adults with refractory or recurrent solid tumors. *Ann Oncol* 2008;19:807-13.
 66. Kim A, Balis FM, Widemann BC. Sorafenib and sunitinib. *Oncologist* 2009;14:800-5.
 67. Grandinetti CA, Goldspiel BR. Sorafenib and sunitinib: Novel targeted therapies for renal cell cancer. *Pharmacotherapy* 2007;27:1125-44.
 68. Maris JM, Courtright J, Houghton PJ, Morton CL, Kolb EA, Lock R, *et al.* Initial testing (stage 1) of sunitinib by the pediatric preclinical testing program. *Pediatr Blood Cancer* 2008;51:42-8.