

## ***Case Report-II***

# Papillary Carcinoma of Thyroid in A 11 Months Old Child

SOUMITA PODDAR, SIDDHARTHA BASU, ANUP MAJUMDER and DEVLEENA

### **ABSTRACT**

**Carcinoma of thyroid gland is rare in pediatric age group before the age of 15 years. A 11 months old child presented with swelling in midline of neck which showed cold nodule on thyroid scan. On fine needle aspiration biopsy (FNAC) papillary carcinoma of thyroid was detected and the patient underwent subtotal thyroidectomy followed by radioiodine ablation and thyroid supplementation. The case is being reported on account of its rarity.**

### **INTRODUCTION**

Thyroid carcinoma is rare in children, with an incidence of 1.5%. The peak age is between 7 to 12 years of age. Thyroid cancer in infancy is extremely rare.

**CASE:** A 11 months old female child was brought to this hospital with swelling in the midline of neck since 2 months of age. The swelling was painless and almost pea size initially but had rapidly increased in size in the past one month. The swelling was 2-3 cm in size in its greatest axis in midline of neck, mobile, firm in consistency, smooth surfaced and it moved with deglutition. The child was sucking and feeding well. Vital signs were normal. No cervical lymph node was palpable. USG of thyroid showed a hypoechoic mass arising from the left lobe of thyroid almost 1×1.5 cm in size. Rest of the thyroid gland was normal. On Thyroid scan (<sup>99m</sup>Tc):- there was poor patchy uptake of radiotracer and a cold

nodule was detected. USG guided FNAC from the thyroid nodule showed papillary carcinoma of thyroid gland. The Serum T3, T4, TSH:- were within normal limits. Chest X-Ray, hematological profile, liver/ renal function tests were within normal limits. Child under went surgery and a sub total thyroidectomy was done. The post operative period was uneventful. The excised specimen measured 1.5×2 cm. The histopathological features confirmed papillary carcinoma of thyroid gland. The capsule was not invaded. Post operative thyroid scan was done after 6 weeks of surgery which showed remnant of thyroid tissue. No other metastatic thyroid tissue was detected. The patient underwent radioiodine(<sup>131</sup>I) ablation. Presently the child is on thyroid hormone supplementation and is disease free at 2 months follow up.

### **DISCUSSION**

Incidence of thyroid cancer in pediatric age group is 1.5%.<sup>2</sup> The peak age of presentation is 7 to 12 years and about 2/3<sup>rd</sup> of cases are among girls.<sup>3</sup> The occurrence of carcinoma thyroid after Chernobyl nuclear accident among 0-6 years children was 2-12/10<sup>5</sup> persons during the year 1986-2002.<sup>4</sup> Present case is unusual because the age of presentation is only 11 months.

The possible causative factors for carcinoma of thyroid in pediatric age group is radiation( >150 cGy), average latent period is 7 year). Here possibility of 'in utero' exposure may be considered. Although several studies don't support this possibility and only one such incident was found (0.09%) among 2049 children exposed 'in utero' during the Chernobyl accident. In our case, mother was exposed to diagnostic dose of radiation during

Department of Radiotherapy, Institute of Post Graduate Medical Education & Research and SSKM Hospital, KOLKATA-700020

Correspondence to: **SOUMITA PODDAR**

E-mail: onco\_soumita@yahoo.co.in

pregnancy. As radiation carcinogenesis is a stochastic effect, the possibility of correlation between 'in utero' exposure and carcinogenesis cannot be ruled out completely. RET/ PTC rearrangement is the most common genetic alteration associated with radiation related papillary thyroid cancer.<sup>6</sup> However this could not be done.

Genetic factor (RAS proto-oncogene in 20% papillary carcinoma of thyroid),<sup>7</sup> familial (in case of medullary carcinoma) or disorder of immune system, TSH receptor activating gene mutation are also considered as the causative factors. Familial factors are autosomal dominant and as no such family history is present in this case, so this possibility can be ruled out. There may be a possibility of occurrence of congenital occult papillary carcinoma. This accounts for 0.5%-36% of all papillary carcinomas. But the disease generally manifests at older ages.

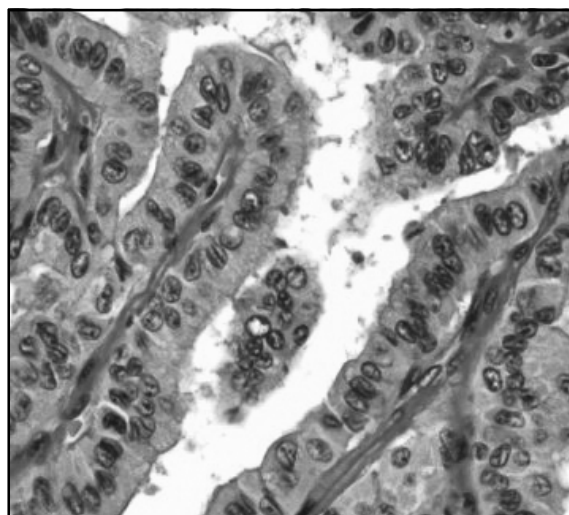
70% of cases of papillary carcinoma of thyroid in children occur below the age of 7 years.<sup>8</sup> The most common presentation is cervical lymphadenopathy or firm palpable thyroid nodule with or without cervical lymphadenopathy.<sup>9</sup> 6% of papillary carcinoma presents with metastasis to lung or upper mediastinal lymphadenopathy. But it almost never occurs in absence of cervical lymphadenopathy. This case presented with firm palpable thyroid nodule without any cervical lymph node or lung metastasis.

On investigation test of thyroid functions usually confirms euthyroidism. Thyroid scan with <sup>123</sup>I or <sup>99m</sup>Tc usually shows parenchyma with normal uptake and one or more hypofunctioning nodules. USG provides adequate information about thyroid size or size of nodule. The single best diagnosis is FNAC; if unsatisfactory, excision or core biopsy is recommended.<sup>10</sup>

Surgery is the treatment of choice.<sup>11</sup> Total or subtotal thyroidectomy is recommended. No clinical trials have established whether total thyroidectomy with lymph node dissection is better than subtotal thyroidectomy.<sup>12</sup> Surgeons preferring a lesser resection hold that differentiated thyroid

carcinoma in children is an indolent disease and that survival is not clearly related to the extent of gland removal.<sup>13</sup> Moreover chance of recurrent laryngeal nerve injury and hypocalcaemia is more in total thyroidectomy. In this patient 2/3<sup>rd</sup> of thyroid gland with the nodule was removed.

<sup>131</sup>I whole body scan should be performed approximately 6 weeks after the initial thyroid resection, followed by therapeutic dose of radionuclide (<sup>131</sup>I) to abate residual tissue and treat residual metastatic disease.<sup>14</sup> Radioiodine ablation has been shown to decrease risk of local recurrence. A higher rate of recurrence has been seen in children who didn't receive initial post operative <sup>131</sup>I ablation than in those who did.<sup>15</sup> After radio ablation most investigators recommend



Histopathology of thyroid showing complex papillary structures composed of a narrow stromal core covered with a layer of glandular epithelium.

exogenous thyroid hormone to suppress TSH-mediated stimulation of the gland. This child also received ablation followed by thyroid hormone supplementation.

In follow up, thyroglobulin has been shown to be a useful marker for residual or metastatic thyroid cancer. Plasma level should be measured yearly and an elevated value should raise the suspicion of recurrence<sup>16</sup>. The overall survival in nonmedullary thyroid cancer in pediatric age group is 98%.<sup>17</sup>

## REFERENCES:

1. Bennett B, Repacholi M, Carr Z. Health effects of the cherbonyl accident and special health care programmes. Report of the UN Cherbonyl Forum Expert Group "Health". Geneva: World Health Organization; 2006.
2. Schlumberger M, De Vathaire F, Travagle JP, et al. Differentiated thyroid carcinoma in childhood: long term follow up of 72 patients. *J Clin Endocrinol Metab* 1987;65:1088.
3. Zimmermann D, Hay ID, Gough IR, et al. Papillary thyroid cancer in children and adults: long term follow up of 1039 patients conservatively treated at one institution during three decades. *Surgery* 1988;104:1157.
4. Kenigsberg J, Buglova E. Health consequences . In: Smith J, Beresford N, eds. *Chernobyl. Catastrophe and consequences*. New York: Springer-Verlag; 2005.
5. Elaine Ron et al. Thyroid cancer incidence among people living in areas contaminated by radiation from the Chernobyl accident. *Health Physics*. 2007;93(5):502-511.
6. Klugbauer S, Pfeiffer P, Gassenhuber H , et al. RET rearrangements in radiation induced papillary thyroid carcinoma: *Genomics* 2001;73:149-160.
7. Lemoine JA, Mayall ES, Wyllie FS, et al: High frequency of ras oncogene activation in all stages of thyroid tumourigenesis. *Oncogene* 1989;4:159-164.
8. McConahey WM, Hay ID, Woolner LB, et al. Papillary thyroid treated at the Mayo Clinic 1946 through 1970: initial manifestations, pathologic findings, therapy and outcome. *Mayo Clinic Proc* 1986;61:978.
9. Robbins J, ed. *Treatment of thyroid cancer in childhood. Proceeding of a workshop held Sept.10-11, 1992, at the National Institute of Health, Bethesda, MD.*
10. Miller JM. Evaluation of thyroid nodules: accent on needle biopsy. *Med Clin North Am* 1985;69:1603.
11. Weber CA, Clark OH. Surgery for thyroid disease. *Med Clin North Am* 1985;69:1097.
12. Ceccarelli C, Pacini F, Lippi F, et al: Thyroid cancers in children and adolescents. *Surgery* 1988;104:1143-1148.
13. La Quaglia MP, Corbally MT, Heller G, et al: Recurrence and morbidity in differentiated thyroid carcinoma in children. *Surgery* 1988;104:1149-1156.
14. Harness JA , Thompson NW, McLeod MK, et al: Differentiated thyroid carcinoma in children and adolescents. *World J Surg* 1992;16:547-554.
15. Nishida T, Nakao K, Hamaji M, et al: preservation of recurrent laryngeal nerve invaded by differentiated thyroid cancer. *Ann Surg* 1997;226:85-91.
16. Kirk JM, Mort C, Grant DB, et al: The usefulness of serum thyroglobulin in the follow up of differentiated thyroid carcinoma in children. *Med Pediatr Oncol* 1992;20:201-208.
17. Beierwaltes WB, Nishiyama RH, Thompson NW, et al. Survival time and "cure" in papillary and follicular thyroid carcinoma with distant metastases: statistics following university of Michigan therapy. *J Nucl Med* 1982;23:561.

