

## Case Report-III

# Childhood Follicular Non-Hodgkin's Lymphoma: A Case Report and Review of Literature

SHIPRA AGARWAL, PRASENJIT DAS, A. K. KARAK, LALIT KUMAR AND RUMA RAY

### ABSTRACT

The majorities of non-Hodgkin's lymphomas in children are lymphoblastic lymphoma, Burkitt's lymphoma, anaplastic large cell lymphoma and diffuse large B-cell lymphoma. Follicular lymphoma is primarily a disease of adulthood with a median age of 59 years. It is rare in pediatric patients. Childhood follicular lymphoma differs from its adult counterpart in several aspects. We report a rare case of childhood low grade mature B-cell non-Hodgkin's lymphoma wherein the tumour cells were CD20 +, focally bcl-6 +, CD3 -, CD5 -, CD10 -, CD23 -, Cyclin D1 -, bcl-2 -, and had a low ki-67 proliferation index. A diagnosis of follicular lymphoma was made on the basis of the focal bcl-6 positivity. Despite non-intervention in the form of chemotherapy or radiotherapy, the patient remained symptom free even after a follow-up of 39 months. This case is being reported for its rarity. This is one of the initial case reports on follicular lymphoma in pediatric age group from the Indian subcontinent.

### INTRODUCTION

Pediatric lymphomas are the third most common malignancy in children and account for 13 % of all childhood cancers.<sup>1,3</sup> Sixty percent of these lymphomas are non- rapidly growing Hodgkin's lymphomas and commonly include lymphoblastic lymphoma, Burkitt's lymphoma, anaplastic large cell lymphoma (ALCL) and diffuse large B-cell lymphoma (DLBCL). The

most common subtype (32%) of non-Hodgkin's lymphoma (NHL) occurring in the pediatric age in India was found to be precursor T-cell lymphoblastic lymphoma (T-LL) in a workshop organized by the International Network of Cancer Treatment and Research (INCTR).<sup>4</sup> In this study, DLBCL, Burkitt's and Burkitt's-like lymphoma, ALCL and Precursor B-cell lymphoblastic lymphoma constituted, 25%, 11%, 10% and 3%, respectively of all the pediatric NHL. Follicular lymphoma, a disease with a median age of presentation of 59 years,<sup>5</sup> is rare in pediatric patients. The youngest patient with follicular lymphoma reported from the Indian subcontinent till date was 17 years.<sup>6</sup> In several series, follicular lymphoma comprises approximately 1% to 2% of all cases of pediatric lymphomas.<sup>7-10</sup> In contrast to the more common non-Hodgkin's lymphomas presenting in childhood and despite having a high grade histopathology, these lymphomas present as an early stage disease with response to a non-interventional mode of treatment.<sup>11</sup> In the present paper, we document an illustrative report of a rare case of childhood low grade mature B-cell non-Hodgkin's lymphoma wherein an accurate diagnosis was made based on histomorphology with an elaborate panel of immunohistochemical markers.

**CASE:** This 12 year old boy presented with a painless right inguinal mass of 10 months duration. Examination revealed solitary right inguinal lymph node of approximately 10cm in diameter with no other significant clinical findings. Radiological investigations (chest X-ray, CT- chest and abdomen) failed to reveal any other significant lymphadenopathy/organomegaly. Histological examination and an elaborate immunohistochemical analysis were performed on lymph node biopsy. The latter was

Department of Pathology (SA, PD, AAK, RR) and Medical Oncology (Lalit Kumar) All India Institute of Medical Sciences, New Delhi, India.

Correspondence to: SHIPRA AGARWAL  
E-mail: doc.shipsaiims@gmail.com

done by means of standard streptavidin-biotin-immunoperoxidase technique using a panel of following fourteen paraffin-reactive antibodies: CD20, CD3, CD5 (Neomarker, USA), CD10, cyclin D1, CD23, bcl-2, bcl-6, kappa, lambda, CD15, CD30, CD68 (KP1) and ki-67.

Histologically the lymph node architecture was seen nearly completely effaced by follicles arranged back to back with scant interfollicular tissue (Fig. 1). The follicles were composed predominantly of small lymphoid cells, two to three times the size of mature lymphocytes, having indented, angulated, and elongated nuclei. The chromatin was coarsely clumped but less dense than that of mature lymphocytes. They had scant cytoplasm. Few large cells having a rim of amphophilic cytoplasm and round nuclei with vesicular chromatin and multiple membrane bound nucleoli were also present. They constituted less than five per high power field of the total neoplastic cell population. These atypical lymphoid cells were intermixed with few mature lymphocytes and eosinophils.

The lesional cells were positive for CD20, bcl-6 (focal), but were negative for CD3, CD5, CD10, CD23, Cyclin D1, bcl-2. The ki-67 proliferation index was low (1.38%). Reactive T cells showed identical pattern of CD3 and CD5 positivity. CD10 was positive in germinal center cells of residual follicles. CD23 revealed nodular pattern of follicular dendritic cells in residual follicles (strong) and also in lesional area (weaker). Results of kappa, lambda, CD68 (KP1), CD15 and CD30 immunostaining were non-contributory. Based on the above findings, a diagnosis of low-grade B-cell non-Hodgkin's lymphoma, not otherwise specified, with eosinophilia was made. The differential diagnoses considered were follicular lymphoma and marginal zone B-cell lymphoma with follicular colonization. However, focal bcl-6 positivity of the neoplastic cells supported the diagnosis of follicular lymphoma. In view of absence of any clinico-radiological evidence of disease elsewhere in the body, a final diagnosis of Follicular non-Hodgkin's lymphoma Grade 1; Ann-Arbor stage I was offered. The patient did not receive any chemotherapy and was advised

close follow-up. He continues to be disease free for the past 39 months, with no evidence of recurrence.

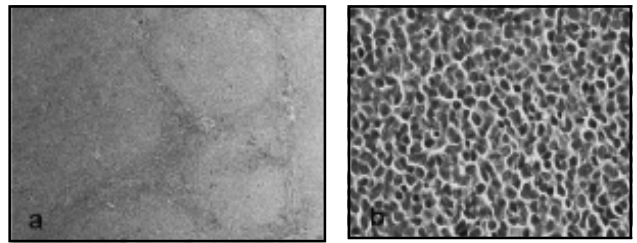


Fig. 1a

Fig. 1b

Photomicrograph demonstrating diffuse effacement of nodal architecture by a lymphoma with prominent follicular pattern and coarsely clumped chromatin (H & E, 40x). Fig 1b: The tumour cells show indented nuclear margins (H & E, 200x).

## DISCUSSION

Follicular lymphoma is rare in pediatric age group. It constitutes about 1% to 2% of all pediatric lymphomas.<sup>7-10</sup> Frizzera and Murphy<sup>8</sup> reported 8 cases out of a total of 318 cases of non-Hodgkin's lymphoma in children; 4 cases had localized peripheral lymphadenopathy at presentation. Five of the patients had stage I or stage II disease, while 3 had stage IV disease. The treatment varied depending on the stage of the disease and the protocol used in the respective treatment center. While 2 patients received only involved field radiotherapy, all others were given a combined modality of treatment, including local or extended field radiotherapy, multi-drug chemotherapy with (in 2 cases) or without surgical excision of the involved organ. All were alive after a median follow-up of 4 years (1 to 14 years) (Table 1). Winberg et al<sup>9</sup> described 14 cases of follicular lymphoma occurring in the first two decades of life, of which 12 cases had adequate follow-up. Eleven of these 12 patients were males. Three cases had extranodal disease at presentation. Seven patients were alive after a median follow-up of 48 months (Table 1). Pinto et al<sup>12</sup> reported 20 cases with a male: female ratio of 3:1 and a median age at the time of diagnosis of 10 years. Seventeen had stage I/II disease, 3 had stage III disease. Faucial tonsils were the primary site in seven cases. The patients were followed up for a period ranging from 6 months to 16 years and all except for one (who died of acute lymphoblastic




Fig 1c: Bcl6 ( 400x).




Fig 1d: Bcl2 (200x)



Fig 1e: CD 20 (200x)

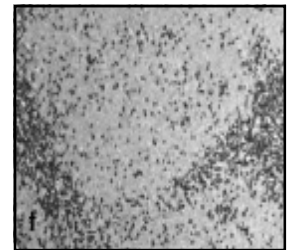


Fig 1f: negative for CD 3 (40x).

**Table 1:**

Authors' (Reference)	Number of cases	Median age at presentation (year)	Sex ratio (M:F)	Number of cases with stage I/II of disease	Number of cases with stage III/IV of disease	Median followup (years)	Alive without disease
Frizzera & Murphy (8)	8	8	3:1	5	3	4	6/8
Winberg et al (9)	12*	15.5	11:1	6	6	2	7/12
Pinto et al (12)	20	10	3:1	17	3	4	19/20
Lorsbach et al (13)	23	11	2.3:1	16/19**	3/19**	9.1	12/13*

\* Cases with available follow-up

\*\* Cases with available presenting clinical features

leukemia 7 years after the initial diagnosis of follicular lymphoma) were in complete remission (Table 1). Another clinico-pathological study conducted by Lorsbach et al<sup>13</sup> included 23 cases; median age being 11 years. As in the other series, there was a male predilection (male: female = 2.3:1) with low stage (stage I) of presentation in most of the cases. Most common sites of involvement were tonsil; inguinal lymph nodes were the primary site in 4 cases. Seventy percent had Grade 2/3 histology. While CD20 and bcl-6 were positive in 100% of the cases; CD 10 was detected in 80 percent of cases; bcl-2 was positive in only 5 of the 16 cases in which it was analyzed immunohistochemically. Rearrangement of bcl-2 gene was detected in 2 of the 16 cases by polymerase chain reaction. Four of the 5 patients with bcl-2 positive tumours were 13 years or older at the time of diagnosis. In

addition, the only 3 patients in this study who had stage III/ IV disease had bcl-2 positive tumours with their age being 13 years or more. Thus, the authors have suggested that though bcl-2 positive follicular lymphoma is rare in young children and adolescents, its expression is not infrequent in older children. In addition, bcl-2 expression has been associated with poorer prognosis. Besides these, there are case reports of follicular lymphoma involving testis as the primary site.<sup>14-16</sup> Finn et al<sup>15</sup> found bcl-6 gene rearrangement in 1 of the 4 cases of pediatric primary testicular follicular lymphomas reported by them, thus proposing a possible role in the pathogenesis of childhood follicular lymphomas. In the present case, the lesional cells were positive for CD 20 and negative for T-cell markers. This feature along with the low ki-67 proliferation index, supports the diagnosis of a

low-grade B-cell lymphoma with a follicular pattern. The differential diagnoses include follicular lymphoma versus marginal zone B-cell lymphoma with follicular colonization. As the neoplastic cells were positive for bcl-6 and the follicular dendritic cell meshwork in the involved follicles was highlighted by CD 23, the diagnosis of follicular lymphoma was offered. They were, however, negative for bcl-2. Since the last two years, the patient in the present case is disease-free without any relapse, despite undergoing only surgical excision of the inguinal lymph node mass. The disease course of the present patient is concordant with that of the available literature where these patients have been reported to present with a low stage of the disease and the clinical course is usually indolent. Chemotherapy does not provide any extra benefit in localized resected disease and the patients must be monitored for progression of the disease before giving any chemotherapy.<sup>7,11,12</sup> The lack of expression of bcl-2 in most cases along with a different clinical course from its adult counterpart suggests a different pathogenesis of childhood follicular lymphoma,<sup>11-16</sup> which still remains undetermined. The role of bcl-6 deregulation in pediatric follicular lymphomas warrants further investigation.

#### REFERENCES:

1. Shad A, Magrath I. Malignant non-Hodgkin's lymphomas in children. In: Pizzo P, Poplack D, eds. *Principles and Practice of Pediatric Oncology*, 3<sup>rd</sup> ed. Philadelphia: Lippincott-Raven 1996;545-587.
2. Shad A, Magrath I. Non-Hodgkin's Lymphoma. *Pediatr Clin North Am*. 1997;44:863-890.
3. Ries LA, Miller RW, Smith M. Cancer in children (ages 0-1 and ages 0-19). In: Miller B, Ries LA, Hankey B, eds. *SEER Cancer Statistics Review 1973-1990*. US Department of Health and Human Services. National Institutes of Health, Bethesda, MD.
4. Naresh KN, Advani S, Adde M, et al. Report of an International Network of Cancer Treatment and Research workshop on non-Hodgkin's lymphoma in developing countries. *Blood Cells, Mols, and Dis*. 2004;33:330-337.
5. Anon. A clinical evaluation of the International Lymphoma Study Group Classification of non-Hodgkin's lymphoma. The non-Hodgkin's lymphoma Classification Project. *Blood*. 1997;89:3909-3918.
6. Sahni CS, Desai SB. Distribution and clinicopathologic characteristics of non-Hodgkin's lymphoma in India: a study of 935 cases using WHO classification of lymphoid neoplasms (2000). *Leuk Lymphoma* 2007;48(1):122-133.
7. Ribeiro RC, Pui CH, Murphy SB, et al. Childhood malignant non-Hodgkin's lymphoma of uncommon histology. *Leukemia* 1992;6(8):761-765.
8. Frizzera G, Murphy SB. Follicular (nodular) lymphoma in childhood: a rare clinical-pathological entity: report of eight cases from four cancer centers. *Cancer* 1979;44:2218-2235.
9. Winberg CD, Nathwani BN, Bearman RM, Rappaport H. Follicular (nodular) lymphoma during the first two decades of life: a clinico-pathologic study of 12 patients. *Cancer* 1981;48:2228-2235.
10. Murphy SB, Frizzera G, Evans AE. A study of childhood non-Hodgkin's lymphoma. *Cancer* 1975;36:2121-2131.
11. Atra A, Meller ST, Stevens RS, et al. Conservative management of Follicular non-Hodgkin's lymphoma in childhood. *Br J Haematol*. 1998;103:220-223.
12. Pinto A, Hutchison RE, Grant LH, Trevenen CL, Berard CW. Follicular lymphomas in pediatric patients. *Mod Pathol*. 1990;3(3):308-313.
13. Lorsbach RB, Shay-Seymore D, Moore J, et al. Clinicopathologic analysis of follicular lymphoma occurring in children. *Blood* 2002;99:1959-1964.
14. Moertel CL, Watterson J, McCormick SR, Simonton SC. Follicular large cell lymphoma of the testis in a child. *Cancer* 1995;75:1182-1186.
15. Finn LS, Viswanatha DS, Belasco JB, et al. Primary follicular lymphoma of the testis in childhood. *Cancer* 1999;85:1626-1635.
16. Lu D, Medeiros J, Eskenazi AE, Abruzzo LV. Primary follicular large cell lymphoma of the testis in a child. *Arch Pathol Lab Med*. 2001;125:551-554.

