

Case Report-V

Supraglottic Carcinoma with Skeletal Muscle and Multiple Bone Secondaries

SURABHI GUPTA, A.K.ARYA, ANUJ KUMAR, SANDEEP CHAUDHARY, BHUPENDRA SINGH CHAUHAN AND ANURAG GUPTA

ABSTRACT

Soft tissue and bone secondaries in supraglottic carcinoma are extremely rare. A 55 year old male presented with history of hoarseness of voice, lump in left side of neck and pain in right shoulder region. Patient underwent Radiotherapy to primary as well as metastatic sites. After 10 months of follow-up, patient presented with distant metastasis to left shoulder, lumbar vertebra and sacrum. This case is being reported on account of its rarity.

INTRODUCTION:

In India, cancer of Head and Neck is common among men with a strong association with smoking/chewing tobacco and alcohol use.² Multiple bony involvements as well as skeletal muscle metastasis is very rare in laryngeal carcinoma.

CASE: A 50-year old male, presented in Sep 2006 with complaints of hoarseness of voice, lump in left side of the neck, pain and swelling over

the right shoulder region, difficulty in swallowing for solids since 6 months. He underwent tracheostomy for difficulty in breathing. Patient was a chronic bidi smoker for about 40 years.

Examination of neck revealed single lymph node of 6X6 cm in size, firm to hard in consistency, in left upper deep cervical chain. Another lymph node was present in right submandibular region of 2X2 cm, hard in consistency and with restricted mobility. There was a swelling, present over right shoulder joint, which caused restricted mobility in abduction (only upto 30°). Direct Laryngoscopic examination revealed an ulcero-proliferative growth involving under surface of left side of epiglottis, left aryepiglottic fold, left vocal cord and left arytenoids. Complete haemogram, liver and renal function tests were normal. Serum alkaline phosphatase and S.calcium was normal. US scan of abdomen revealed bilateral enlarged polycystic kidneys; grade I BPH, Few hepatic cysts. Chest X-Ray (PA view) was within normal limits. MRI of right shoulder showed diffuse enlargement and heterogeneous signal intensity of myofascial planes around right shoulder joint with involvement of deltoid, trapezeus, and supraspinatous and infraspinatous muscles with loss of intervening sharp myofascial planes. Patchy signal alteration was seen along subscapularis muscles.

Department of Radiotherapy (Surabhi Gupta, A.K.Arya, Anuj Kumar, Sandeep Chaudhary, Bhupendra Singh Chauhan) and Department of Pathology (Anurag Gupta) S.N.Medical College, Agra
Correspondence to : **SURABHI GUPTA**
E-mail: mtturabhi@rediffmail.com

Biopsy from the primary site (left arytenoids) revealed poorly differentiated Squamous cell carcinoma (fig 1). Fine Niddle Aspiration Cytology from Right shoulder swelling revealed metastasis from poorly differentiated carcinoma, probably Squamous (fig. 2).

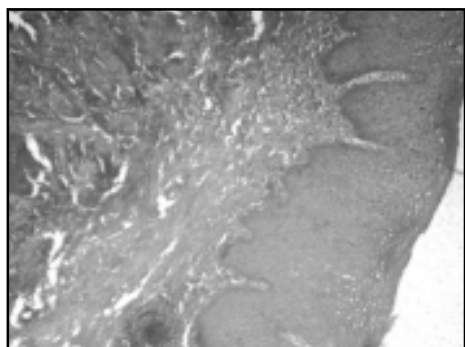


Fig 1: section from laryngeal growth showing poorly differentiated squamous cell carcinoma

Patient was staged as T₃ N₃ M₁ (fig 2). Patient received palliative Radiotherapy 30Gy/10# to right scapular region from 11/08/06 to 24/08/06 for pain. There was complete relief of pain

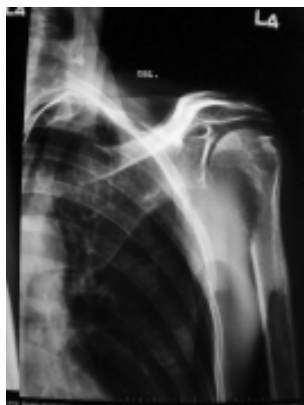

Fig 3: X-ray of left shoulder joint oblique view, showing metastasis

to the involved site. In view of good general condition patient received concurrent chemoradiation in the form of external beam radiotherapy 60Gy/30 Fractions to the primary site and neck nodes and weekly Inj. Cisplatin 50 mg I/V with proper hydration and premedication from 29/08/06 to 06/10/06. There was complete response to the primary site and partial response to lymph node (residual size

was 2x2 cm²) after completion of Radiation. Patient was kept on monthly follow up. Patient was asymptomatic till July 2007, when he presented with pain over left shoulder and right hip joint. X-ray left shoulder joint showed

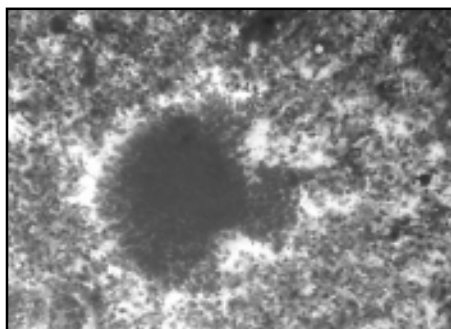


Fig 2: Smear from shoulder swelling showing metastasis from poorly differentiated carcinoma

secondary metastatic deposits (fig 3), for which he further received 30Gy/10Fractions to the involved sites. Patient achieved complete pain

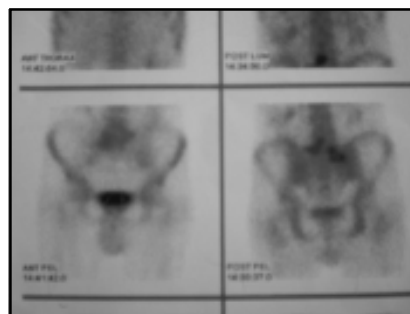


Fig 4: Bone scan showing increase uptake at L4 & L5 vertebra

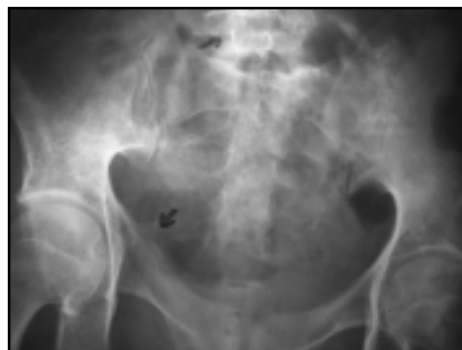

Fig 5: X-ray pelvis showing destruction of sacrum, L4 & L5 vertebra

relief. A follow up bone scan revealed increased uptake at L4 vertebra, transverse process of L5 vertebra, sacrum, right SI joint, right scapular spine and left shoulder joint suggestive of skeletal metastases (fig 4). X-ray of hip joint & pelvis showed destruction of L4, L5 vertebra (fig 5). He was given palliative radiotherapy (30Gy/10 Fractions) to involved vertebrae and pelvic region. This was followed by 6 cycles of Cisplatin and 5-FU based chemotherapy. Presently he is asymptomatic and on follow up.

DISCUSSION

Present case had advanced disease at presentation with poorly differentiated squamous cell carcinoma. Patient had evidence of distant metastasis at initial diagnosis. Serum calcium levels were normal. Distant metastasis from primary head & neck cancer in general and from larynx cancer in particular, are infrequent¹. Patients with advanced disease (stage III-IV), palpable neck nodes (N1-N3), histological evidence of metastatic nodal disease, extracapsular spread, and three or more positive lymph nodes are at greater risk.² Common sites of distant metastasis include- skin, lung, bones and CNS. Very few cases of bone metastasis from primary larynx cancer have been reported in English literature.³⁻⁶ Clinically localized bone pain is the most common symptom. On radiology changes could be - osteolytic, osteosclerotic, or bone fractures, soft-tissue mass, periostitis. Infrequently, hypercalcemia could be associated either due to extensive bone destruction or due to

paraneoplastic (ectopic parathyroid hormone production) mechanism.⁷ Multimodality treatment - radiotherapy and chemotherapy provides good loco-regional control. However, for symptomatic bone metastasis - local radiation provides effective palliation. Present case achieved good response to local radiation and systemic chemotherapy and was asymptomatic more than 10 months at last follow up. Patients with advanced head and neck cancer must be kept on regular follow up and a possibility of distant metastasis must be considered in symptomatic patients.

REFERENCES:

1. Slotman GJ, Mohit T, Raina S, Swaminathan AP, Ohanian M, Rush BF Jr. The incidence of metastases after multimodal therapy for cancer of the head and neck. *Cancer*. 1984;1:54(9):2009-14.
2. Alvi A, Johnson JT. Development of distant metastasis after treatment of advanced-stage head and neck cancer. *Head and Neck*. 1997;19(6):500-5.
3. Loughran CF. Bone metastases from squamous-cell carcinoma of the larynx. *Clin Radiol*. 1983;34(4):447-50.
4. Vize G. Laryngeal metastasis to the temporal bone causing facial paralysis. *J Laryngol Otol*. 1974;88(2):175-7.
5. Choi YS, Yoon YK, Kwak HY, Song IS. Patellar metastasis from a squamous cell carcinoma of the larynx. *AJR Am J Roentgenol*. 2000;174(6):1794-5.
6. Yucel EA, Demirel T, Demiryont M, Egeli U, Deger K. An unusual metastatic site of laryngeal carcinoma: scapular muscles. *J Laryngol Otol*. 2003;117(1):85-7.
7. Penel N, Berthon C, Everard F, et al. Prognosis of hypercalcemia in aerodigestive tract cancers: study of 136 recent cases. *Oral Oncol*. 2005;41(9):884-9.

