

# Melorheostosis with renal arterio-venous malformation: A case report with review of literature

Abdul Rashid Lone,

Mushtaq Ahmad,

Sheikh Aejaaz Aziz,

Gul Mohammad Bhat

Javid Rasool Bhat<sup>1</sup>,

Rifat Jahan,

Shoukat H. Khan<sup>2</sup>

Department of Medical Oncology,

<sup>1</sup>Clinical Hematology, <sup>2</sup>Nuclear  
Medicine, RCC, Sheri Kashmir  
Institute of Medical Sciences,  
Srinagar, Kashmir, India

## Address for correspondence:

Dr. Abdul Rashid Lone,  
Department of Medical Oncology,  
RCC, Sheri Kashmir Institute of  
Medical Sciences,  
Srinagar - 190 011,  
Kashmir, India.  
E-mail: drarlone@yahoo.co.in /  
drarlone@rediffmail.com

## ABSTRACT

Melorheostosis, also known as Leri's disease and flowing periosteal hyperostosis, is a rare cause of pain and stiffness in a limb. The appearance is of "candle greasing" down one side of one or several bones of the body. We describe a case referred to tertiary care center with suspicion of renal cell carcinoma with diffuse bone metastasis. After reassessment, the patient was diagnosed melorheostosis with renal AV malformation. He was reassured about the benign nature of the disease and is asymptomatic.

**Key words:** *Flowing periosteal hyperostosis, Leri's disease, melorheostosis, renal AV malformation*

**DOI:** 10.4103/0971-5851.56336

## INTRODUCTION

Melorheostosis is a rare nongenetic developmental anomaly, first described in 1922 by Leri and Joanny. It can present at any age, and the diagnosis is made by radiography. This skeletal disorder is due to a disturbance of both intramembranous and endochondral bone formations and therefore belongs to a group of "mixed sclerosing bone dysplasias." The prognosis is uncertain; and treatment, symptomatic. Numerous soft-tissue and vascular anomalies have been reported in patients with melorheostosis.

## CASE REPORT

A 42-year-old male patient presented in 2001 with urinary symptoms. His physical examination was unremarkable, with normal pulse and blood pressure. Investigation at presentation revealed a normal hemogram and erythrocyte sedimentation rate (ESR). Fasting blood sugar was 90 mg/dL (normal, 90-110 mg/dL), and kidney functions were normal. Ultrasonography revealed grade one benign

prostatic hyperplasia with multiple cysts in left kidney. Isotopic Renogram done after intravenous injection of 5 milli Curies of Technetium-99m diethylene triamine penta acetic acid (Tc-99m DTPA) under a large field of view Gamma camera revealed a relative renal function of 45% in left kidney and 55% in the right kidney [Figure 1]. The overall scan impression was that of an enlarged left kidney with mild functional impairment. On reevaluation in 2003, his physical examination was unremarkable. Investigations revealed a normal hemogram, normal results of kidney function tests and normal levels of serum and urinary calcium. Parathormone (PTH) levels were within normal limits. Intravenous pyelogram (IVP) revealed a well-defined cystic lesion in the left kidney near pelvicalyceal system causing splashing of pelvis, obstructed calyces and caliectasis. Contrast-enhanced CAT scan of abdomen (CECT) revealed large multiloculated cystic mass arising from left kidney, impinging on pelvis and causing hydronephrosis [Figure 2]. Fine-needle aspiration was inconclusive. Tc-99m Methylene Diphosphonate (MDP) bone scan revealed abnormal tracer uptake in multiple ribs, femur, pelvis, foot bones, tibia and 9<sup>th</sup>, 10<sup>th</sup> and 11<sup>th</sup> dorsal vertebrae [Figure 3]. Hemogram and

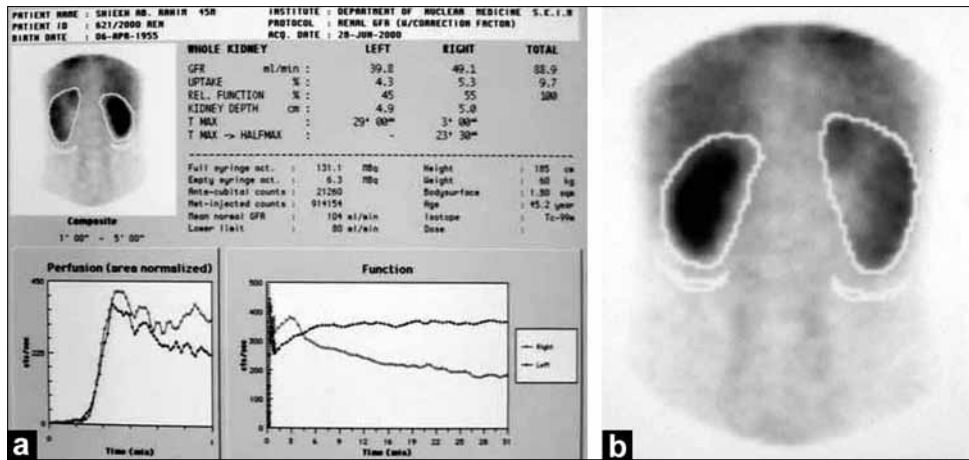


Figure 1: (a) Tc-99m DTPA renogram (PA). Tc-99m DTPA renogram (AP); (b) Tc-99m DTPA renogram (AP)

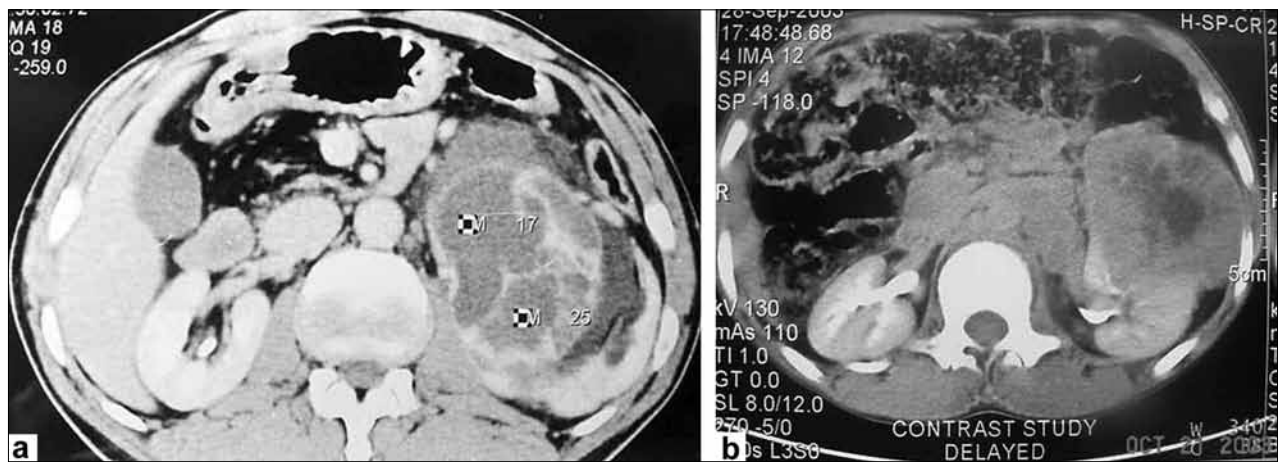


Figure 2: CECT (a,b) revealed a large multiloculated cystic mass arising from left kidney, impinging upon the pelvis and causing hydronephrosis

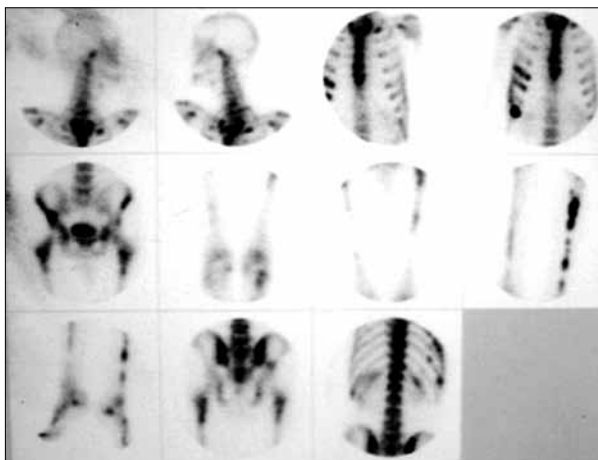


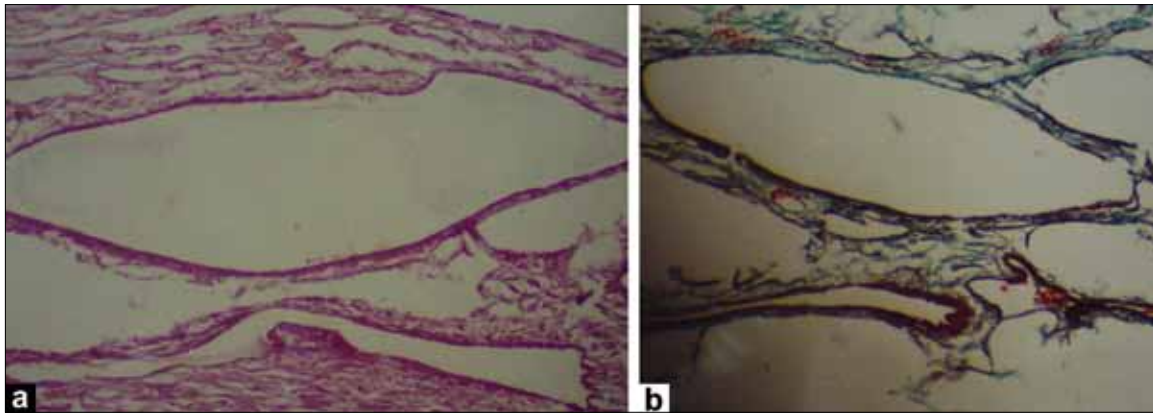
Figure 3: TC-99m MDP bone scan

serum chemistry were normal. Left radical nephrectomy was done in April 2003. Operative findings revealed a mass involving left kidney, with hydronephrotic changes. Histopathological examination (HPE) revealed arterial malformation of kidney [Figure 4]. Patient was referred to tertiary care center with an impression of renal cell

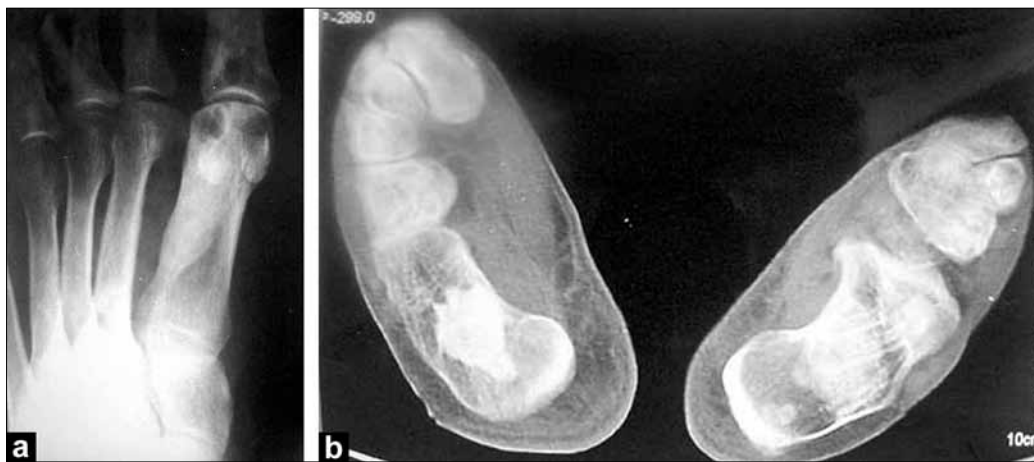carcinoma with diffuse bone metastasis. He was reevaluated and found to have high serum alkaline phosphatase (Alp) levels. In view of the long history, good performance status and histopathological examination, skeletal survey was done, which revealed hyperostosis of long bones, and the bone of foot resembling wax dripping on one side [Figure 5]. A final diagnosis of melorheostosis was made and the patient reassured. He is on our follow-up for the last 5 years and is asymptomatic.

## DISCUSSION

Melorheostosis is a rare nongenetic developmental anomaly. The name is derived from the Greek words *melos*, meaning limb; and *rhein*, meaning to flow. Its etiology is unknown, patients present at any age and both sexes are affected equally. It affects mainly the long bones; but in some cases, also short bones of the hands and feet; and rarely, the axial skeleton.<sup>[1,2]</sup> The appearance is of “candle greasing” down one side of one or several of the bones of one half of the body.<sup>[3]</sup> Although changes mainly affect cortex, sclerotic changes may extend into the spongiosa of bones. Bone



**Figure 4:** (a) Arteriovenous anomaly: Tangle of abnormal muscularized arteries and ectatic veins without intervening capillaries (H and E,  $\times 400$ ); (b) Masson's trichrome showing abnormal muscularized and fibrotic arterial walls (MTC,  $\times 400$ )



**Figure 5:** (a, b) Irregular, hyperosteotic changes of cortex, resembling melting wax dripping on the side of a candle. Dense sclerotic linear areas are seen, mainly in the cortex

scintigraphy is positive and shows moderately increased tracer uptake.<sup>[4]</sup> The skeletal disorder is due to a disturbance of both intramembranous and endochondral bone formations and therefore belongs to the group of “mixed sclerosing bone dysplasias,” a classification proposed by Greenspan.<sup>[5,6]</sup> Melorheostosis is found to be associated with anomalies of blood or lymph vessels in 5% to 17% of cases.<sup>[7,8]</sup> Remarkably vascular anomalies have been always reported to be ipsilateral and have included capillary dysplasia, vascular nevi, arteriovenous shunts, varices, lymphactesia, aneurysms and glomangiosomas, renal artery stenosis, aortic valve insufficiency.<sup>[8-12]</sup>

The etiology and pathogenesis of melorheostosis are unknown. Two major hypotheses exist: First, the bony lesions have been ascribed to sclerotomes, which are areas of sensory innervations of skeleton<sup>[13]</sup> and second, the bony lesions are proposed to originate from a postzygotic mutation occurring during embryogenesis.<sup>[14,15]</sup> Histopathology of the bone specimen reveals nonspecific hyperostotic, mainly lamellar, bone formation.<sup>[16]</sup>

Isolated cases of malignancy have been reported in association with melorheostosis - one case of osteosarcoma and one of malignant fibrous histiocytoma. At least, one death has been reported due to complications of this disease, due to resistant pleural effusion secondary to associated vascular malformation. The clinical course is slowly progressive. Severe symptoms may require treatment by sympathectomy or even amputation.<sup>[17]</sup>

## REFERENCES

1. Léri A, Joanny J. Une affection non décrite des os: Hyperostose “en coulée” sur toute la longueur d’un membre ou “melorhéostose”. *Bull Mem Soc Hop Paris* 1922;46:1141-5.
2. Greenspan A, Azouz EM. Bone dysplasia series: Melorheostosis: Review and update. *Can Assoc Radiol J* 1999;50:324-30.
3. Patrick JH. Melorheostosis associated with arteriovenous aneurysm of the left arm and trunk: Report of a case with long follow-up. *J Bone Joint Surg Br* 1969;51:126-9.
4. Greenspan A, Azouz EM. Melorheostosis: Review and update. *Can Assoc Radiol J* 1999;46:1141.
5. Greenspan A. Sclerosing bone dysplasias: A target-site approach. *Skeletal Radiol* 1991;20:561-83.
6. Vanhoenacker FM, de Beuckeleer LH, van Hul W, Balemans W,

- Tan GJ, Hill SC, *et al.* Sclerosing bone dysplasias: Genetic and radio clinical features. *Eur Radiol* 2000;10:1423-33.
7. De Goede E, Fagard R, Fryns JP. Unique cause of Reno vascular hypertension: Melorheostosis associated with a malformation of the renal arteries. *J Hum Hypertens* 1996;10:57-9.
  8. Ingen-Housz-Oro S, Chigot V, Hamel-Teillac D, Brunelle F, De Prost Y. Melorheostosis associated with arteriovenous malformation of the ear. *Ann Dermatol Venereol* 2001;128: 915-8.
  9. Hall R. A case report melorheostosis with cutaneous haemangioma and lymphatic vesicles. *J Bone Joint Surg Br* 1961;43:335-7.
  10. Ewald FC. Unilateral mixed sclerosing bone dystrophy associated with unilateral lymphangiectasis and capillary hemangioma: A case report. *J Bone Joint Surg Am* 1972;54:878-80.
  11. Kessler HB, Recht MP, Dalinka MK. Vascular anomalies in association with osteodystrophies: A spectrum. *Skeletal Radiol* 1983;10:95-101.
  12. Roger D, Bonnet Blanc JM, Leroux-Robert C. Melorheostosis with associated minimal change nephrotic syndrome, mesenteric fibromatosis and capillary haemangiomas. *Dermatology* 1994; 188:166-8.
  13. Murray RO, McCredie J. Melorheostosis and the sclerotomes: A radiological correlation. *Skeletal Radiol* 1979;4:57-71.
  14. Fryns JP. Melorheostosis and somatic mosaicism. *Am J Med Genet* 1995;28:199.
  15. Youssoufian H, Pyeritz RE. Mechanisms and consequences of somatic mosaicism in humans. *Nat Rev Genet* 2002;3: 748-58.
  16. Tinschert S, Stein A, Goldner B, Dietel M, Happle R. Melorheostosis with ipsilateral nevus sebaceus (didymosis melorheosebacea). *Eur J Dermatol* 2003;13:21-4.
  17. Meloreostosis, Leri's disease, flowing periosteal hyperostosis. Bullough and Invigorita, *Atlas of Orthopaedic Pathology*, 1<sup>st</sup> ed. University Park Press Greenfield and Arrington, Imaging of Bone tumors, Lippencott; 1995.

**Source of Support:** Nil, **Conflict of Interest:** None declared.