Article published online: 2021-08-06

Extra-axial cerebello pontine angle medulloblastoma: A rare site of tumor

Sir,

Medulloblastoma is a common tumor of the posterior fossa, representing 20–25% of all pediatric neoplasms.[1] The tumor often occurs in the cerebellar vermis and at the apex of the fourth ventricle.[1,2] There are only a few reported cases of cerebellopontine (CP)-angle medulloblastoma in the literature, with most being intra-axial. The extra-axial site of this tumor remains a rarity.[1,3]

This 4-year-old girl presented with left hemicranial headache followed by facial asymmetry with deviation of angle of mouth for 1 month. There was no other significant history.

On clinical examination, higher intellectual functions were normal, both pupils were equal and reacting to light, visual acuity/visual fields were normal, fundus–no papilloedema, left lower motor neuron facial paresis, and left-sided sensory neural hearing loss, other cranial nerves normal. No stigmata of neurofibromatosis was noted. A computerised tomography (CT) scan of the brain showed contrast enhancing extra-axial lesion in the left CP angle centered around internal acoustic meatus [Figure 1]. CT bone window did not show enlargement of the internal acoustic meatus or hyperostosis [Figure 1]. Magnetic resonance imaging (MRI) of the brain showed CP angle lesion which was hypointense on T1W and hyperintense on T2W image [Figure 2]. The lesion was brilliantly enhancing with contrast, and no dural tail or canalicular component noticed [Figure 3]. She underwent left retromastoid craniectomy and total excision of the lesion. It was grayish, moderately vascular, and soft. There was a clear plane between the tumor and cerebellum, whereas it was adherent to dura and tent laterally. The HPE was confirmed as desmoplastic medulloblastoma [Figure 4] with the high MIB-1 labeling index and S-100 negativity.

Medulloblastoma usually occurs in inferior medullary velum in the midline.[2] However rarely it may occur laterally in the cerebellar hemisphere in the pediatric and adult age group[1,3-5] with most being intra-axial. The extra-axial site of this tumor remains a rarity.[1,3] Origin of medulloblastoma may be either from germinal cells or their remnants situated at the end of the posterior medullary velum or from remnants of the external granular layer.[3,6] Their development in the CPA may be from the remnants of the external granular layer in the cerebellar hemisphere, including the flocculus which faces the CP

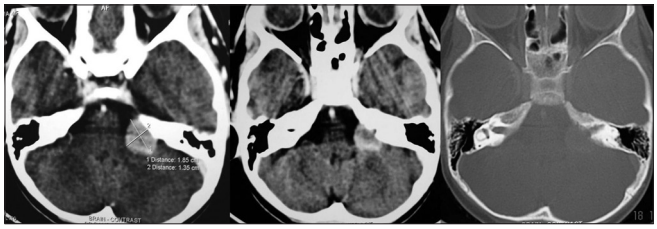

Figure 1: CT scan brain plain with contrast shows left extra-axial contrast enhancing lesion

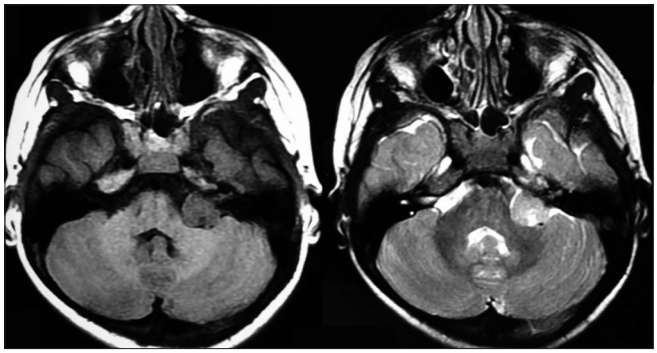

Figure 2: MRI of the brain showed the CP angle lesion which was hypointense on T1W and hyperintense on T2W image

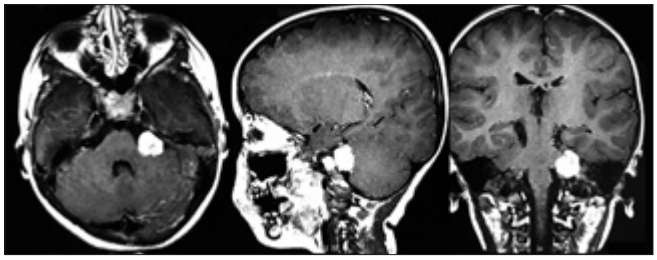

Figure 3: MRI of the brain contrast study axial, sagital, and coronal section shows contrast enhancing extra-axial lesion

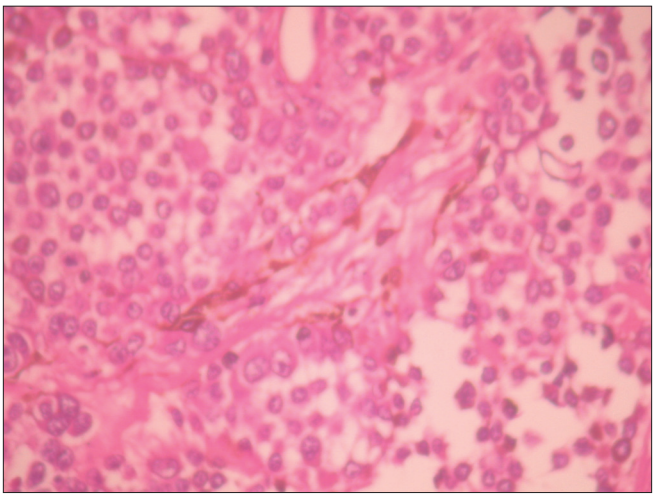

Figure 4: HPE suggestive of desmoplastic medulloblastoma

angle.[3,6] In the CP angle, medulloblastomas though fifth, sixth, and eighth cranial nerves are frequently involved, these nerves were spared in this patient.[5,7] CP angle medulloblastomas are very rare with nearly 36 cases published in the literature[1,3,5] of which only 10 are in adults.[1,3,5,7] The lack of association with any cerebellar tissue and the extra-axial location of the tumor made our patient's case quite rare. However, they are likely under-reported owing to publication bias and must be considered in the differential diagnosis of extra-axial CP angle lesions.

Goutham Cugati, Manish Singh, Nigel Peter Symss, Anil Pande, Vasudevan Madabushi Chakravarthy, Ravi Ramamurthi

Department of Neurosurgery, Voluntary Health Services, Adyar, Chennai, Tamil Nadu, India

Address for correspondence:
Dr. Manish Singh,
Department of Neurosurgery
Voluntary Health Services, Adyar,
Chennai - 600113, Tamil Nadu, India
E-mail: manish007singh@yahoo.com

REFERENCES

1. Fallah A, Banglawala SM, Provias J, Jha NK. Extra-axial medulloblastoma in the cerebellopontine angle. Can J Surg 2009;52:E101-2.
2. Mohan M, Pande A, Vasudevan MC, Ramamurthi R. Pediatric medulloblastoma: A review of 67 cases at a single institute. Asian J Neurosurgery 2008;2:63-69.
3. Singh M, Cugati G, Symss NP, Pande A, Vasudevan MC, Ramamurthi R. Extra axial adult cerebellopontine angle medulloblastoma: An extremely rare site of tumor with metastasis. Surg Neurol Int 2011;2:25.
4. Available from: http://www.surgicalneurologyint.com/text.asp?2011/2/1/25/77178 [Last Cited on 2011 Feb 26].
5. Hubbard JL, Scheithauer BW, Kispert DB, Carpenter SM, Wick MR, Law ER Jr. Adult cerebellar medulloblastomas: The Pathological radiological and clinical disease spectrum. J Neurosurg 1989;70:536-44.
6. Kumar R, Bhowmick U, Kalra SK, Mahapatra AK. Pediatric cerebellopontine angle medulloblastomas. J Pediatr Neurosci2008;3:127-30.
7. Stevenson L, Echlim F. Nature and origin of some tumors of cerebellum: Medullobastoma. Arch Neurol Psychiatry 1934;31:93-109.
8. Jaiswal AK, Mahapatra AK, Sharma MC. Cerebelloponitne angle medulloblastoma. J Clin Neurosci 2004;11:42-5.

Access this article online

Quick Response Code:

Website: www.ijmpo.org

DOI: 10.4103/0971-5851.89801

Conference Announcement

Round Table Meeting on

"Targeted therapy in Malignancy: Where Future is!"

on 12th Nov 2011 at the AIIMS, New Delhi.

Contact Persons
Dr. Lalit Kumar, Organizing Secretary, Email: lalitaiims@yahoo.com,
Jose Pulickal, Email: Jose.pulickal@ranbaxy.com