

or transient bisalbuminemia have been described in various pathological conditions including diabetes mellitus, Waldenström's macroglobulinemia, multiple myeloma, sarcoidosis, Alzheimer's disease, pancreatic pseudocyst, nephrotic syndrome, chronic kidney disease, and also in patients receiving high doses of penicillin.^[1-5] Bisalbuminemia is an infrequent finding among Indians; we report three cases of bisalbuminemia of the "slow" variant which were incidentally discovered on screening serum samples for protein electrophoretic studies in last 6 months.

The first case is a 65-year-old female patient of type II diabetes mellitus (DM) who presented with neuropathy, nephropathy, nonproliferative retinopathy, and right diabetic foot. The second case is a 50-year-old male patient of type I DM who presented with chronic inflammatory demyelinating neuropathy. The third patient presented with mild fever, arthralgia, and bone pains and referred for investigation of multiple myeloma. Serum protein electrophoresis was performed with an automated rapid agarose gel electrophoresis system (SAS-1 Serum Protein SB, Helena Biosciences, Europe). Serum electrophoresis revealed two distinct albumin bands at anodic end [Figures 1 and 2]. The bands were of unequal relative amounts in all cases. New albumin variant bands had slower mobility compared to normal albumin. The slow and normal bands constituted for 20.4 and 25.7% of total serum proteins in first case, 28.6 and 25.5% in second case, and 25.5 and 28.7% in third case, respectively. In addition, first case also showed bisalbuminuria. Bisalbuminemia was noted as an incidental finding in all three cases on serum protein electrophoresis. The patients' serum samples were reexamined and remained bisalbuminemic 1 month after their first visit.

First case of bisalbuminemia was reported in a diabetic German in 1955. Since then, a variety of mutations and polymorphisms have been reported in literature. So far, there are 77 known mutations of the serum albumin gene, with 65 of them resulting in bisalbuminemia.^[5] The acquired (or transient) form of bisalbuminemia has been found in patients receiving high doses of b-lactam antibiotics or suffering by pancreatic disease, usually complicated with ruptured pseudocysts. Hereditary bisalbuminemia, transmitted as an autosomal codominant character, is a relatively rare genetic disorder (occurring with a cumulative frequency of 1:1000-1:10,000) that is usually revealed by chance.^[2] The causative genetic lesion is a point mutation of human serum albumin gene.

Albumin variations, either acquired or inherited, should always be on the radar of both clinicians and research scientists. Such new forms can possibly provide data

Bisalbuminemia: A Rarely Encountered Protein Anomaly

Sir,

Bisalbuminemia or alloalbuminemia is an inherited or acquired, rarely encountered serum protein anomaly, characterized by the occurrence of bicuspid electrophoretic pattern in the albumin fraction detected on serum electrophoresis. It can be seen in densitometry as a bifid mountain where albumin has two heads. These albumin mutants also called alloalbumins either have increased electrophoretic mobility (fast type variants) or decreased mobility (slow type variants).^[1] The presence of acquired

Address for correspondence:
 Dr. Seema Chhabra,
 E-mail: drseemachhabra@gmail.com

REFERENCES

1. Kobayashi S, Okamura N, Kamoi K, Sugita O. Bisalbumin (fast and slow type) induced by human pancreatic juice. *Ann Clin Biochem* 1995;32:63-7.
2. Šimundić A, Miler M, Nikolac N, Topić E, Čaržavec D, Milanović B, *et al.* Bisalbuminemia in a male Croatian patient with sarcoidosis. *Biochemia Medica* 2009;19:95-100.
3. Ejaz AA, Krishna M, Wasiluk A, Knight JD. Bisalbuminemia in chronic kidney disease. *Clin Exp Nephrol* 2004;8:270-3.
4. Kalambokis G, Kitsanou M, Kalogera C, Kolios G, Seferiadis K, Tsianos E. Inherited bisalbuminemia with benign monoclonal gammopathy detected by capillary but not agarose gel electrophoresis. *Clin Chem* 2002;48:2076-7.
5. Shetty JK, Prakash M, Gopalakarishna K. Bisalbuminemia in adult male with Alzheimer's disease. *Indian J Med Sci* 2007;61:356-7.

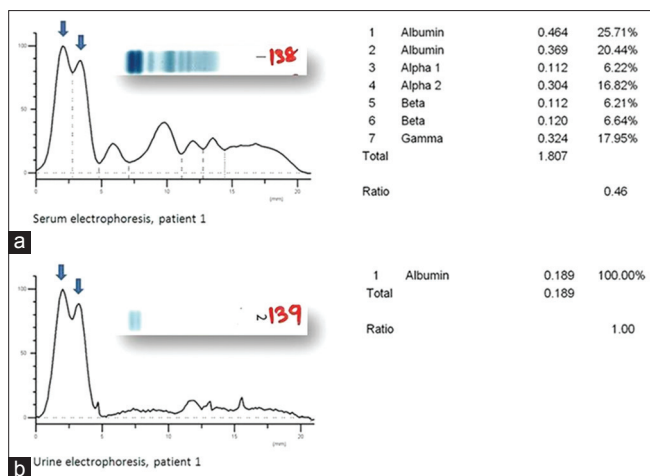


Figure 1: Densitometer tracing showing two peaks in the albumin region (a) on serum electrophoresis (b) on urine electrophoresis from patient 1. Inset showing gel electrophoresis picture

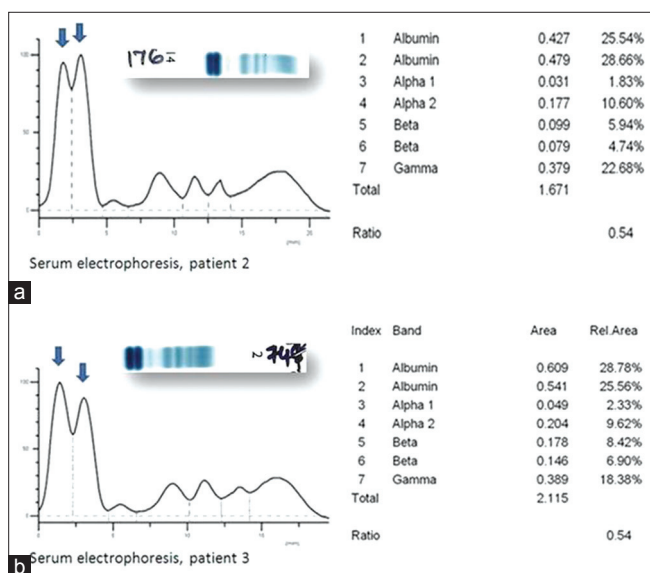



Figure 2: Densitometer tracing showing two peaks in the albumin region on serum electrophoresis from (a) patient 2 and (b) patient 3. Inset showing gel electrophoresis picture

on protein evolution and on the molecular structure and characteristics of the albumin molecule. Acquired bisalbuminemia could point to an underlying disease process, such as pancreatic pseudocysts, providing a clinician with another clue towards a possible diagnosis. Studying albumin variants can be of great interest and might be helpful in estimating the geographic distribution of these variants which is again important from anthropology point of view.

**Seema Chhabra, Frainey Bansal,
 Biman Saikia, Ranjana Walker Minz**

Department of Immunopathology, Post Graduate Institute of
 Medical Education and Research, Chandigarh, India

Access this article online

Quick Response Code: 	Website: www.jlponline.org
	DOI: 10.4103/0974-2727.119869