

Urinary Tract Infection Due to *Paenibacillus alvei* in a Chronic Kidney Disease: A Rare Case Report

Sanghamitra Padhi, Muktikesh Dash, Rani Sahu, Pritilata Panda

Department of Microbiology, Maharaja Krishna Chandra Gajapati Medical College and Hospital, Berhampur, Odisha, India

Address for correspondence: Dr. Sanghamitra Padhi, E-mail: padhisanghamitra@yahoo.in

ABSTRACT

Paenibacilli, the Gram positive, aerobic spore bearing bacilli are found normally in the environment. Though these organisms were not known to cause human disease, until recently; few species of this genus have been reported to cause infections in humans. We report here, a case of urinary tract infection in a 60-year-old chronic kidney disease patient due to this rare bacterium. The patient presented with complains of fever, dysuria, and flank pain. Routine and microscopic examination of urine revealed no abnormality except plenty of pus cells and albumin (1+). Bacterial culture showed significant bacteriuria and the isolated bacteria was identified to be *Paenibacillus alvei* based on standard biochemical reactions.

Key words: Chronic kidney disease, *Paenibacillus alvei*, urinary tract infection

INTRODUCTION

Paenibacillus is a genus of aerobic, Gram-positive bacilli, originally included in the genus *Bacillus* has been separated from it based on phylogenetic studies using 16S rRNA gene.^[1] Several species of *Paenibacillus* have been reported to cause human infections like *Paenibacillus alvei* in prosthetic hip infections, cellulitis, and endophthalmitis;^[2-4] *P. macerans* in brain abscess, catheter associated infection, and wound infection;^[5,6] *P. polymyxa* in bacteremia.^[7]

We now report a case of urinary tract infection in a chronic kidney disease patient caused by *Paenibacillus alvei*, which to the best of our knowledge is first to be reported.

CASE REPORT

The patient is a 60-year-old male, farmer by occupation, residing in a village complained of

dysuria and fever for which he consulted the local physician. He was advised to do the minimum available investigations, which showed fasting blood sugar 81 mg/dL; hemoglobin (Hb) 9.6 gm/dL; and total leukocyte count 11,200 cells/mm³. His differential count revealed increased percentage of neutrophil (85%). Routine and microscopic examination of urine showed presence of albumin (1+), plenty of pus cells, and 2-3 epithelial cells per high power field. Based on this report, the patient was advised oral administration of Norfloxacin 400 mg twice daily for 7 days. But 12 days later, patient complained of right side flank pain and increased intensity of fever for last 8 days. So he was referred to the tertiary care hospital for consultation, where different investigations were carried out. Ultrasonography of abdomen revealed hypoplastic right kidney [Figure 1]. Serum urea and creatinine levels were 56 and 1.3 mg/dL, respectively. The patient was diagnosed as a case of chronic kidney disease and his urine sample was sent to the Department of Microbiology for different investigations. Routine and microscopic examination of urine revealed presence of albumin (1+), plenty of pus cells, 1-2 epithelial cells per high power field. Bacteriological culture of urine showed significant bacteriuria (10⁵ cfu/ml) and the colonies [Figure 2] were moist, glossy with an unpleasant odor. Gram

Access this article online	
Quick Response Code: 	Website: www.jlponline.org
	DOI: 10.4103/0974-2727.119872

staining of colonies detected presence of Gram-positive bacilli bearing ellipsoidal, subterminal spores [Figure 3]. By standard biochemical reactions, the isolate was identified as *Paenibacillus alvei*.^[8] A repeat culture of the urine sample was performed to confirm its isolation. The isolate was sensitive to ampicillin, amikacin, nitrofurantoin, cefotaxime, cefixime, and resistant to norfloxacin. Hence, the patient was administered with intravenous injection of 1 g of cefotaxime 8-hourly for 7 days. Then a repeat urine culture was performed which was found to be bacteriologically sterile.

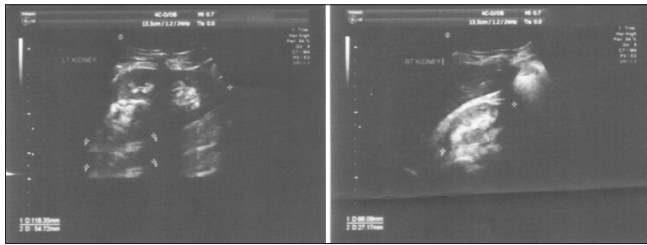


Figure 1: Ultrasonography showing hypoplastic kidney

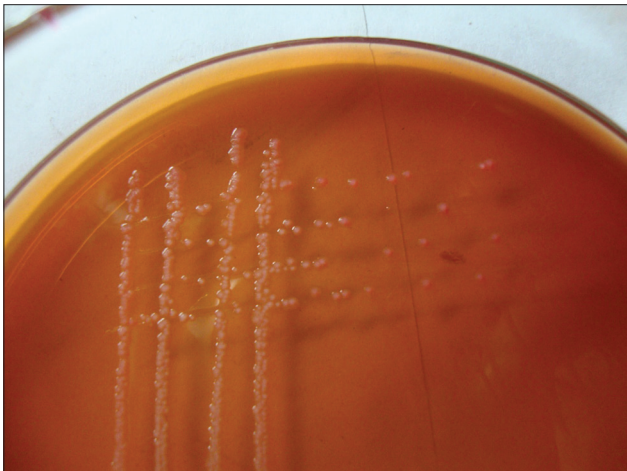


Figure 2: Growth and isolation of bacteria on the culture plate

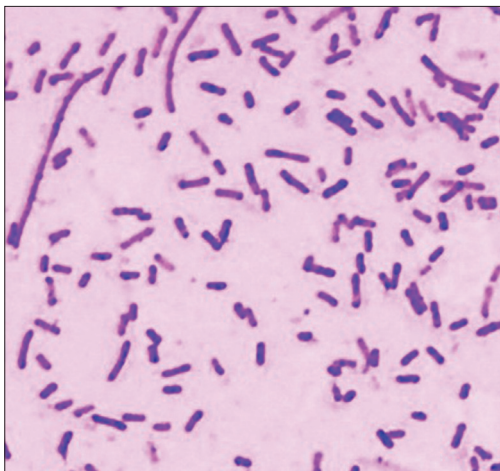

Figure 3: Gram staining showing subterminal spore in Gram-positive bacilli

DISCUSSION

Paenibacillus, a genus of Gram positive, facultative an aerobic, endospore forming bacteria, belongs to the family *Paenibacillaceae*. The name *paeni* has been derived from the latin word *paene* which means almost and so the *Paenibacilli* are literally almost Bacilli. Because of highly conserved genome encoding their 16S rRNA which differs from that of *Bacillus*, they were included in a novel genus called *Paenibacillus* which consists of more than 90 species. Many species of this genus have already been isolated from clinical samples among which *Paenibacillus alvei* is the commonest one. *P. alvei* has also been isolated from life threatening conditions like meningitis and pneumonitis.^[9,10] *P. alvei* originally isolated from honeycomb of bees and later on from soil, is found to produce thiol-activated cytolyins which might be responsible for its virulence.

In our case, elevated neutrophil count and plenty of pus cells in microscopic examination of urine, on two occasions, in a febrile patient was indicative of urinary tract infection. In addition to this isolation of *P. alvei* from urine culture, from a chronic kidney disease patient, and bacteriological sterile urine after 7 days of antimicrobial administration is sufficient enough to say that the urinary tract infection was due to *P. alvei*.

Cultures showing isolation of Gram-positive spore bearing bacilli are in general considered as contaminants as they are ubiquitous in nature. But isolation of these bacilli in pure form, that to in any preexisting disease condition and immunocompromised conditions should not be neglected and be processed for identification to reduce the morbidity and mortality of the patients.

REFERENCES

1. Ash C, Priest FG, Collins MD. Molecular identification of rRNA group 3 bacilli (Ash, Farrow, Wallbanks and Collins) using a PCR probe test. Proposal for the creation of a new genus *Paenibacillus*. *Antonie Van Leeuwenhoek* 1993;64:253-60.
2. Reboli AC, Bryan CS, Farrar WE. Bacteremia and infection of a hip prosthesis caused by *Bacillus alvei*. *J Clin Microbiol* 1989;27:1395-6.
3. Shin JH, Sung SK, Shim JD, Kim HR, Park SW, Lee JN. A case of *Paenibacillus alvei* cellulitis in immune-competent patient. *Korean J Lab Med* 2005;25:53-5.
4. Antonello A, Weinstein GW. Successful treatment of *Bacillus alvei* endophthalmitis. *Am J Ophthalmol* 1989;108:454-5.
5. Bert F, Ouahes O, Lambert-Zechovsky N. Brain abscess due to *Bacillus macerans* following a penetrating periorbital injury. *J Clin Microbiol* 1995;33:1950-3.
6. Barrero F, Galán F, Marín P, García-Martos P, Capote FJ. Catheter associated infection by *Bacillus macerans* in a patient with acute leukemia. *Enferm Infecc Microbiol Clin* 1996;14:628-9.
7. Nasu Y, Nosaka Y, Otsuka Y, Tsuruga T, Nakajima M, Watanabe Y, *et al.* A case of *Paenibacillus polymyxa* bacteremia in a patient with cerebral infarction. *Kansenshogaku Zasshi* 2003;77:844-8.

8. Logan NA. Bacillus anthracis, Bacillus cereus, and other aerobic endospore-forming bacteria, In: Borriello SP, Murray PR, Funke G, editors. Topley and Wilson's Microbiology and Microbial Infections. 10th ed. ASM Press, Hodder Arnold; 2005. p. 922-52.
9. Park SJ, Cong W, Lee SY. Bacterial and fungal species from cerebrospinal fluid in the past five years. Korean J Pathol 1976;10:137-42.
10. Coudron PE, Payne JM, Markowitz SM. Pneumonia and empyema infection

associated with a Bacillus species that resembles B. alvei. J Clin Microbiol 1991;29:1777-9.

How to cite this article: Padhi S, Dash M, Sahu R, Panda P. Urinary tract infection due to *Paenibacillus alvei* in a chronic kidney disease: A rare case report. J Lab Physicians 2013;5:133-5.

Source of Support: Nil. **Conflict of Interest:** None declared.

Announcement

iPhone App



A free application to browse and search the journal's content is now available for iPhone/iPad. The application provides "Table of Contents" of the latest issues, which are stored on the device for future offline browsing. Internet connection is required to access the back issues and search facility. The application is Compatible with iPhone, iPod touch, and iPad and Requires iOS 3.1 or later. The application can be downloaded from <http://itunes.apple.com/us/app/medknow-journals/id458064375?ls=1&mt=8>. For suggestions and comments do write back to us.