

# Molecular Characterization of Methicillin-Resistant *Staphylococcus aureus* Causing Fatal Purulent Pericarditis

Vasudevan Anil Kumar, Nair Nisha<sup>1</sup>, Rajesh Thachathodiyl<sup>2</sup>, Aswathy Nandakumar, Kavitha R Dinesh, Eileen Thatcher, Shamsul Karim, Raja Biswas<sup>1</sup>

Departments of Microbiology, <sup>1</sup>Center for Nanoscience and Molecular Medicine, <sup>2</sup>Cardiology, Amrita Institute of Medical Sciences, Ponekara, Kerala, India

**Address for correspondence:** Dr. V Anil Kumar, E-mail: vanilkumar@aims.amrita.edu

## ABSTRACT

Though pericardial disease is common in patients with renal disease, purulent pericarditis is very rare. We report a fatal case of purulent pericarditis and sepsis due to methicillin-resistant *Staphylococcus aureus* in a 78-year-old male with systemic hypertension and renal disease along with the molecular characterization of its resistant mechanism.

**Key words:** Methicillin-resistant *Staphylococcus aureus*, multi-drug resistant, purulent pericarditis

## INTRODUCTION

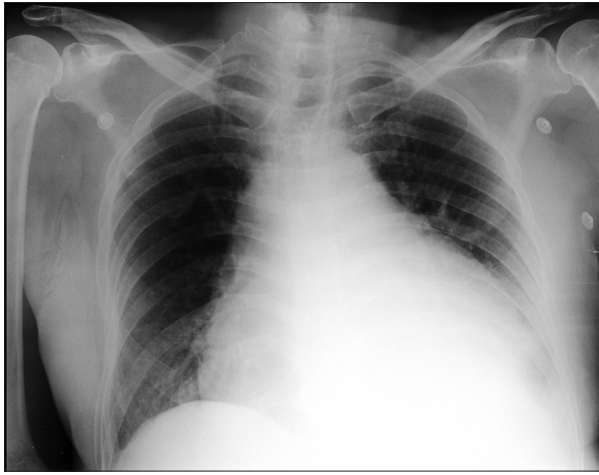
Inflammation of the pericardium due to infection or non-infectious etiology is known as pericarditis. The most common forms are idiopathic and viral which are usually self-limiting and benign conditions. In contrast without treatment mortality in purulent pericarditis approaches 100%.<sup>[1]</sup> Predisposing factors include renal disease, previous cardiac and thoracic surgery, endoscopic oesophageal variceal sclerotherapy, laposcopic nissins fundoplication, fiberoptic bronchoscopy and percutaneous coronary angioplasty<sup>[2]</sup> The portal of entry is usually direct invasion of infection from adjacent pneumonia or empyema and to a lesser extent may be due to hematogenous seeding from a distant infection. We report a fatal case of acute purulent pericarditis due to methicillin-resistant *Staphylococcus aureus* (MRSA) with molecular characterization of its resistance mechanisms.

## CASE REPORT

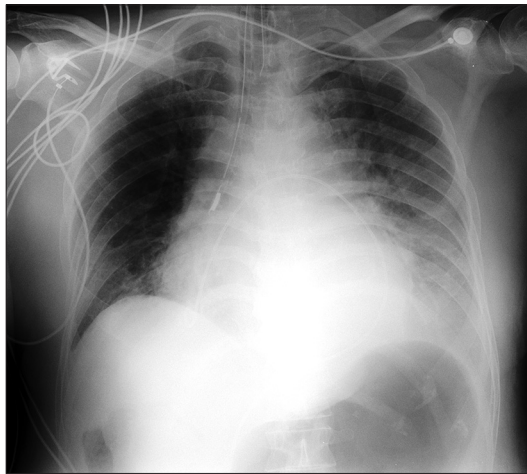
A 78-year-old male who was a known case of squamous cell carcinoma of buccal mucosa, which was excised with cervical lymph node dissection two years ago along with systemic hypertension and renal failure (Urea 179 mg/dl, Creatinine 5.28 mg/dl) was hospitalized with complaints of fever since 10 days and dyspnoea on exertion class III of two days duration. A chest X-ray [Figures 1 and 2] showed massive pericardial effusion and an electrocardiogram (ECG) [Figure 3] revealed low voltage waves, ST elevation, atrial fibrillation and a fast ventricular rate. The white cell count was 21 K/ $\mu$ l with 88% neutrophils and liver enzymes were also elevated (SGOT 103 IU/L, SGPT 80 IU/L). The patient developed cardiac tamponade. Emergency pericardiocentesis was done and 800ml of fluid was drained and a pigtail catheter was introduced through a subxiphoid incision and placed under fluoroscopic guidance in the pericardial cavity. Pericardial fluid analysis showed ADA 15.2 U/L, glucose 97.8 g/dl, protein 5.84 g/dl.

Blood and pericardial fluid cultures grew Gram positive cocci which were identified as MRSA with the Vitek 2 (BioMerieux, Inc., Durham, NC). Both the MRSA isolates (from blood and pericardial fluid)

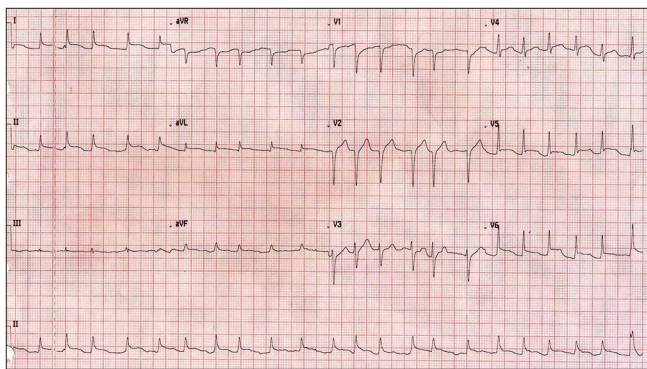
Access this article online	
<b>Quick Response Code:</b> 	<b>Website:</b> <a href="http://www.jlponline.org">www.jlponline.org</a>
	<b>DOI:</b> 10.4103/0974-2727.119874



**Figure 1:** Chest X-ray on admission showing a massive pericardial effusion with a pig-tail catheter *in situ* for drainage



**Figure 2:** Chest X-ray after pericardiocentesis showing a pig-tail catheter left *in situ* for continuous drainage



**Figure 3:** Electrocardiogram on admission showing low voltage waves in leads II, III and aVF; ST elevation in leads I, II, aVL and chest leads V1 – V6; atrial fibrillation and a fast ventricular rate of 134 beats/min

were resistant to multiple classes of antibiotics namely oxacillin, penicillin, trimethoprim-sulfamethoxazole, gentamicin and ciprofloxacin while susceptible to vancomycin, clindamycin, tetracycline, linezolid,

quinupristin/dalfopristin, nitrofurantoin, and rifampicin as determined by Vitek 2 system. Vancomycin (1 µg/ml) and daptomycin (0.94 µg/ml) susceptibility was confirmed by Etest (BioMerieux, Inc., Durham, NC). The isolate was intermediately sensitive to erythromycin (1 µg/ml) and a D-test for inducible clindamycin resistance was found to be negative. The MRSA isolate from blood and pericardial fluid were identical and identification was confirmed by amplifying the 16S rDNA gene of the genus *Staphylococcus* and *sau* gene specific for *S. aureus*.<sup>[3]</sup> A multiplex polymerase chain reaction (PCR) was done to simultaneously detect genes responsible for resistance to four classes of antibiotics and the isolate was positive for *aac A-aph D*, *erm (C)* and *mecA* encoding for resistance to aminoglycoside, erythromycin and oxacillin respectively.<sup>[3]</sup> The organism was susceptible to tetracycline and, therefore, *tetK* and *tetM* genes were not amplified.<sup>[3]</sup> All the primers were synthesized at Sigma Genosys, India.

The patient who was empirically put on piperacillin/tazobactam was shifted to vancomycin when cultures identified the isolate as MRSA on the third day. His renal function worsened and he was put on hemodialysis and mechanical ventilatory support. Subsequently he developed septic shock and metabolic acidosis and expired on the fourth day of admission due to heart failure.

## DISCUSSION

Purulent pericarditis historically a disease of children and young adults has been a rare entity in the modern antibiotic era. Since 1945, the median age at the time of diagnosis has increased from 21 to 49 years.<sup>[4]</sup> The predisposing factors in the post antibiotic era were found to be an underlying non-infectious condition like thoracic surgery or chronic renal disease. Other predisposing factors are rheumatoid arthritis, malignancy, immunosuppression, and alcohol abuse.<sup>[5]</sup> Pericardial diseases are more common in patients with renal disease and frequency has declined from 20%, which was 35 years ago, to 5% presently.<sup>[6]</sup> In most of these cases pericardial fluid did not show any evidence of infection, making purulent pericarditis a rare entity. Due to the absence of typical pericarditis features diagnosis of purulent pericarditis is often delayed. These patients typically present with an acute illness characterized by fever, chills, and tachycardia. Pericardial rub and chest pain are frequently not present and ECG may be normal in 35% of cases.<sup>[4,7]</sup> Primary site of infection is rarely pericardium and four pathways have been described for its spread to the pericardium namely direct extension of

an intrathoracic process, penetrating injury to the chest wall, local extension and hematogenous spread.<sup>[1]</sup> Purulent pericarditis following percutaneous procedures is being increasingly reported and therefore these nosocomial infections are more likely to be caused by multi-drug resistant (MDR) pathogens.

Though the introduction of antibiotics has drastically reduced the incidence of purulent pericarditis in the last few decades, it is slowly reemerging due to the increased prevalence of MDR pathogens. *S. aureus* is the most common cause of purulent pericarditis,<sup>[2]</sup> and therefore reports of MRSA purulent pericarditis are on the rise.<sup>[8,9]</sup> Even though there are potent antibiotics to treat MRSA a delay in diagnosis often leads to high mortality. Our case highlights one such case of fatal purulent pericarditis caused by and MDR MRSA where early diagnosis and appropriate empirical antibiotic therapy could have resulted in a favorable outcome.

### CONCLUSION

We suggest that acute purulent pericarditis with MDR MRSA should be considered in patients with renal disease.

### REFERENCES

1. Klacsmann PG, Bulkley BH, Hutchins GM. The changed spectrum of purulent pericarditis: An 86 year autopsy experience in 200 patients. *Am J Med* 1977;63:666-73.
2. Parikh SV, Memon N, Echols M, Shah J, McGuire DK, Keeley EC. Purulent pericarditis: Report of 2 cases and review of the literature. *Medicine (Baltimore)* 2009;88:52-65.
3. Strommenger B, Kettlitz C, Werner G, Witte W. Multiplex PCR assay for simultaneous detection of nine clinically relevant antibiotic resistance genes in *Staphylococcus aureus*. *J Clin Microbiol* 2003;41:4089-94.
4. Sagrista-Sauleda J, Barrabes JA, Permanyer-Miralda G, Soler-Soler J. Purulent pericarditis: Review of a 20-year experience in a general hospital. *J Am Coll Cardiol* 1993;22:1661-5.
5. Skiest DJ, Steiner D, Werner M, Garner JG. Anaerobic pericarditis: Case report and review. *Clin Infect Dis* 1994;19:435-40.
6. Lange RA, Hillis LD. Clinical practice. Acute pericarditis. *N Engl J Med* 2004;351:2195-02.
7. Morgan RJ, Stephenson LW, Woolf PK, Edie RN, Edmunds H. Surgical treatment of purulent pericarditis in children. *J Thorac Cardiovasc Surg* 1983;85:527-31.
8. Lee YP, Hoi WH, Wong RC. A case of myopericarditis in a patient with methicillin-resistant *Staphylococcus aureus* community-acquired pneumonia. *Ann Acad Med Singapore* 2008;37:243-5.
9. Marcia R, Robert M. Four cases of community-associated methicillin-resistant *Staphylococcus aureus* pericarditis. *Infect Dis Clin Pract (Baltim Md)* 2010;18:251-2.

**How to cite this article:** Kumar VA, Nisha N, Thachathodiyl R, Nandakumar A, Dinesh KR, Thatcher E, Karim S, Biswas R. Molecular characterization of methicillin-resistant *staphylococcus aureus* causing fatal purulent pericarditis. *J Lab Physicians* 2013;5:136-8.

**Source of Support:** Nil. **Conflict of Interest:** None declared.

#### Announcement

#### Android App



Download  
**Android  
application**

FREE

A free application to browse and search the journal's content is now available for Android based mobiles and devices. The application provides "Table of Contents" of the latest issues, which are stored on the device for future offline browsing. Internet connection is required to access the back issues and search facility. The application is compatible with all the versions of Android. The application can be downloaded from <https://market.android.com/details?id=com.app.medknow>. For suggestions and comments do write back to us.