

Schistosomiasis of the Appendix in a Tertiary Hospital in Northern Nigeria: A 22-Year Review

Saad A Ahmed, Umar Mohammed, Robert B Sanda¹, Jerry Makama², Mohammed S Shehu, Emmanuel A Ameh², Ahmed A Mayun

Departments of Pathology, and ²Surgery, Ahmadu Bello University Teaching Hospital, Zaria, Kaduna, Nigeria, ¹Department of Surgery, Acute Care and Emergency Surgical Service, Peter Lougheed Center, Calgary General Hospital, Calgary, AB, Canada

Address for correspondence: Dr. Saad A Ahmed, E-mail: saahmednl@yahoo.com

ABSTRACT

Background: Schistosomiasis is one of the neglected tropical diseases caused by a trematode, *Schistosoma* spp, and affects many systems in the body including the gastrointestinal tract. Schistosomiasis of the appendix is a well-recognized disease and presents as a chronic granulomatous inflammation. This study aims to document the frequency and pattern of distribution of schistosomal appendicitis in our environment.

Materials and Methods: This is a retrospective histopathological review of schistosomiasis of the appendix in the Department of Pathology, Ahmadu Bello University Teaching Hospital, Zaria - Nigeria, between January 1, 1991 to December 31, 2012.

Results: Within the study period, there were 1,464 appendectomy specimens histologically examined in the Pathology Laboratory. Thirty of these, representing 2.1%, were diagnosed as schistosomiasis of the appendix. The male:female ratio was 6.5:1 and peak age incidence was in the 20-29 years age group. Abdominal pains, vomiting and fever were seen in 23 (76.7%) and altered bowel motion in seven (23.3%) patients.

Conclusion: This study showed that schistosomiasis of the appendix is not rare and that its presentation is similar to other forms of appendicitis. There is a need to focus on the prevention of schistosomiasis in order to reduce morbidity among these economically viable age groups.

Key words: Appendicitis, Nigeria, schistosomiasis

INTRODUCTION

Schistosomiasis is one of the neglected tropical diseases and the World Health Organization (WHO) estimates that 500-600 million people in tropical and subtropical countries are at risk for schistosomiasis and that over 200 million people are infected.^[1,2] The species of major global importance are *Schistosoma haematobium*, *S. mansoni* and *S. japonicum*.^[3] All the three species deposit eggs in the appendix, but schistosomiasis seldom cause

appendicitis.^[4,5] Schistosomiasis of the appendix is a well-recognized disease. Some reports have implicated *S. haematobium*, *S. mansoni* and *S. japonicum* species in having a preference for the appendix.^[6-9]

This study reports the frequency distribution and clinico-pathological findings of 30 cases of schistosomal appendicitis seen in a tertiary hospital in Northern Nigeria.

MATERIALS AND METHODS

The study was a retrospective histopathological study of appendectomy specimens in the Pathology Laboratory of the Ahmadu Bello University Teaching Hospital Zaria - Nigeria over a 22- year period between January 1, 1991 and December 31, 2012. Clinical data on each case were extracted from the

Access this article online	
Quick Response Code: 	Website: www.jlponline.org
	DOI: 10.4103/0974-2727.129085

respective copies of the request cards. All tissues had been previously fixed in formalin. The hematoxylin and eosin (H and E)-stained slides were retrieved in each case and reviewed microscopically by the authors. Where slides were missing or broken, fresh sections were taken from the paraffin-embedded tissue blocks of the specimens and stained.

Cases in whom the bio-data, clinical details, slides and/or tissue blocks were missing were excluded from the study. The results are presented in a tabular form and analyzed using simple frequency distribution.

RESULTS

Over the 22-year period, 1464 appendectomy specimens were received and 30 of these were diagnosed as schistosomal appendicitis representing 2.1% of all cases [Figure 1]. There were 26 males and four females, with male: female ratio of 6.5:1 [Table 1], with an age range of 13-55 years and a peak age incidence in the third decade. The presenting complaints were abdominal pains, vomiting and fever, seen in 23 (76.7%) and altered bowel motion in seven (23.3%) patients [Table 2].

Gross examinations of the specimen showed features of acute appendicitis with fibrinopurulent exudates in five cases, serosa congestion and thickened wall in 10 case, and 15 cases were grossly unremarkable; however fecaliths were identified in 24 cases. Microscopic examinations showed that all the appendices had Schistosoma ova in the mucosa and/or different parts of the wall [Figure 2]. The ova were morphologically consistent with *S. haematobium* in 29 cases, while one case was consistent with *S. mansoni*. Morphologically, *S. haematobium* ova have a terminal spine while *S. mansoni* have lateral spine. The other tissue reactions include submucosal fibrosis, active granuloma formation with tissue eosinophilia and infiltrates of acute and chronic inflammatory cells.

DISCUSSION

Schistosomiasis is an important and highly prevalent trematode infection affecting approximately 200 million people in tropical and sub-tropical countries.^[1] Schistosomiasis is endemic in many parts of Nigeria. The incidence of schistosomal appendicitis from this study is 2.1% [Figure 1], which is similar to 2.3% reported by Gali *et al.*^[10] in Maiduguri and 2.4% observed by Adebamowo

et al.^[7] in Ibadan. However, our report is higher than the report by Ojo *et al.*,^[8] with values of 0.9%, but lower than the 4.15% value observed by Badmos *et al.*^[9] and 9% value observed by Attah *et al.*^[11] in Ibadan. The reason for the fall in the incidence is probably due to the improvement of provision of social and medical amenities, and treatment with effective drugs in Nigeria. In developed countries like the USA, Japan and Ankara, schistosomal appendicitis is very rare, with an incidence of 0.2%, 0.34% and 0.05%, respectively.^[12-14] These are reports from nonendemic areas and higher socioeconomic indices as well.

Most cases were seen in the second and third decades of life, with a peak incidence in the third decade [Table 1], and this is similar to that reported by Adekunle *et al.*^[15] and Adisa *et al.*^[16]. However, this is higher compared with the peak age incidence of acute appendicitis observed in the second decade by Badmos *et al.*^[9]

Table 1: Age groups and gender distribution of schistosomal appendicitis

Age (years)	Male	Female
10-19	6	1
20-29	8	1
30-39	2	1
40-49	2	0
50-59	2	0
Unspecified	6	1
Total	26	4 (M:F, 6.5:1)

Table 2: Clinical presentation of 30 cases

Clinical presentation	Frequency (%)
Abdominal pain	23 (76.7)
Vomiting	23 (76.7)
Fever	23 (76.7)
Altered bowel motion	7 (23.3)

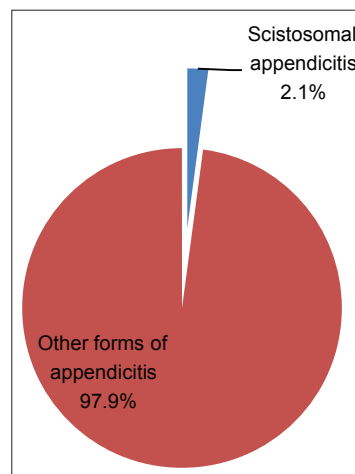


Figure 1: Frequency of Schistosomal appendicitis among appendectomy specimens

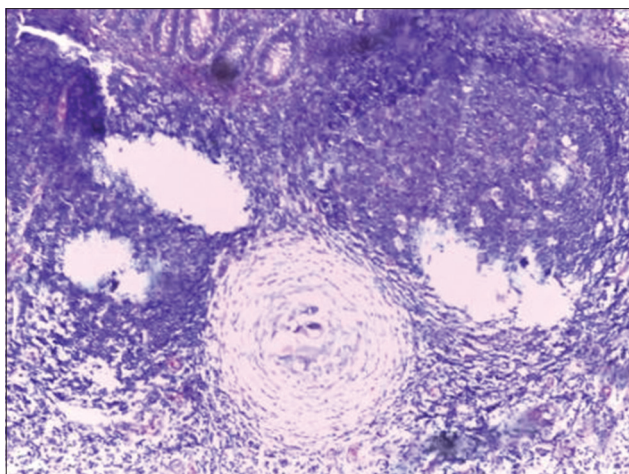


Figure 2: Section showing schistosoma ova within a granuloma and surrounded by chronic inflammatory cells' infiltrate (H and E, $\times 200$)

The clinical features are not different from other reports. Abdominal pains, vomiting and fever remain the most common initial symptoms, and were present in 23 (76.7%) of the patients, and altered bowel motion in seven (23.3%) patients was the second most common symptom [Table 2]; this is similar to other reported series.^[9-12,15]

The histopathological findings are not quite different from reports in the subregion, except that *S. haematobium* was the sole agent in appendiceal schistosomiasis from this report in 29 (96.7%) cases, which is in contrast to *S. mansoni* as reported in some series in Nigeria.^[8,17] This could be due to the fact that *S. haematobium* is endemic in this environment and it has been established that in an endemic area, it is not uncommon to be found in the appendix.^[4,5,9,10,18] The gold standard of diagnosis is identification of the ova by either histology in a tissue or microscopy of the urine or feces; in the tissue, the basic lesions of schistosomiasis are circumscribed granuloma around eggs or a diffuse cellular infiltrate around eggs by eosinophils and neutrophils [Figure 2]. Plasma cells, lymphocytes, macrophages and giant cells are also usually present.^[4] The granulomata vary in structure and the only pathognomonic feature is the contained eggs. Some eggs are surrounded by a layer of eosinophilic material, the Splendore-Hoeppli phenomenon.^[4,5] Schistosoma egg are readily demonstrable under H and E stain.^[4] Sometimes, special stains could be used to demonstrate schistosoma ova in the tissues. Because the ova are usually surrounded by periodic-acid Schiff (PAS)-positive diastase-resistant materials, these stains can be used.^[19] In addition, the egg shells of *S. mansoni* and *S. intercalatum* are acid fast, while those of *S. haematobium* are not.^[4] In the present report, special stains were not performed due to the fact that

schistosoma ova were easily demonstrated morphologically in the tissue sections stained with H and E.

This report has not only confirmed the impression of some earlier authors that schistosomiasis can cause appendicitis but also confirmed that it should be considered as a differential diagnosis in patients who are in their third decade of life with features of appendicitis. In all our cases, there was no prior clinical suspicion of schistosomiasis. Also, appendectomy specimens should be sent for histopathological review so that patients could benefit from full investigation and treatment.

REFERENCES

1. World Health Organization. Schistosomiasis Control. Division of Control of Tropical Diseases. Geneva: World Health Organization; 1998.
2. Arruda RM, Castro Rde A, Tamura MV, Ruano JM, Baracat EC, Girão M. Mansoni's schistosomiasis of a leiomyoma: Case report. Clinics [HYPERLINK "http://www.ncbi.nlm.nih.gov/pubmed/17823718"](http://www.ncbi.nlm.nih.gov/pubmed/17823718) \o "Clinics (São Paulo, Brazil)." (Sao Paulo) 2007;62:529-30.
3. Leutscher P, Ravaoalimalala VE, Raharisolo C, Ramarokoto CE, Rasendramino M, Raobelison A, et al. Clinical findings in female genital schistosomiasis in Madagascar. Trop Med Int Health 1998;3:327-32.
4. Robert MM, Charlie NB, Allen WC. Schistosomiasis. In: Chapman HB, Daniel HC, editors. Pathology of Tropical and Extra Ordinary Diseases. Vol 2. Washington DC: Armed Forces Institute of Pathology; 1976. p. 482-508.
5. Edington GM, Gilles HM, editors. In: Pathology in the Tropics. London: Edward Arnold Publishers Ltd.; 1976. p. 149-79.
6. Smith JH, Kamel IA, Elwi A, Von Lichtenberg F. A quantitative post mortem analysis of urinary schistosomiasis in Egypt. I. Pathology and pathogenesis. Am J Trop Med Hyg 1974;23:1054-71.
7. Adebamowo CA, Akang EE, Ladipo JK, Ajao OG. Schistosomiasis of the appendix. Br J Surg 1991;78:1219-21.
8. Ojo OS, Udeh SC, Odesanmi WO. Review of the histopathological findings in appendices removed for acute appendicitis in Nigerians. J R Coll Surg Edinb 1991;36:245-8.
9. Badmos KB, Komolafe AO, Rotimi O. Schistosomiasis presenting as acute appendicitis. East Afr Med J 2006;83:528-32.
10. Gali BM, Nggada HA, Eni EU. Schistosomiasis of the appendix in Maiduguri. Trop Doct 2006;36:162-3.
11. Attah EB, Banigo OG. Schistosomal appendicitis. Int Surg 1975;60:616-7.
12. Nandipati K, Parithivel V, Niazi M. Schistosomiasis: A rare cause of acute appendicitis in the African American population in the United States. Am Surg 2008;74:221-3.
13. Terada T. Schistosomal appendicitis: Incidence in Japan and a case report. World J Gastroenterol 2009;15:1648-9.
14. Duzgun AP, Moran M, Uzun S, Ozmen MM, Ozer VM, Seckin S, et al. Unusual findings in appendectomy specimens: Evaluation of 2458 cases and review of the literature. Indian J Surg 2004;66:221-6.
15. Adekunle OO, Funmilayo JA. Acute appendicitis in Nigeria. J R Coll Surg Edinb 1986;31:102-5.
16. Adisa AO, Omonisi AE, Osasan SA, Alatise OI. Clinicopathological review of schistosomal appendicitis in south western Nigeria. Trop Gastroenterol 2009;30:230-2.
17. Adesunkanmi AR, Agbakwura EA, Adekunle KA. Pattern and outcome of acute appendicitis in semi-urban and rural African communities: A study of 125 patients. Niger Med Pract 1998;36:8-11.
18. Edino ST, Mohammed AZ, Ochicha O, Anumah M. Appendicitis in Kano,

Nigeria: A 5-year review of pattern, morbidity and mortality. *Ann Afr Med* 2004;3:38-41.

19. Frank BJ. Splendore-Hoeppli phenomenon. In: Chapman HB, Daniel HC, editors. *Pathology of Tropical and Extraordinary Diseases*. Vol 2. Washington DC: Armed Forces Institute of Pathology; 1976. p. 681-3.

How to cite this article: Ahmed SA, Mohammed U, Sanda RB, Makama J, Shehu MB, Ameh EA, Mayun AA. Schistosomiasis of the appendix in a tertiary hospital in northern nigeria: A 22-year review. *J Lab Physicians* 2014;6:18-21.

Source of Support: Nil. **Conflict of Interest:** None declared.

Announcement

Android App



Download
**Android
application**

FREE

A free application to browse and search the journal's content is now available for Android based mobiles and devices. The application provides "Table of Contents" of the latest issues, which are stored on the device for future offline browsing. Internet connection is required to access the back issues and search facility. The application is compatible with all the versions of Android. The application can be downloaded from <https://market.android.com/details?id=comm.app.medknow>. For suggestions and comments do write back to us.