Article published online: 2020-02-19

Case Report

Access this article online
Quick Response Code:

Website:
www.jlponline.org

DOI:
10.4103/0974-2727.208261

Cotrimoxazole, a wonder drug in the era of multiresistance: Case report and review of literature

Priyam Batra, Vishant Deo[1], Purva Mathur, Amit Kumar Gupta[2]

Abstract:

Antimicrobial resistance is one of the greatest threats to human health worldwide. The rate of development of newer antibiotics is much slower than the rate of development of antibiotic resistance. A survey reported that it takes 15 years and US$800 million (including preclinical and clinical costs) to bring a single drug to the market, whereas the reuse of the older drugs for antimicrobial use takes $17 million, thereby circumventing 40% of the overall cost. The first case is a patient with nosocomial pyrexia of unknown origin who was given treatment with tigecycline and cefepime/tazobactam but failed to respond to the same. However, the patient responded to the treatment with cotrimoxazole. The second case is a patient with meningitis caused by an atypical zoonotic pathogen, *Staphylococcus chromogenes*. This is the first report of human infection with *S. chromogenes*, this being a common cause of bovine mastitis. The isolate was obtained from a patient of neurotrauma who developed meningitis after decompressive craniotomy. The strain was obtained from cerebrospinal fluid, blood, and shunt chamber pus. Cotrimoxazole was given for the treatment, and the patient improved after the treatment. Although the newer antibiotics have replaced sulfonamides in the treatment of many infections, they are still of great value and are the agents of choice in many infections. Sulfonamides have wide antimicrobial activity against both Gram-positive and Gram-negative bacteria, but their usefulness has diminished with the emergence of resistant strains. This paper reports cases of two different kinds of infections from a level 1 trauma center, who failed to respond to the newer antibiotics but showed a response to administration of cotrimoxazole.

Key words:

Cotrimoxazole, multidrug-resistant pathogens, nosocomial pyrexia of unknown origin, older antibiotic, *Staphylococcus chromogenes*

Introduction

Antimicrobial resistance is one of the greatest threats to human health worldwide.[1] It dramatically reduces the probability of effectively treating infections and increases the morbidity and mortality associated with common bacterial diseases.[2] The rate of development of newer antibiotics is much slower than the rate of development of antibiotic resistance. A survey reported that it takes 15 years and US$800 million (including preclinical and clinical costs) to bring a single drug to the market, whereas the reuse of the older drugs for antimicrobial use takes $17 million, thereby circumventing 40% of the overall cost.[3]

Although the newer antibiotics have replaced sulfonamides in the treatment of many infections, they are still of great value and are the agents of choice in many infections.[4,5] Sulfonamides are derivatives of para-aminobenzenesulfonamide (sulfanilamide) as shown in Figure 1. Most of the sulfonamides are relatively insoluble in water, but their sodium salts are readily soluble. The minimal structural prerequisites for antibacterial action are in the sulfanilamide itself. The sulfur must be linked directly to the benzene ring. Substitutions in the amide NH2 group (N1) have variable effects on the antibacterial activity of the molecule, but the substitution of heterocyclic aromatic nuclei at N1 yields highly potent compounds.[6] Sulfonamides competitively inhibit dihydropteroate synthase, the bacterial enzyme responsible for the incorporation of para-aminobenzoic acid into dihydropteroic acid, the immediate precursor of folic acid. Trimethoprim exerts a synergistic effect with sulfonamides by selectively inhibiting microbial dihydrofolate reductase, the enzyme that reduces dihydrofolate to tetrahydrofolate, as shown in Figure 2.[6] The most effective ratio of these two drugs for the greatest number of microorganisms

Departments of Microbiology, [1]Surgery and [2]Lab Medicine, All India Institute of Medical Sciences, New Delhi, India

Address for correspondence:
Dr. Purva Mathur, Room No 211, Second Floor, Department of Laboratory Medicine, JPNA Trauma Centre, AIIMS, New Delhi, India.
E-mail: purvamathur@yahoo.co.in

Submission: 29-06-2016
Accepted: 07-08-2016

This is an open access article distributed under the terms of the Creative Commons Attribution-NonCommercial-ShareAlike 3.0 License, which allows others to remix, tweak, and build upon the work non-commercially, as long as the author is credited and the new creations are licensed under the identical terms.

For reprints contact: reprints@medknow.com

How to cite this article: Batra P, Deo V, Mathur P, Gupta AK. Cotrimoxazole, a wonder drug in the era of multiresistance: Case report and review of literature. J Lab Physicians 2017;9:210-3.

© 2017 Journal of Laboratory Physicians | Published by Wolters Kluwer - Medknow

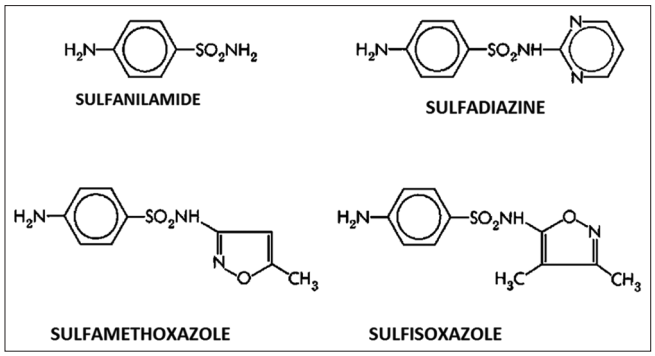

Figure 1: Structural formula of selected sulfonamides

is 20 parts sulfamethoxazole to 1 part trimethoprim. Sulfonamides have a good oral absorption with peak plasma levels reaching in 2–6 h. They enter the body fluids readily and may reach concentrations therein that are 50–80% of the serum concentration. The drug readily enters cerebrospinal fluid (CSF).[6]

Sulfonamides have a wide antimicrobial activity against both Gram-positive and Gram-negative bacteria, but their usefulness has diminished with the emergence of resistant strains. The combination of sulfonamides and trimethoprim has been used successfully in the treatment of uncomplicated lower urinary tract infections, acute exacerbations of chronic bronchitis, and shigellosis.[6] It is also used in HIV-infected patients as prophylaxis against opportunistic pathogens *Pneumocystis jirovecii* and *Toxoplasma gondii.* The WHO recommends cotrimoxazole prophylaxis to be provided to all HIV-infected individuals with CD4 count <350/mm^3, especially in resource-limited settings with high prevalence of bacterial infections and malaria.[7]

This paper reports cases of two different kinds of infections from a level 1 trauma center, who failed to respond to the newer antibiotics but showed a response to the administration of cotrimoxazole (sulfonamide/trimethoprim combination).

Case Reports

Case 1

A 21-year-old boy presented to a trauma center with polytrauma involving head, chest, spine, abdomen, and perineum following road traffic injury. The patient had a degloving injury of the perineum. The patient also had pelvic and long bone fractures along with musculoskeletal injury. The patient was started with amoxicillin/clavulanate, metronidazole, and amikacin empirically as per the hospital's antibiotic policy. Diversion end colostomy was done to prevent soiling of the perineal wound. Multiple debridements followed by negative pressure wound therapy application were done. Later, the wound was closed and the pelvic fracture was managed with traction followed by surgical treatment.

The patient was afebrile for 5 days postoperatively but developed a high-grade fever (>102°F) with high leukocyte count on postoperation day 5. Blood, drain, and urine cultures were done which were found to be sterile. Perineal wound site was inspected and was found to have no discharge. Wound swab from the site was sent for culture, but no pathogen grew from the wound. The whole body computed tomography scan was performed in which no focus of infection could be localized. The source of fever could not be identified but the patient's condition continued to deteriorate with continuous high-grade fever. The patient was diagnosed to have nosocomial pyrexia of unknown origin (PUO).

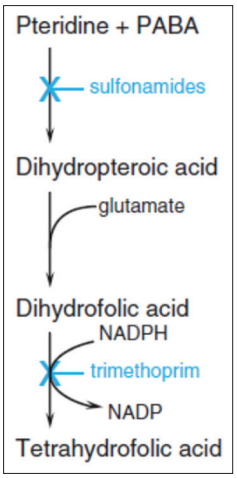

Figure 2: Steps in folate metabolism blocked sequentially by sulfonamides and trimethoprim

The patient was then started on tigecycline and cefepime/tazobactam antibiotics as both antimicrobials have good activity against Gram-positive and Gram-negative organisms and also have good soft tissue penetration. After 5 days of no response to the antibiotic combination used, the patient was started on cotrimoxazole since it is a broad spectrum antibiotic. After 3 days of cotrimoxazole treatment, the patient's fever and leukocyte count began to decrease. The patient became afebrile with normal leukocyte count after 7 days of treatment.

Case 2

A 45-year-old male presented to the emergency department following fall from height with nonpenetrating head injury leading to raised intracranial pressure (ICP). At the time of presentation, the patient had Glasgow Coma Scale (GCS) of 9, i.e. E3V3M3. Decompressive craniotomy was done along with the placement of ventriculoperitoneal shunt, and the patient was started with netilmicin and cefoperazone-sulbactam as per the hospital's antibiotic policy. Following the operation, the patient improved and the GCS became 13, E4V4M5. The patient was stable for nearly 5 days when he again started to have raised ICP with the signs of meningitis with GCS of 8, E2V2M4.

Blood and CSF culture was done; the blood culture was sterile and CSF sample grew *Staphylococcus chromogenes*. This was disregarded as a probable contaminant since it was isolated on the first occasion. The patient's condition deteriorated further due to the continuously rising ICP and his shunt removal, and the replacement was planned. On the operation table, the shunt chamber also showed visible purulent secretions which were collected and sent for culture. Shunt chamber and the repeat CSF samples were also sent for culture. *S.*

chromogenes was isolated from all the three samples, i.e. CSF, shunt chamber, and pus discharge from the shunt site. Cotrimoxazole was started based on the antibiotic sensitivity profile of *S. chromogenes* isolated and as a broad spectrum antibiotic. Blood sample was also simultaneously sent which also grew *S. chromogenes.*

After 2 days of starting cotrimoxazole, the patient started to respond, and the fever and leukocyte count started to fall. The GCS score of the patient also improved to 10, E3V3M4. Gradually, the patient's signs of meningitis also improved, and repeated CSF and blood cultures after 7 days of starting cotrimoxazole were sterile.

Case 3

Cotrimoxazole is used as the drug of choice in patients with *Stenotrophomonas maltophilia* infections. This is because of the intrinsic resistance of *Stenotrophomonas* spp. to a variety of antibiotics, ability of biofilm formation, and production of various extracellular enzymes. In our hospital, retrospective analysis of the 7 year hospital laboratory data showed that a total of 123 samples obtained from 88 patients were culture positive for *Stenotrophomonas* infection. Most patients presented with bacteremia (45, 51%), followed by pneumonia (37, 42%), and skin and soft tissue infections (6, 7%). The demographic characteristics of the patients with *Stenotrophomonas* infection are presented in Table 1.

Of the 88 patients, 54 (61%) patients not admitted to the Intensive Care Unit (ICU) had cotrimoxazole as the drug of choice for treatment. These patients responded well to the treatment. Only 7 of the 34 patients admitted to ICU and received cotrimoxazole. However, the drug had to be discontinued after few days of treatment due to the bone marrow suppression caused by the drug.

Table 1: Demographic and basic characteristics of 88 patients infected with *Stenotrophomonas maltophilia*

Characteristics	Cases
Age (median, range (years))	30 (1-77)
Sex, *n* (%)	
Female	26 (30)
Male	62 (70)
Days of hospitalization (mean±SD)	4215
Number of patients with ICU stay	34
Duration of ICU stay (mean±SD)	43±17
Mortality (%)	28 (32)

ICU: Intensive Care Unit, SD: Standard deviation

Discussion

The patient in the first case was hospitalized for more than 5 days when he developed temperature >101°F on several occasions with no infection incubating at the time of admission. The patient was intensively investigated but the source of infection could not be localized, thus was diagnosed as a case of nosocomial PUO.[8] The most probable locus of infection was abdominal cavity as per the clinician's judgment. Thus, cotrimoxazole was started as it is a broad spectrum antibiotic with good soft tissue penetration.

S. chromogenes isolated from the second patient is a Gram-positive coagulase negative *Staphylococcus* associated with bovine mastitis.[9] This is a common zoonotic pathogen which is generally not associated with human infections. Other coagulase negative *Staphylococci* which have been identified as the causes of bovine mastitis include *Staphylococcus simulans*, *Staphylococcus epidermidis*, and *Staphylococcus haemolyticus*.[10] Bovine mastitis can be caused by trauma or infection. Mastitis can cause heavy economic loss to milk producers with the average production loss per lactation for one infected quarter is about 1.600 pounds. Economic loss can also be due to discarded abnormal milk, cost of replacement of the infected cow, and cost of drugs and veterinary services.[11]

To the best of our knowledge, this is the first report of meningitis in humans caused by *S. chromogenes*. The source of the pathogen could not be identified. However, based on the sensitivity report, cotrimoxazole was started for treatment as it has a broad spectrum of action and also has good central nervous system penetration and the patient also responded well to the drug. Patients' response to the treatment was assessed by the decreasing ICP and improvement of GCS score.

S. maltophilia (earlier classified as *Pseudomonas* or *Xanthomonas maltophilia*) is an aerobic, nonglucose fermenting, Gram-negative rod-shaped, nonspore forming, nonacid-fast facultative aerobes which is widely distributed in the natural and hospital environment. This pathogen was earlier considered to have limited pathogenic potential but now with the growing degree of immunosuppression in the general population;[12] it is being recognized as an important nosocomial pathogen. Cotrimoxazole remains the most effective treatment modality for *Stenotrophomonas* infections. However, drug resistance has been increasingly noted against this drug also.[13]

With the increasing prevalence of hospital- and community-acquired infections caused by multidrug-resistant (MDR) bacterial pathogens, development of newer antibacterial agents is necessary. However, as the rate of development of newer antimicrobial agents is slow, re-introduction of previously used antibiotics active against the MDR pathogens is a good alternative for the control of antibiotic-resistant bacteria. Cotrimoxazole is one much miracle drug having broad antibacterial spectrum making it suitable for use in a wide variety of infections and the good tissue penetration makes it useful for the treatment of infections involving multiple systems of the body. For instance, the rate of resistance to cotrimoxazole in the year 2012 in our hospital was 79.8% in Gram-negative bacteria. The level of resistance decreased to 65.6% in the year 2014. The most commonly isolated notorious pathogen in our ICU is *Acinetobacter baumannii*. Nearly 90% of these are resistant to most of the commonly used antibiotics except colistin and tigecycline. The level of resistance in *A. baumannii* in the year 2012 was 87.5% and was found to decrease to 72.4%. However, despite the increasing sensitivity to the drug, cotrimoxazole is not largely used in the ICUs because of the serious bone marrow suppression caused by the drug.[6,14,15]

Financial support and sponsorship
Nil.

Conflicts of interest
There are no conflicts of interest.

References

1. Walker B, Barrett S, Polasky S, Galaz V, Folke C, Engström G, *et al*. Environment. Looming global-scale failures and missing institutions. Science 2009;325:1345-6.
2. Chong CR, Sullivan DJ Jr. New uses for old drugs. Nature 2007;448:645-6.
3. Klevens RM, Morrison MA, Nadle J, Petit S, Gershman K, Ray S, *et al*. Invasive methicillin-resistant *Staphylococcus aureus* infections in the United States. JAMA 2007;298:1763-71.
4. Geresu B, Misganaw D, Beyene Y. Retrospective evaluation of cotrimoxazole use as preventive therapy in people living with HIV/AIDS in Boru Meda Hospital. BMC Pharmacol Toxicol 2014;15:4.
5. Patil HV, Patil VC, Rajmane V, Raje V. Successful treatment of cerebral toxoplasmosis with cotrimoxazole. Indian J Sex Transm Dis 2011;32:44-6.
6. Petri WA Jr. Goodman and Gilmans the Pharmacological Basis of Therapeutics. 12th ed. San Diego, California: McGraw Hill; 2011. p. 1625-46.
7. Guidelines on co-trimoxazole prophylaxis for HIV-related infections among children, adolescents and adults: Recommendations for a public health approach. Geneva: World Health Organization; 2006. Available from: http://www.who.int/hiv/pub/plhiv/ctx/en. [Last accessed on 2016 Aug 22].
8. Fauci AS, Braunwald E, Kasper DL, Hauser SL, Longo DL, Jameson JL, *et al*. Harrison's Manual of Medicine. 17th ed. San Diego, California: McGraw Hill; 2012. p. 199-201.
9. Souza FN, Piepers S, Della Libera AM, Heinemann MB, Cerqueira MM, De Vliegher S. Interaction between bovine-associated coagulase-negative *Staphylococci* species and strains and bovine mammary epithelial cells reflects differences in ecology and epidemiological behavior. J Dairy Sci 2016;99:2867-74.
10. Taponen S, Nykäsenoja S, Pohjanvirta T, Pitkälä A, Pyörälä S. Species distribution and *in vitro* antimicrobial susceptibility of coagulase-negative *Staphylococci isolated* from bovine mastitic milk. Acta Vet Scand 2016;58:12.
11. Schroeder JW. Mastitis Control Programs: Bovine Mastitis and Milking Management. NDSU Extension Service. North Dakota State University; 1997. p. 1-16. Available from: https://www.ag.ndsu.edu/pubs/ansci/dairy/as1129.pdf. [Last accessed on 2016 Jul 13].
12. Low CY, Rotstein C. Emerging fungal infections in immunocompromised patients. F1000 Med Rep 2011;3:14.
13. Wu H, Wang JT, Shiau YR, Wang HY, Lauderdale TL, Chang SC; TSAR Hospitals. A multicenter surveillance of antimicrobial resistance on *Stenotrophomonas maltophilia* in Taiwan. J Microbiol Immunol Infect 2012;45:120-6.
14. Sharif A, Sharif MR, Alizargar J. Susceptibility of Gra negative bacteria to cotrimoxazole in specimens sent to the laboratory of Shahid Beheshti Hospital. Middle East J Sci Res 2014;21:440-4.
15. Jain DK, Arya RK, Ranjan KP, Ranjan N. Emergence of sensitivity of cotrimoxazole in urinary tract infections. World J Pharm Res 2014;3:2172-5.