

Submucous Lipoma of Sigmoid Colon: A Rare Entity

Sir,

Lipoma of colon is a rare entity. So far to best of our knowledge, only 254 cases have been reported in the literature.^[1] It may be asymptomatic to mildly symptomatic depending upon the size of the lesion (larger than 20 mm).^[2] Though the diagnosis can be made easily at surgery or autopsy, but before that it may lead to many differential diagnostic problems, such as polypoidal carcinoma. We report a case of submucous lipoma sigmoid colon in a woman who underwent left hemicolectomy with clinical suspicion of malignancy.

A 45-year-old female presented with abdominal pain and constipation since 20 days. Abdominal examination has not revealed any organomegaly. As anorectal digital examination and proctoscopy have not revealed any significant findings, colonoscopy was then performed to find out a large polypoidal growth proximal to the sigmoid flexure nearly obstructing the lumen [Figure1]. There is ulceration of the overlying mucosa, which has raised the clinical suspicion of polypoidal Adenocarcinoma of sigmoid colon. The patient subsequently underwent left hemicolectomy.

The resected segment of sigmoid colon (30 cm in length) has revealed the presence of a smooth, ovoid, slightly firm, polypoidal, submucous tumor of 45 × 35 × 30 mm³ in size with mucosal surface ulceration; the cut surface of which is lobular, yellowish, and greasy [Figure 2].

Microscopy revealed lobules of adipocytes with little intervening fibro collagen, beneath the ulcerated mucosa and florid fibroblastic and vascular proliferation in the stalk of lesion. The smooth muscle fibres were pushed to the periphery forming a capsule along with fibrous tissue [Figure 3]. The diagnosis of submucous lipoma of colon was made.

Submucous lipomas of colon are extremely rare, with a reported incidence of approximately 0.26%,^[3] described initially by Bauer in 1757. They are more frequently seen in the large than in the

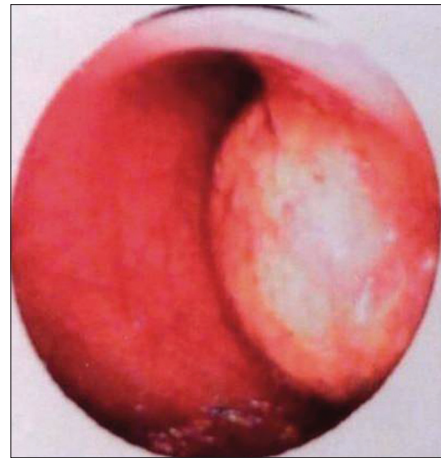

Figure 1: Colonoscopic photograph showing polypoidal growth obstructing the lumen just proximal to the sigmoid flexure

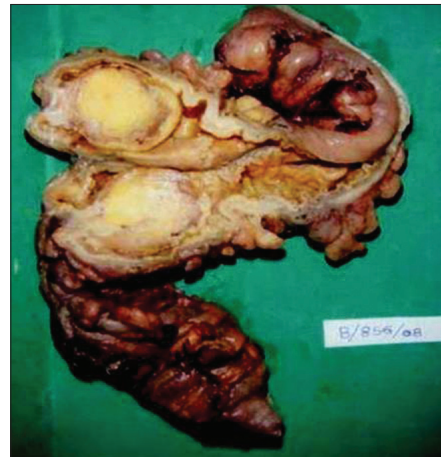


Figure 2: Gross photograph showing an ovoid, yellowish, greasy, polypoidal growth nearly obstructing the lumen

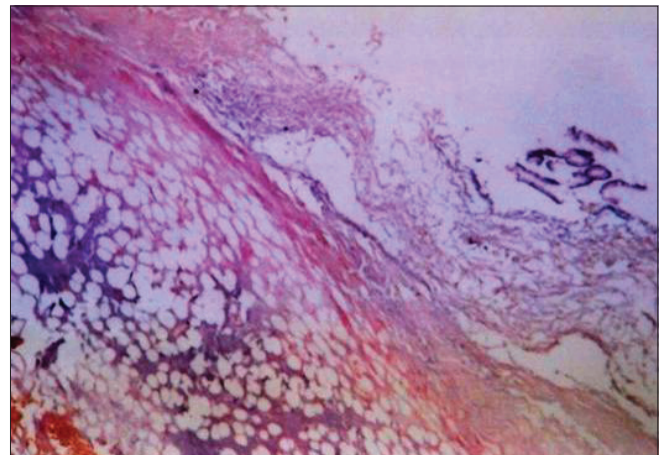


Figure 3: Microphotograph is showing mucosal ulceration and submucosal lobules of adipocytes with encapsulation (H and E, ×100)

small intestine and are common in the right accounting for nearly 90% of the cases than in the left colon. The present case is a lipoma of the left colon which is a rare entity. The histogenesis of colonic lipoma is unclear. Majority of

the patients are asymptomatic but some may experience abdominal pain, constipation, and malena. The episode of intussusception or intestinal obstruction can also be seen in the patients with a larger lipoma.^[4] Sometimes they can also be the source of massive lower gastrointestinal bleeding. Most of the cases are diagnosed only after resection; however, occasionally the diagnosis can be made from a deeper biopsy, with the development of colonoscopy, barium enema, and computed tomography (CT) scan. Some characteristic findings of colon lipomas are useful in making diagnosis, even there is a case report that colon lipoma was correctly diagnosed by sonography.^[5] If the preoperative diagnosis of colonic lipoma can be made with precision, extent of surgery may be appropriately limited and unnecessary hemicolectomies can be avoided.

**Kinnera Vijay Sreedhar Babu,
Amit Kumar Chowhan,
Mutheeswaraiyah Yootla,
Mandyam Kumaraswamy Reddy**

Department of Pathology, Sri Venkateswara Institute of
Medical Sciences, Tirupati - 517 507, India

Address for correspondence: Dr. Kinnera Vijay
Sreedhar Babu, E-mail: kinneravsb@rediffmail.com

DOI: 10.4103/0974-2727.59706

REFERENCES

1. Hayes HT, Burr HB, Melton WT. Submucous lipoma of the colon. Review of the literature and report of four cases. *Dis Colon Rectum* 1960;3:145-8.
2. Rogy MA, Mirza D, Berlakovich G, Winkelbauer F, Rauhs R. Submucous large bowel lipomas – presentation and management. An 18 year study. *Eur J surg* 1991;157:51-5.
3. Notaro JR, Masser PA. Annular colon lipoma; a case report and review of the literature. *Surgery* 1991;110:570-2.
4. Kabaalioglu A, Gelen T, Aktan S, Kesici A, Bircan O, Lüleci E. Acute colonic obstruction caused by intussusception and extrusion of a sigmoid lipoma through the anus after barium enema. *Abdom Imaging* 1997;22:389-91.
5. Alkim C, Sasmaz N, Alkim H, Caglikulekci M, Turhan N. Sonographic findings in intussusception caused by a lipoma in the muscular layer of the colon. *J Clin Ultrasound* 2001;29:298-301.