

Fusarium solani: An Emerging Fungus in Chronic Diabetic Ulcer

Ramakrishna Pai, Rekha Bloor, Shreevidya K, Divakar Shenoy*

Department of Microbiology and Surgery*, Father Muller Medical College, Kankanady, Mangalore - 575 002, India

Address for correspondence: Dr. Rekha Bloor, E-mail: rekhabloor@gmail.com

ABSTRACT

Fusarium species, a mold which causes disease mainly in plants has emerged as pathogen in immunocompromised patients. *Fusarium* is known to cause keratitis, onychomycosis, and endophthalmitis. *Fusarium solani*, is the most common isolate from clinical specimen. Here is a case, a 65-year-old male with type II diabetes mellitus since 10 years presented with a large ulcer on the left leg since 8 months following trauma. The fungal culture of the eschar of the ulcer isolated a mold, *Fusarium solani*. The patient's leg was amputated and was treated with amphotericin B. The patient was discharged on healing of the stump. This case gives emphasis on fungal culture in chronic diabetic ulcer.

Keywords: Chronic diabetic ulcer, *Fusarium solani*, fungal ulcer

DOI: 10.4103/0974-2727.66710

www.jlponline.org

INTRODUCTION

Fusarium species is a well-know plant pathogen, seen in soil and water worldwide.^[1] It has been causing invasive infections in immunocompromised patients especially in bone marrow transplantation and long-term steroid therapy patients. The main route of acquisition of the pathogen is through direct inoculation or inhalation of the spores. *Fusarium* is known to cause keratitis, onychomycosis, endophthalmitis, and even skin infection.^[2,3] On microscopic examination of the clinical specimens, septate fungal hyphae with acute angle branching similar to *Aspergillus* are seen. The fungal culture on Sabourad's Dextrose Agar (SDA) grew a mold with characteristic pink pigment, which on microscopy had fusiform septate macroconidia, specific for *Fusarium* genus of mold. Here, we present a case of chronic diabetic ulcer of the left lower limb from which *Fusarium solani* was isolated.

CASE REPORT

A 62-year-old taxi driver, on regular treatment for type II diabetes mellitus since 10 years, presented with a large ulcer on the left lower limb since 8 months following minor trauma at the heel. The patient was on

antibacterial drugs for 2 months, still ulcer did not heal.

On examination, the patient was poorly built and nourished and anemic. He was afebrile; pulse was 90 beats per minute, blood pressure 140/80 mmHg. Systemic examination did not reveal any abnormality. The ulcer was extending from the ball of the toe to the posterior aspect of middle third of the left leg [Figure 1]. The left popliteal, posterior tibial, and doralis pedis pulses were not felt.

Lab investigations were as follows: hemoglobin 11.2 g%, total leucocyte count 21,000, differential count N 90 L8 E1 M1, ESR 71 mm/first hour, HIV/HB_sAg negative, fasting blood sugar 280 mg%, urea 40 mg%, creatinine 1.5 mg%, and X-ray of the left leg with foot did not reveal any periosteal thickening.

The tissue from the ulcer was sent for culture and sensitivity test. The wet mount of 10% KOH mount of tissue revealed hyaline, septate, branched, fungal hyphae. Gram stained and Ziehl Neelsen stained smears of the tissue revealed numerous polymorphonuclear cells with septate fungal hyphae with fusiform fungal spores [Figure 2] and no acid fast bacilli, respectively. The specimens were inoculated onto blood agar, MacConkey's agar, Lowenstein Jensen medium, thioglycollate broth, and Robertson's

cooked meat medium for aerobic, Mycobacteria and anaerobic culture, respectively. The specimen was also inoculated into two sets of Sabouraud dextrose agar with and without antibiotics. One set was incubated at 37°C and the other set at 25°C. After 2-5 days of incubation, a heavy growth of fungal colonies was seen at 25°C. The colonies appeared floccose, pink and reverse side of the colony was purple [Figure 3]. The lactophenol cotton blue mount of the colony had septate branched hyphae that produced microconidia and many multiseptate sickle or boat-shaped macroconidia. For identification, subcultures were made onto potato dextrose agar (PDA), incubated at 25°C and 37°C and subjected to daily examination. Better growth on PDA was observed at 25°C. The colonies appeared floccose, pink and reverse side of the colony was purple. The lactophenol cotton blue mount of the colony had septate branched hyphae that produced microconidia and many multiseptate sickle or boat-shaped macroconidia. The grams staining of the colony is shown in the Figure 4. The fungus was identified as *Fusarium solani* by slide

culture. Later, another tissue sample was sent for repeat isolation of the fungus to confirm the pathogenic role of the fungus. This time also the same fungus i.e. *Fusarium* was isolated. Meanwhile, histopathological examination of the tissue revealed the dense infiltration of the tissue with neutrophils, lymphocytes and septate fungal hyphae with fusiform fungal spores.

Three consecutive blood samples were sent for fungal culture which was inoculated into two sets of Sabouraud dextrose agar with and without antibiotics. However, all the three samples remained negative. X-ray of the chest and abdominal ultrasound showed no abnormalities.

The patient was treated with amphotericin B i.v infusion. He underwent above knee amputation and the proximal tissue from amputation site was sent for fungal culture which did not grow any fungus. Patient was discharged after 15 days of antifungal therapy. On follow up, patient had no signs of fungal infection at the amputated stump.

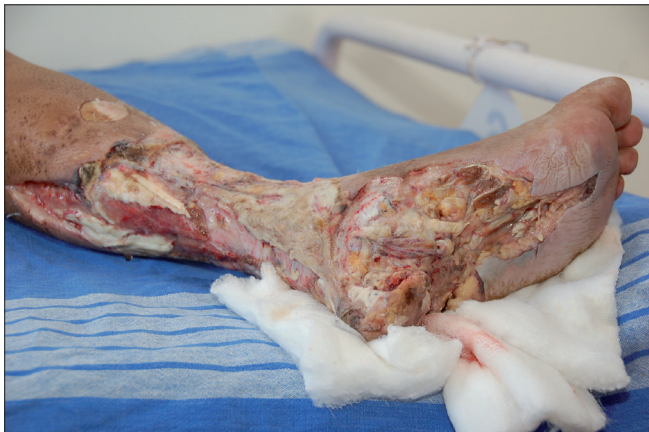

Figure 1: Extent of the ulcer on the left leg and foot

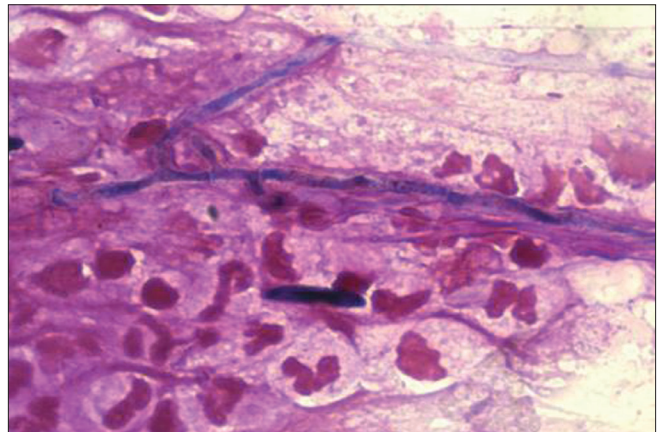


Figure 2: Grams staining of the specimen showing fungal hyphae and macroconidia in 40x

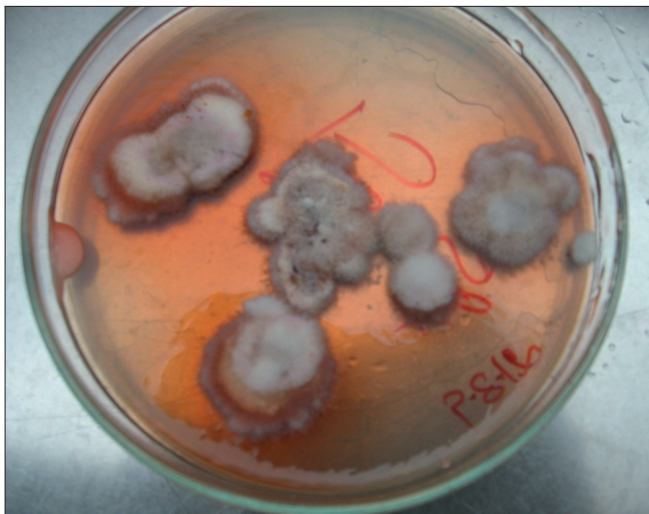


Figure 3: *Fusarium* colony on SDA after 5 days of incubation

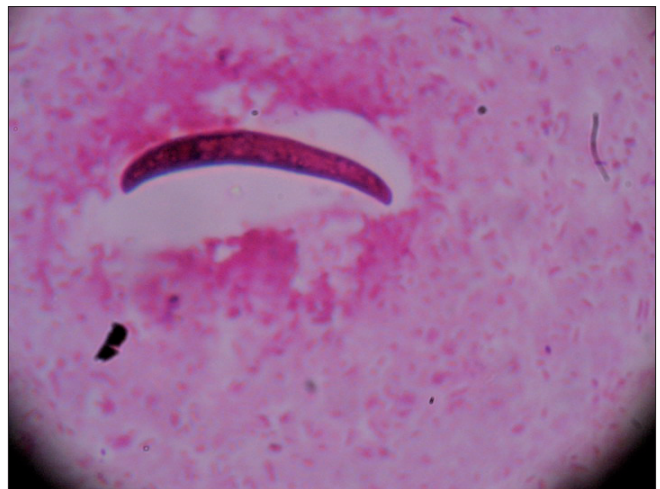


Figure 4: Microscopy of colony of *Fusarium* showing spindle-shaped macroconidia in 40x

DISCUSSION

In patients with diabetes mellitus, foot infections are common, ranging from chronic bacterial or fungal infections to serious life-threatening ones. A special consideration should be given to the environmental and opportunistic mycoses. Environmental fungi, including *Aspergillus*, *Alternaria*, and *Fusarium*, can produce infection and toxin-related diseases. *Fusarium* genus is seen commonly in soil and dead debris in environment and frequently cause disease in plants.^[1] It can cause keratitis, onychomycosis, endophthalmitis, skin, and musculoskeletal infection mainly in immunocompromised patients with bone marrow transplantation, long-term steroid therapy and AIDS. The most common isolated *Fusarium* from clinical specimens is *Fusarium solani*, followed by *Fusarium oxysporum* and *Fusarium moniliforme*.^[4] Even, osteomyelitis of the lower extremity in diabetic patients has been reported in USA.^[5] This genus of mold produces various characteristic diffusible pigments. The microscopic examination of the fungi reveals narrow septate hyphae with acute angle branching which are indistinguishable for *Aspergillus* genus. *Fusarium* produces fusiform septate macroconidia and microconidia, hence the name. The mortality rate with Fusarial infection ranges from 50 to 80%.^[2] The prognosis of the patient depends on the adequate neutrophil counts and appropriate antifungal treatment. In the immunocompromised host, disseminated disease may follow a superficial localized infection through lymphatic and/or hematological spreading because of the strong propensity of *Fusarium* for vascular invasion, thrombosis, and tissue necrosis.^[6,7] Disseminated fusariosis is defined as involvement of two noncontiguous sites in association with more than one positive hemoculture^[6,8] and can affect almost any organ. But in this case, we did not isolate *Fusarium* from blood culture. The diagnosis of *Fusarium* infection is principally based on mycology and

histopathology. Recently, a PCR technique has also been developed for specific detection of *Fusarium* species.^[9] Although the polymerase chain reaction (PCR) for detection of DNA and RNA copies is being increasingly used, the cytological/histopathological demonstration of typical septate hyphae or growth of *Fusarium* in tissue specimens remains the gold standard for a definitive diagnosis, hence PCR analysis of isolated was not done.

Hence, this case emphasizes on looking for fungal infection in long standing diabetic ulcer, who are on antibacterial agents for a long time.

REFERENCES

1. Sugar AM. Miscellaneous fungi. In: Gorbach SL, Bartlett JG, Blacklow NR, editors. Infectious diseases. Chapter 276, 3rd ed. 2004. p. 2270-5.
2. Hoshenthal DR. Uncommon fungi. In: Mandell GL, Benett JE, Dolin R editors. Principles and Practices of Infectious Disease. 6th ed, Chapter 267. Vol 2. 2005. p. 3068-79.
3. Mangini C, de Camargo B. Fungal infection due to *Fusarium* spp. in children with refractory hematologic malignancies. Med Pediatr Oncol 1999;32:149-50.
4. Campbell CK, Johnson EM, Philpot CM, Warnock DW. *Fusarium solani* in moulds with enteroblastic conidia adhering in wet masses. Identification of pathogenic fungi. Chapter 8. London: Public Health Laboratory Service; 1996. p. 160-2.
5. Bader M, Jafri AK, Krueger T, Kumar V. *Fusarium* osteomyelitis of the foot in a patient with diabetes mellitus. Scand J Infect Dis 2003;35:895-7.
6. Bushelman SJ, Callen JP, Roth DN, Cohen LM. Disseminated *Fusarium solani* infection. J Am Acad Dermatol 1995;32:346-51.
7. Freidank H. Hyalohyphomycoses due to *Fusarium* spp: Two case reports and review of the literature. Mycoses 1995;38:69-74.
8. Boutati EI, Anaissie EJ. *Fusarium*: A significant emerging pathogen in patients with hematologic malignancy: Ten years' experience at a cancer center and implications for management. Blood 1997;90:999-1008.
9. Hue FX, Huerre M, Rouffault MA, de Bievre C. Specific detection of *Fusarium* species in blood and tissues by a PCR technique. J Clin Microbiol 1999;37:2434-8.

Source of Support: Nil, **Conflict of Interest:** None declared.