

Detection of Human Papillomavirus in Cervical Gradings by Immunohistochemistry and Typing of HPV 16 and 18 in High-Grades by Polymerase Chain Reaction

Mrudula Soma, Suhasini Kamaraj

Department of Microbiology, M.G.R. College of Arts and Science, Hosur- 635 109, Tamil Nadu, India

Address for correspondence: Dr. S. Mrudula, E-mail: somamrudula@hotmail.com

ABSTRACT

Background: Cervical cancer has a major impact on developing countries, where screening programs are not well established or effective.

Aim: This study aims to investigate Human papillomavirus (HPV) 6, 11 and 18 expression in cervical biopsies by immunohistochemistry, (IHC) followed by typing of high-risk HPV 16 and 18 in high-grades by polymerase chain reaction (PCR).

Settings and Design: During the study period of six months, 30 biopsy samples were obtained from patients attending various gynecology clinics in and around Trichy District, Tamil Nadu, between January and June 2009.

Materials and Methods: The ecto- and endoscopic biopsy specimens of the cervix were fixed in 10% buffered formalin; routine paraffin sections were taken for processing and stained with hematoxylin and eosin. The samples were graded as Normal cervicitis, Cervical intraepithelial neoplasia (CIN) I, II, III, and squamous cell carcinoma (SCC), for original diagnosis by pathologists. The extra sections were studied for the expression of HPV 6, 11 and 18 by immunohistochemistry and HPV DNA 16 and 18 by PCR.

Results: Out of thirty samples, 15 expressed positive and 15 negative for HPV marker. Twenty-seven cases of cervical gradings have been categorized into high grade CIN II/III, SCC (23) and low grade CIN I (4). The high grades were subjected to PCR for high-risk typing. The results revealed that 15 cases were positive for HPV genotype 16 and eight cases for HPV genotype 18. The prevalence of HPV infection was found to be higher in women aged between 50 and 59.

Conclusion: This study reveals a significant detection of HPV in the South Indian suspected individuals, by the use of advanced techniques such as IHC and PCR.

Keywords: Cervical intraepithelial neoplasia, human papillomavirus, squamous cell carcinoma, immunohistochemistry, polymerase chain reaction

DOI: 10.4103/0974-2727.66711

www.jlponline.org

INTRODUCTION

Cervical cancer is the second-most common type of cancer among women, worldwide. In India, an estimated 1,32,082 new cases are reported annually.^[1] The disease is caused by HPV, a sexually transmitted virus,^[2] risk factors are immunosuppression,^[3] and infection with *Chlamydia trachomatis*.^[4] Out of 100 HPV genotypes, 30 were shown to infect the uterine cervical epithelium.^[5] The subsets for inducing cervical cancers^[6] are low-, intermediate-, and high-risk. The virus is asymptomatic in the benign stage^[7,8] and it clinically manifests as a neoplastic transformation.^[9]

The primary method for HPV detection is the Pap

smear test. Human error is probably the primary threat to accurate interpretation.^[10] To overcome these limitations, high sensitivity and specificity for detection of truly dysplastic cells, in the form of an objective biomarker with polymer-based methods, is adopted. However, these methods have less specificity in differentiating the types. Hence, application of molecular methods can demonstrate HPV genetic material in nearly 100% of the premalignant and malignant tissues of the uterine cervix.

MATERIALS AND METHODS

In the study, a total of 30 cervical biopsies were

included. The biopsy specimens were fixed in 10% buffered formalin and processed for routine paraffin section, using the conventional methods. These sections were strictly selected from the Pathology Department (from January to June 2009), Doctors Diagnostic Center, Trichy, Tamil Nadu, India. The original histological diagnoses were obtained on the hematoxylin and eosin slides by an experienced pathologist. Thin (4µm) sections were cut, placed on slides, and submitted for immunohistochemical techniques. An additional 20µm section was used for DNA extraction and HPV typing by polymerase chain reaction (PCR). The section blade was replaced after each specimen block to avoid contamination between the samples.

Immunohistochemistry

Immunohistochemistry was performed on 30 samples. For conducting immunohistochemical experiments, the kits were bought from Novocastra, UK, Biogenex, USA, and other chemicals from Merck, Mumbai. Four micrometer sections of formalin-fixed, paraffin-embedded tissues were cut and placed on clean microscopic slides. The sections were dewaxed in xylene, rehydrated in graded alcohol, and rinsed in water. For antigen retrieval, the sections were immersed in 0.01M of citrate buffer, pH 6.0, in a high pressure cooker for 20 minutes, the tissue sections were cooled under tap water for 10 minutes. A peroxidase block reagent was applied on the specimen according to the tissue size and it was incubated for 5–10 minutes at room temperature. Next, a power block reagent was added, after draining out the slides, and incubated for 15 minutes at room temperature. An appropriate volume of mouse monoclonal antibody (HPV 6, 11, and 18) was added for one hour on the specimen and then with an appropriate volume of a secondary antibody (super enhancer reagent), it was incubated for 30 minutes, followed by rinsing with Tris buffer saline, pH 7.4 to 7.6 for 10 minutes. Poly horse radish peroxidase was added to it and it was incubated at room temperature for 30 minutes followed by rinsing with Tris buffer saline for 10 minutes. The slides were drained and blotted around the sections, to which an appropriate volume of substrate (3, 3'-diaminobenzidine) solution was added, and they were incubated for 40–50 minutes at room temperature followed by rinsing thrice in Tris-buffer saline. Finally, the sections were counterstained in a Mayer's hematoxylin bath for 1–10 minutes and then rinsed with tap water. The negative control consisted of the same section where the diluents without primary antibody were applied. The slides were tilted fully to cover the tissue by placing it in the horizontal position and allowed the coat to burden it, and then the cover slips were placed. It was then viewed under the light microscope at 1000X for the final and fine magnification.

HPV detection and typing

Processing of samples

Thick sections from the samples were transferred to sterile (2 ml) eppendroff tubes. Paraffin was removed with warm xylene (60°C) followed by washing twice with ethanol (90% v/v). The samples were dried in a thermomixer (Bio-Rad, USA) for 30 minutes. The dried samples were transferred into centrifuges (15 ml capacity) containing 1X phosphate buffered saline (pH 7.4). The tubes were then vortexed to dissociate the cells, and centrifuged at 10,000 rpm for 10 minutes to get the cell pellet.

DNA extraction

The DNA was isolated according to the procedure mentioned in the literature.^[11] The pelleted cells were resuspended in Tris-EDTA buffer (pH 8.0) and treated with sodium dodecyl sulfate (10% w/v) and proteinase K (1% w/v) at 65 °C for one hour. The DNA was extracted using phenol, chloroform and isoamyl alcohol mixture (25:10:1 v/v) and precipitated with isopropanol. The RNA was removed by digestion with 25 µl of ribonuclease and the DNA was precipitated by adding ethanol (70% v/v), and was centrifuged at 12,000 rpm for 10 minutes. The samples of extracted DNA were made into two aliquots. One aliquot was used to look for the presence of DNA in agarose gel electrophoresis. The presence of DNA was also estimated spectrophotometrically at 260 nm.

PCR for HPV

The other aliquot of extracted DNA was subjected to PCR, for amplification of HPV DNA type 16 and 18, using type-specific primers. These type-specific primers amplified the complementary sequence of forward HPV DNA type 16, which was 5'-ATTAGTGAGTAT AGACATTA-3' and that of the reverse was 5'-GGCTTTTGACAGTTAATACA-3'. The forward and reverse sequences of HPV DNA type 18 were 5'-ACTATGGCGCGCTTTGAGGA-3' and 5'-GGTTTCTGGCACC GCAGGCA-3', respectively^[11]. The reaction mixture was carried out in a volume of 50 µl, containing the following: KCl, 100 mM; TrisHCl, 20 mM; MgCl₂, 2.0 mM; dNTP, 2.5 mM; 1.5 units of taq polymerase; 25 picomole of each primer was added to 13 µl of sterile distilled water. Then 2 µl of template DNA was added to each reaction. The reaction was performed in a DNA thermocycler MG (My Gene 25) subjecting the mixture to 40 cycles of amplification. Denaturation was done for three minutes at 94°C for the first cycle. This was followed by one minute each of denaturation at 94°C,

annealing at 54°C, and extension at 72°C, for 40 cycles. The last cycle was extended for one minute at 72°C. The PCR product was electrophoresed in 1.5% agarose gel. The gel was stained with ethidium bromide, to visualize the amplified PCR product, and the bands were visualized with the help of a UV transilluminator.

RESULTS

The presence of viral infection was evidenced by a strong nuclear expression of viral infection marker β -galactosidase HPV 6 L₁ coat fusion/capsid protein in all histological specimens of precancerous and cancerous cell malignancies, following immunohistochemical staining with mouse monoclonal antibodies HPV 6, 11, and 18 (4C4 clone, 40-233 amino acid residues). Out of 30 patients screened with clinical symptoms, the immunostaining results on distribution of HPV 6, 11, and 18 revealed that 15 expressed positive and 15 negative. None of the three normal cervical tissues were evaluated by this technique; three out of three showed no expression in the epithelial cells of both nucleus and cytoplasm, which had been classified as no infection or normal [Figure 1a]. All CIN I (4) showed strong nuclear positivity in the basal layers, whereas. CIN II (3) showed nuclear and cytoplasmic

positivity in the basal and middle layers [Figure 1b, c and d], respectively. CIN III displayed strong (2 out of 6) and showed no expression (4 out of 6) of HPV 6, 11, and 18 Ag in the nucleus as well as cytoplasm [Figure 1e]. The samples of squamous cell carcinomas displayed strong (6 out of 14) and showed no expression (8 out of 14) of HPV 6, 11, and 18 Ag in the cytoplasm, with lack of strong nuclear positivity [Figure 1f]. Out of the 27 graded cases in this study, 23 were high risk, which included CIN II (3), CIN III (6), and SCC (14), and the remaining four were low-grade (CIN I). These 23 samples were made into two aliquots. One aliquot was used to observe the presence of DNA by agarose gel electrophoresis. Furthermore, their presence was confirmed spectrophotometrically at 260 nm. The other aliquot (with 23 high grades) was taken and analyzed by PCR for the amplification of specific genotypes HPV 16 and 18. The amplified product was electrophoresed in 1.5% agarose gel, which was followed by visualization of the amplified PCR products on the gel. The photographed image of the agarose gel with the amplified PCR products, is shown in Figure 2. Figure 2 reveals that out of 23 high-grade cases detected by PCR, 15 cases were positive for HPV genotype 16, and eight cases were positive for HPV genotype 18. (The generated fragments were of 109 bp and 334 bp for HPV 16 and 18, respectively). Here, most of the lower expressed samples

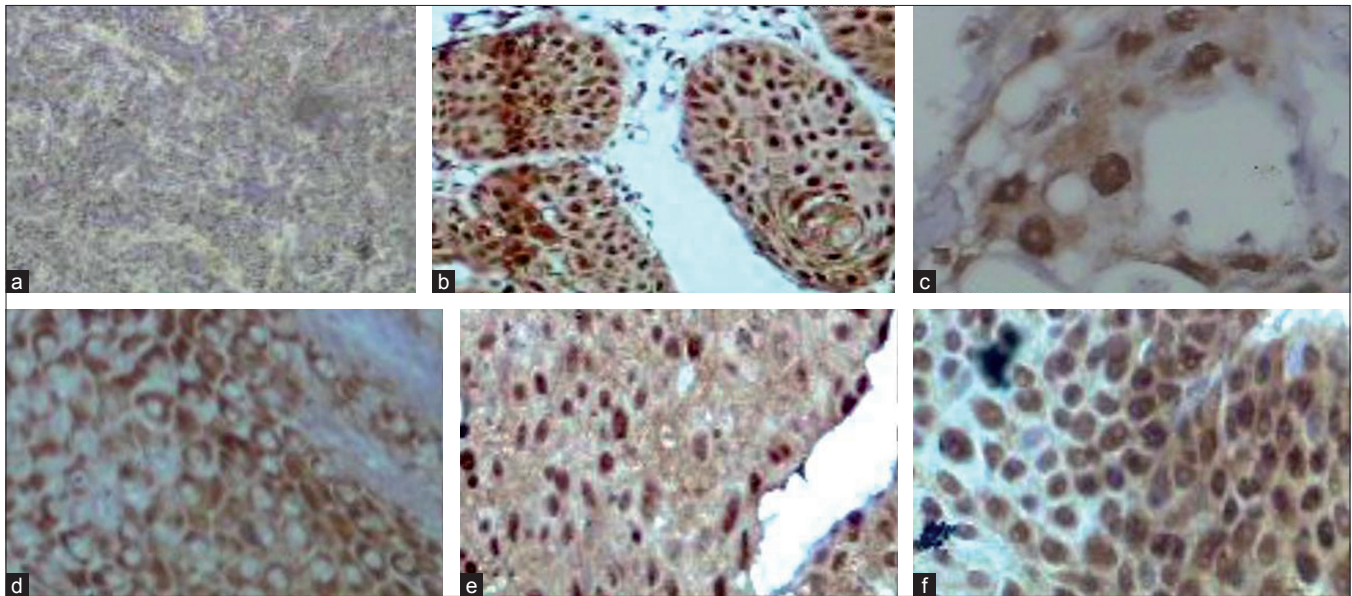


Figure 1: (a) No expression of viral infection marker in the epithelial cells of both the nucleus and cytoplasm: Absence of papilloma virus capsid protein L1 in normal cervicitis by immunohistochemistry with mouse monoclonal antibodies; (b) Nuclear expression of viral infection marker: presence of papilloma virus capsid protein L1 in CIN I by immunohistochemistry with mouse monoclonal antibodies; (c) Nuclear expression of viral infection marker in the basal and middle layers: presence of papilloma virus capsid protein L1 in CIN II by immunohistochemistry with mouse monoclonal antibodies; (d) Cytoplasmic expression of viral infection marker in basal and middle layers: presence of papilloma virus capsid protein L1 in CIN II by immunohistochemistry with mouse monoclonal antibodies; (e) Nuclear as well as cytoplasmic expression of viral infection marker in all the layers (basal, middle, upper): presence of papilloma virus capsid protein L1 in CIN III by mouse monoclonal antibodies; (f) Strong cytoplasmic expression of viral infection marker in all the layers and lack of strong nuclear positivity: presence of papilloma virus capsid protein L1 in SCC by immunohistochemistry with mouse monoclonal antibodies

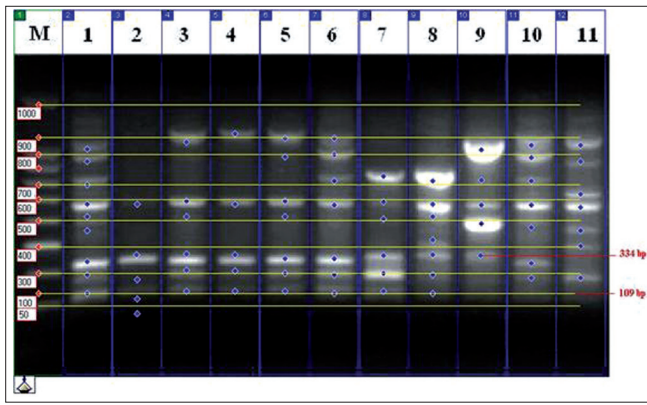


Figure 2: Agarose gel electrophoresis of amplified PCR products of HPV type 16 and HPV type 18 Lane M - Marker (100 bp Ladder); Lane - 1,3,4-8 showing positive for HPV 16 (109bp), Lane-1-9 showing positive for HPV 18 (334 bp)

in immunohistochemical staining were found to have the HPV 16 genotype. From these findings, HPV type 16 was found to be more prevalent than HPV type 18. The study on the incidence of HPV among different age groups showed that HPV infection was higher, in the range of 50–59 years of age.

DISCUSSION

Human papillomavirus has been considered as the most significant risk factor for cervical cancers. HPV is recognized as a public health problem for its role as a critical factor in the pathogenesis of various cancers.^[11]

The purpose of the present study was to assess the feasibility of staining paraffin sections for the presence of HPV with monoclonal antibodies (4C4 clone, IgG₁) raised against the coat fusion proteins. The results suggested that it was possible to detect HPV 6, 11, and 18 in the tissue sections, by using the immunohistochemical staining technique.

Immunostaining results on the distribution of HPV 6, 11, and 18 in 30 cervical biopsies of the present study, suggested that all three biopsies within normal limits showed no expression, 30% of CIN I showed nuclear positivity in the basal layers and 10% of CIN II in the cytoplasm of the basal and middle layers, whereas, 13.33% of CIN III expressed it in the nucleus, and 40% in the cytoplasm of SCC exhibited strong cytoplasmic positivity in all the layers. The strong antigenic HPV positivity of the nucleus or cytoplasm was found to be rare in 33.3% of the cases of CIN III and 66.7% of the cases of SCC. A similar technique^[12] had been adopted by using a surrogate biomarker P16^{INK 4A} for the detection of HPV in tissues of normal as well as different grades of CIN. Their study

material consisted of formalin-fixed, paraffin-embedded blocks of cervical specimens from 161 adolescents. The specimen included 15 cases of normal cervicitis, 48 cases of CIN I, 46 cases of CIN II, and 52 cases of CIN III. The results showed that all 15 biopsies within normal limits were negative for P16^{INK 4A}. The positivity of P16^{INK 4A} in CIN I was 44%. This was increased to 97% expression in CIN II and CIN III. In another study,^[13] the staining of 54 samples of formalin-fixed material of the cervix using the HPV 6, 11, and 18 antibody, showed that 40% of the cervical warts were positive for HPV 6, 11 and 18. There was no capsid protein detected in the normal and SCC using these antibodies.

Currently there is compelling evidence that the development of human cervical cancer, without the involvement of the specific HPV, is exceptional or impossible. The advanced method for diagnosis of HPV infection is based on the detection of viral DNA.^[14] As the PCR technique is highly sensitive, it is possible to detect even very low levels of HPV DNA. In the present study, high-grade biopsy samples were taken mainly for the presence of high-risk HPV types 16 and 18, using the real time PCR technique, as they were more prevalent and focused all over the world. Moreover, the percentage of HPV 16 and 18 was found to be more predominant than the other high-risk types, when screening for cervical cancer in the population-based study of South India.^[11,15-17] In addition to this, the other high-risk types could not be focused by researchers globally, as vaccine is the limiting factor.^[18] In the current study, HPV 16 and 18, in high-grade samples of CIN II(3), CIN III(6), and SCC(14) were chosen and demonstrated. The obtained results positive for HPV 16 were found to be 20% in CIN II, 26.7% in CIN III, and 53.3% in SCC; and HPV 18 was found to be 25% in CIN III and 75% in SCC. Here, most of the unexpressed graded samples in immunohistochemical staining were found to have the HPV 16 genotype when subjected to PCR. It was also suggested that HPV 16 might have produced a little capsid antigen and thus might have escaped immunohistochemical detection.^[19]

The results of high-risk HPV typing showed that HPV 16 (65.22%) was the most common type detected in our study. This was consistent with the results of other authors^[3] who had mentioned HPV 16 as the main oncogenic type of HPV associated with cervical cancer. The prevalence rate of HPV 16 among Iranian patients^[20] with cervical carcinoma was reported to be 6.7%. In the present study, the prevalence of HPV 16 among patients with cervical cancer was higher^[5] than Croatia (50%), Australia (53%), Thailand (41%), Italy (32.6%), China (48.8%), and the Philippines (43.9%); and was lower

than in Colombia (69.9%), Spain (66.4%), and Morocco (72.4%). HPV type 18 was the second-most common type with the prevalence rate of 34.78%, detected in the present study. These results were in agreement with the literature reports^[21] on cervical squamous cell cancer from Britain and South Africa. The results of two independent research findings on Iranian patients have been reported^[14,20] as 0 and 20%. The prevalence rate of HPV 18 was found^[5] to be lowest in Spain (3.7%), Columbia (4.4%), and the Philippines (27.9%). The higher HPV prevalence may be due to a difference in the number of samples, the type of case group (high-risk or low-risk group) or the cultural limitations. The prevalence of the disease is lower in countries like Iran because of the establishment of special religious and cultural bans that prevents people from involving in risky sexual contacts.^[22]

A similar study had been carried out by Zehbe *et al.*^[23] on 148 cervical biopsies, in which CIN I–III had been diagnosed and further tested for the presence of HPV DNA, using the PCR technique. The results of their study detected 93, 95, and 96% in CIN I, II, and III, respectively. However, in another study, out of 70 patients analyzed for the presence of HPV using a high-risk typing PCR kit, 49% of the cases were reported to be positive for HPV 16, which was the most common type detected in their study.^[3]

Investigation of the age classification dictates that age group 50–59 has been allocated the highest number of HPV positive cases in this study. In contrast Gita *et al.*^[3] reported the highest number of positive cases in the age group of 35–44. A study^[24] conducted on women from the Dindigul district of South India showed high HPV prevalence and particularly no decline in women of older age groups. All women with age between 35 and 55 years had high HPV or very high rates of HPV 16 and 18.

In our studies, the generated fragments were of 109 bp and 334 bp for HPV 16 and 18, respectively and were visualized on 2% agarose gels. These results are in conformity with the findings of Aggarwal *et al.*^[11]

CONCLUSION

Infection with specific types of HPV has been associated with an increased risk of cervical cancer. In view of this, the current study was carried out to detect HPV using a viral infection marker, using the polymer-based IHC method. It was found that out of 30 samples screened, 15 showed positive for HPV antigen. It is pertinent to note that this method is gaining popularity, as it does not rely on avidin-

biotin complex (ABC), as the problems associated with this can be eliminated, and thereby it results in the reduction of background noise, achieves signal amplification, and enhances sensitivity. To detect the malignancy stage, 23 high-grade biopsy specimens were subjected to real-time PCR for HPV high-risk typing. This method was found to be highly sensitive because of its possibility in detecting even very low levels of HPV DNA and in differentiating high-risk HPV types 16 and 18. Hence, it is significant that the potential usefulness of the IHC staining technique in conjugation with highly sensitive PCR is a reliable method for detecting women with HPV infection.

ACKNOWLEDGMENTS

The authors thank Dr. P.K. Rath, Department of Pathology, Doctors Diagnostic Center, Trichy, Tamil Nadu, India, for providing biopsy specimens and identifying the gradings.

REFERENCES

- Xavier BF. The burden of cervical cancer: Asia in the international perspective. *Int J Cancer* 2006;118:3030-44.
- Kraus I, Molden T, Holm R, Lie AK, Karlsen F, Kristensen GB, *et al.* Presence of E6 and E7 mRNA from human papilloma virus types 16,18,31,33 and 45 in the majority of cervical carcinomas. *J Clin Microbiol* 2006;44:1301-17.
- Gita E, Maryam G, Mohammad R, Hossein G, Afsoun T. PCR detection and high risk typing of human papillomavirus DNA in cervical cancer in Iranian women. *Cancer Ther* 2008;6:361-6.
- Walboomers JM, Jacobs MV, Manos MM, Bosch FX, Kummer JA, Shah KV, *et al.* Human papillomavirus is a necessary cause of invasive cervical cancer worldwide. *J Pathol* 1999;189:12-9.
- Nubia M, Xavier BF, Silvia S, Rolando H, Xavier C, Keerti V, *et al.* Epidemiologic classification of human papillomavirus types associated with cervical cancer. *N Engl J Med* 2003;348:6.
- Zuna RE, Allen RA, Moore WE, Lu Y, Mattu R, Dunn ST. Distribution of HPV genotypes in women with cervical lesions: evidence for three categories of intra epithelial lesions based on morphology and HPV type. *Mod Pathol* 2007;20:167-74.
- Kobayashi A, Miaskowski C, Wallhagen M, Smith Mucune K. Recent developments in understanding the immune response to human papilloma virus infection and cervical neoplasia. *Oncol Nurs Forum* 2000;27:643-51.
- Reichman RC, Braunwald E, Focci AS, Hauser SL, Longo DL, Jameson JL. Human papillomavirus. *In: Harrison's Principle of Internal Medicine* 15th Ed, 2001:1118-1120.
- Tyring SK. Human papillomavirus infection: Epidemiology, pathogenesis and host immune response. *J Am Aca Dermatol* 2000;43:18-26.
- Burd EM. Human papillomavirus and cervical cancer. *Clin Microbiol Rev* 2003;16:1-17.
- Aggarwal R, Gupta S, Nijawan R, Suri V, Kaur A, Bhasan V, *et al.* Prevalance of high risk human papillomavirus in women with benign cervical cytology: A hospital based study from North India. *Int J Cancer* 2006;43:110-6.
- Lulin H, Ming G, Zhi H, Justin T, Larry S, Daniel M, *et al.* Human papillomavirus genotyping and P16^{INK4A} expression in cervical intraepithelial neoplasia of adolescents. *Mod Pathol* 2005;18:267-73.
- Shepard P, Lunny D, Brookes R, Palmer T, Cance D. The detection of human papillomaviruses in cervical biopsies by immunohistochemistry and insitu hybridization. *Scand J Immunol* 1992;11:69-74.

14. Maleknejad P, Mohammad R, Bahram K, Farnaz F, Shadi S. Detection of human papilloma virus types 16 and 18 in pathologic samples from patients with cervical cancer by PCR and RFLP methods. *DARU* 2006; 14:78-81.
15. Clifford GM, Smith JS, Plummer M, Munoz N, Franceschi S. Human papillomavirus types in invasive cervical cancer worldwide: a meta-analysis. *Brit J Cancer* 2003;88:63-73.
16. Franceschi S, Rajkumar T, Vaccarella S, Gajalakshmi V, Sharmila A, Snijders PJ, *et al.* Human papillomavirus and risk factors for cervical cancer in Chennai, India: A case-control study. *Int J Cancer* 2003;107:127-33.
17. Sowjanya AP, Jain M, Poli UR, Padma S, Das M, Shah KV, *et al.* Prevalence and distribution of high-risk human papillomavirus (HPV) types in invasive squamous cell carcinoma of the cervix and in normal women in Andhra Pradesh, India. *BMC Infect Dis* 2005;5:116.
18. Frazer I. God's gift to women: the human papilloma virus vaccine. *Immunity* 2006;25:179-84.
19. Roman A, Fife KH. Human papillomaviruses: Are we ready to type? *Clin Microbiol Rev* 1989;2:166-90.
20. Farjadian S, Asadi E, Dorodchi M, Samsami D A, Tabei SZ, Kumar VP, *et al.* High risk HPV types in southern Iranian patients with cervical cancer. *Pathol Oncol Res* 2003;9:121-5.
21. Cooper K, Herrington CS, Graham AK, Evans MF, Mc Gee Jo D. In situ evidence for HPV 16, 18,33 integration in cervical squamous cell cancer in Britain and South Africa. *J Clin Pathol* 1991;44:406-9.
22. Golshani M, Eslami G, Mohammadzadeh Ghobadloo SH, Fallah F, Goudarzi H, Soleimani Rahbar A A, *et al.* Detection of Chlamydia trachomatis, Mycoplasma hominis and Ureaplasma urealiticum by Multiplex PCR in semen sample of fertile men. *Iran J Publ Health* 2007;36:50-7.
23. Zehbe I, Eva R, Karin E, Goran W, Erik W. Detection of human papilloma virus in cervical intraepithelial neoplasia, using in situ hybridization and various polymerase chain reaction techniques. *Virchows Arch* 1996;428:151-7.
24. Silvia F, Rolando H, Gary M. C, Peter J.F, Annie A, Xavier B, *et al.* Variations in the age-specific curves of human papilloma virus prevalence in women worldwide. *Int J Cancer* 2006;119:2677-84.

Source of Support: Nil, **Conflict of Interest:** None declared.