

Atypical Presentation of Visceral Leishmaniasis in a HIV-positive Patient from a Nonendemic Area

Dhara H Vyas, Parul D Shah

Department of Microbiology, Smt. N. H. L. Municipal Medical College, Ellisbridge, Ahmedabad, India

Address for correspondence: Dr. Parul D. Shah, E-mail: parulshah_12@yahoo.co.in

ABSTRACT

Visceral leishmaniasis (VL), though widely prevalent in India, is not seen in the Rajasthan where the dry, hot and arid climatic conditions create a hostile environment for the growth of the parasite or its vector, the sandfly. We present a case of VL in a patient co-infected with HIV from this region. A 34-year-old known case of a HIV-positive patient presented to the skin department of our hospital with multiple, nontender, erythematous, papulonodular lesions all over the body for 6 months with history of weight loss and low-grade fever. Important examination findings were pallor, inguinal lymphadenopathy and hepatosplenomegaly. Laboratory findings included anemia, leucopenia, hypergammaglobulinemia and altered leucocytes to erythrocyte ratio. Buffy coat examination and bone marrow aspirates showed the presence of leishman bodies inside monocytes and macrophages respectively as well as extracellularly also. The patient was treated with amphotericin B intravenously and responded well to the treatment.

Keywords: HIV positive, leishman bodies, visceral leishmaniasis

INTRODUCTION

Leishmaniasis is a chronic inflammatory disease of the skin, mucous membranes or viscera caused by obligate intracellular parasites transmitted through bite of infected sandflies of the genus *Phlebotomus*.^[1] Leishmaniasis consists of four main clinical syndromes: cutaneous leishmaniasis (CL); muco-cutaneous leishmaniasis; visceral leishmaniasis (VL; also known as kala-azar); and post kala-azar dermal leishmaniasis (PKDL).^[2]

Leishmaniasis is endemic throughout the Middle East, South Asia including India, Africa, and Latin America.^[1] The annual estimate for the incidence and prevalence of VL cases worldwide is 0.5 million and 2.5 million, respectively. Of these, 90% of the confirmed cases occur in India, Nepal, Bangladesh and Sudan. In India VL is prevalent in the eastern

states having a hot and humid climate while the drier western parts of the country are home to CL.^[2] In India, VL is a serious problem in Bihar, West Bengal and eastern Uttar Pradesh while sporadic cases have also been reported from Gujarat, Tamil Nadu and Kerala and sub Himalayan parts of north India including Himachal Pradesh and Jammu and Kashmir. The first evidence for existence of CL was based on clinico epidemiologic analysis of cases in 1973 during a large scale outbreak of the disease in Bikaner. Surveys carried out revealed the presence of sporadic cases in Rajasthan at Hanumangarh (Sriganganagar district), Jodhpur city and rural and urban areas of the Bikaner district.^[3]

Recent outbreaks of VL in India and the epidemic of HIV have made VL a re-emerging problem in India.^[4] Outbreaks and epidemics of leishmaniasis have also been associated with urban development, deforestation, environmental changes and population migrations.^[5]

CASE REPORT

A 34-year-old patient from Rajasthan presented to our skin department with multiple skin lesions all

| Access this article online | |
|--|---|
| Quick Response Code:  | Website: www.jlponline.org |
| | DOI: 10.4103/0974-2727.86847 |

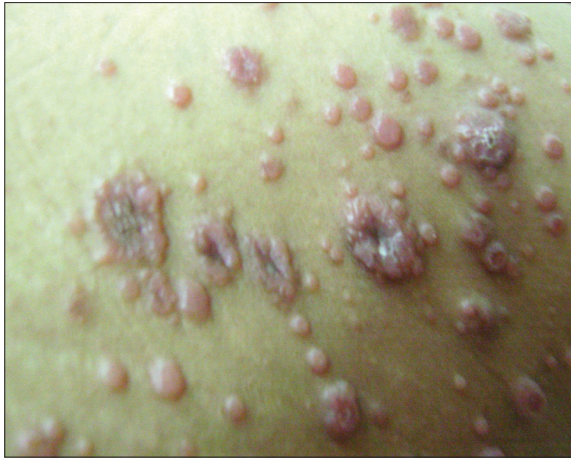

Figure 1: Multiple erythematous, nodular and umbilicated skin lesions

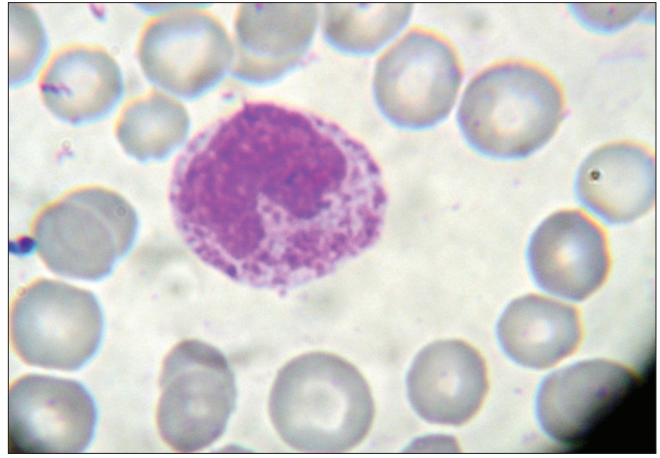


Figure 2: Photomicrograph showing ovoid LD bodies within monocytes in peripheral smear (x100)

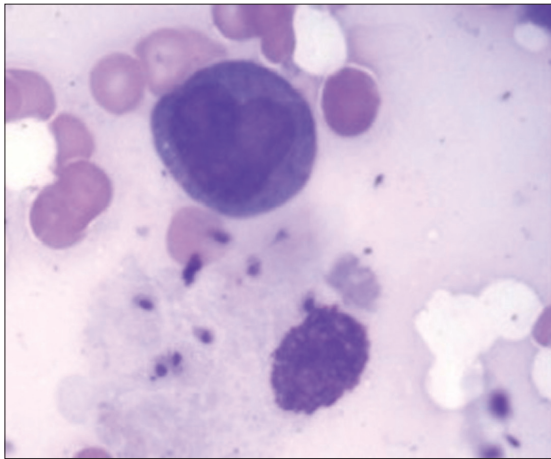


Figure 3: Bone marrow aspiration smear showing LD bodies extracellularly (x100)

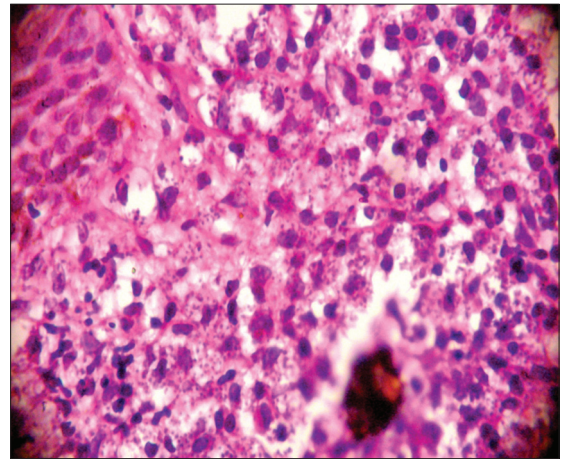


Figure 4: Biopsy from a skin lesion showing dense dermal infiltration with histiocytes along with LD bodies intracellularly as well as extracellularly in HE stain (x100)

over the body for 6 months. The patient had nontender, erythematous, papulonodular skin lesions along with a history of weight loss for 6 months and low-grade fever for 1 month. The patient denied ever visiting any endemic area of VL. The patient took treatment in Rajasthan, but lesions did not subside. The patient was screened for HIV and found to be positive. The patient was referred to our hospital for diagnosis and further management.

On general examination the patient was pale, weak and emaciated. Bilateral inguinal lymphadenopathy was present. Per abdomen examination revealed massive splenomegaly and mild hepatomegaly. On local examination multiple, discrete, erythematous, papulonodular lesions [Figure 1] were found to be present all over the body including face, chest, arms, forearms, back, trunk, buttock and lower limbs. Lesions showed central umbilication without ulceration of nodules. Laboratory investigations included routine hemogram which showed anemia (Hb- 9.82%) and leucopenia (total count- 2980/mm³). Leucocyte

to erythrocyte ratio was 1.2:1000 (altered). Peripheral smear examination suggested the presence of microcytic hypochromic RBCs with anisocytosis and elliptocytosis. The most striking feature in peripheral smear along with the above findings was abundance of amastigote forms of Leishman bodies both intracellularly within the monocytes [Figure 2] as well as extracellularly. Multiple blood samples were taken and findings were reconfirmed. After confirming the parasites in peripheral blood smear in repeated samples, buffy coat was prepared from the EDTA blood sample of the patient which also showed the presence of multiple Leishman bodies within monocytes. Then bone marrow aspiration from the sternum was performed, revealing erythroid hyperplasia with normoblastic erythropoiesis along with Leishman bodies [Figure 3]. CD₄ percentage was 10% and the absolute CD₄ count was 187/μl. Serum globulins were high (4.90 g/dl) and A/G ratio was low (0.65). FNAC from skin nodules showed numerous organisms consistent with Leishman

bodies. Histopathology from skin biopsy suggested dense diffuse pan dermal infiltrates of histiocytes with numerous intracellular and extracellular organisms [Figure 4]. Tests for malaria, syphilis, hepatitis and enteric fever were negative.

The patient was started with fungizone (amphotericin B) intravenously and antiretroviral drugs (Zidovudine, Lamivudine and Nevirapine) in standard doses. On discharge, the patient's condition was good. The patient came for follow up after 3 months, when there was complete resolution of cutaneous lesions and other symptoms.

DISCUSSION

VL is common in less developed countries, with an estimated 5,00,000 new cases each year.^[1] Because of the diversity of epidemiological situations, no single diagnosis, treatment, or control will be suitable for all. The usual incubation period of VL is 2–6 months. The classic presentation of VL includes fever, weight loss, hepatosplenomegaly, pancytopenia, and hypergammaglobulinemia. HIV co-infection may alter typical presentation, but cutaneous involvement of VL is a rare finding. It is seen in 2-12% of patients with HIV/*Leishmania* co-infection.^[6] These lesions can occur simultaneously with a bout of VL and can be papular, maculopapular or nodular. Most patients with HIV who present with VL are in a state of advanced immunodeficiency: up to two-thirds of patients with concomitant HIV and *L. donovani* infection have CD₄ counts < 200 cells/ μ l.^[7] Rajasthan is a home to CL, so the possibility of visceralisation of cutaneous leishmaniasis has to be ruled out. But the presence of systemic signs and symptoms along with the absence of ulceration of nodules also favor cutaneous manifestations of visceral leishmaniasis. As we have not performed the immunological and molecular tests to confirm the diagnosis, it remains the limitation of this case report.

HIV infection increases the risk of developing VL by 100 to 2,320 times in areas of endemicity. At the same time, VL promotes the clinical progression of HIV disease and development of AIDS-defining conditions.^[8] In India, the first *Leishmania*-HIV co-infection case was reported in 1999, later five more reports of *Leishmania*-HIV co-infection were published.^[9,10] The epidemiological impact of co-infection is so significant that the World Health Organization is considering introducing VL as an AIDS indicator-disease.^[11]

Examination of a bone marrow smear is often the most useful diagnostic test (sensitivity, 67-94%), and aspirates from other sites can be considered depending on the clinical

presentation. We could identify *Leishmania* parasites in Buffy coat examination of peripheral smear as well as in bone marrow aspirates, extracellularly and intracellularly. Other parameters which are associated with leishmanial infection like anemia, leucopenia, and hypergammaglobulinemia as well as altered leucocytes to erythrocyte ratio were also present. ELISA and PCR, are of utmost importance for confirmed diagnosis, however, these are often beyond the reach of the poor in the country.

The *Leishmania*-HIV co-infection has serious implications for patient management as the visceral strains can manifest in atypical forms localizing to mucus membranes and skin while dermatrophic strains can cause visceral disease.^[10] Treatment options include pentavalent antimonials such as sodium stibogluconate, lipid formulations of amphotericin B, miltefosine, paromomycin and pentamidine.^[12]

In conclusion, early diagnosis of *Leishmania* cases is necessary mainly when co-infected with HIV or presented with atypical manifestations like nodular cutaneous lesions or when the patient is coming from a non-endemic region.

REFERENCES

1. Mc Adam AJ, Sharpe AH. Infectious diseases. In: Robbins and Cotran, editors. Pathologic Basis of Disease. 7th ed. New Delhi: Elsevier Publishers; 2004 .p. 403-5.
2. Arevalo, J. Influence of *Leishmania* (viannia) species on the response to antimonials treatment in patients with American tegumentary leishmaniasis. J Infect Dis 2007;195:1846-51.
3. Kesavan A, Parvathy VK, Thomas S, Sudha SP. Indigenous visceral leishmaniasis: two cases from Kerala. Indian J Pediatr 2003;40:373-4.
4. Redhu NS, Dey A, Balooni V, Singh S. *Leishmania*-HIV co-infection: an emerging problem in India. AIDS 2006;20:1213-5.
5. Desjeux P. Leishmaniasis: current situation and new perspectives. Comp Immunol Microbiol Infect Dis 2004;27:305-18.
6. World Health Organization. Report of the consultative meeting on Leishmania/HIV co-infection. Vol.95. Geneva: WHO/LEISH; 1995. p. 1-14.
7. ter Horst R, Collin SM, Ritmeijer K, Bogale A, Davidson RN. Concordant HIV infection and visceral leishmaniasis in Ethiopia: the influence of antiretroviral treatment and other factors on outcome. Clin Infect Dis 2008;46:1702-9.
8. Olivier M, Badaró R, Medrano FJ, Moreno J. The pathogenesis of Leishmania/HIV co-infection: cellular and immunological mechanisms. Ann Trop Med Parasitol 2003;97(Suppl 1):79-98.
9. Singh S. Mucosal Leishmaniasis in an Indian AIDS patient. Lancet Infect Dis 2004;4:660-1.
10. Singh S, Kumar J, Singh R, Dwivedi SN. Hepatitis B and C viral infections in Indian kala-azar patients receiving injectable anti-leishmanial drugs: a community-based study. Int J Infect Dis 2000;4:203-8.
11. Malafaia G. Coinfection HIV/Leishmania: a serious problem of Public Health. Rev Saude Publica 2009; 43:195.
12. Alvar J, Aparicio P, Aseffa A, Den Boer M, Cañavate C, Dedet JP, et al. The relationship between leishmaniasis and AIDS: the second 10 years. Clin Microbiol Rev 2008;21:334-59.

How to cite this article: Vyas DH, Shah PD. Atypical presentation of visceral leishmaniasis in a HIV-positive patient from a nonendemic area. J Lab Physicians 2011;3:119-21.

Source of Support: Nil. **Conflict of Interest:** None declared.