

Reactive Thrombocytosis in H1N1 Infection

Sir,

Platelets are acute-phase reactants and their increased production secondary to systemic infections, inflammatory conditions, bleeding, and tumors is termed as reactive thrombocytosis.^[1] We present a case series of three patients with H1N1 infection in which thrombocytosis was detected as an incidental laboratory abnormality and discuss the clinical implication and possible mechanism for the high platelet count.

Three young patients with no co-morbidities presented with flu-like illness of three days duration followed by sudden onset of shortness of breath. H1N1 infection was confirmed by real-time reverse-transcriptase–polymerase-chain-reaction (TaqMan A/H1N1) assay. Intensive care and invasive mechanical ventilation was needed for management of acute respiratory distress syndrome (ARDS). During their stay in intensive care unit (ICU), reactive thrombocytosis (RT), defined as platelet count above $450 \times 10^3/\text{mm}^3$ was detected as an incidental laboratory abnormality. The thrombocytosis was benign, and so no treatment was initiated for high platelet counts [Figure1]. Onset, peak, and termination of RT were seen on 10-14-26; 3-9-15; and 8-12-16 day of ICU admission in the three patients, respectively. The maximum platelet counts were 9.15 , 9.8 and $7.85 \times 10^5 \text{cells}/\text{mm}^3$, respectively, in the three patients. This coincided with the resolution of the systemic inflammatory response (evaluated using systemic inflammatory response syndrome [SIRS] criteria) and the clinical recovery. Erythrocyte sedimentation rate (ESR), a non-specific measure of inflammation was between 20-40 mm/hr during the period of RT, but normalized with clinical recovery. C-reactive protein (CRP) levels, however, could not be done.

Secondary thrombocytosis is due to the overproduction of proinflammatory cytokines such as interleukin (IL)-1, IL-6, and IL-11.^[1] A "cytokine storm" is a potentially fatal

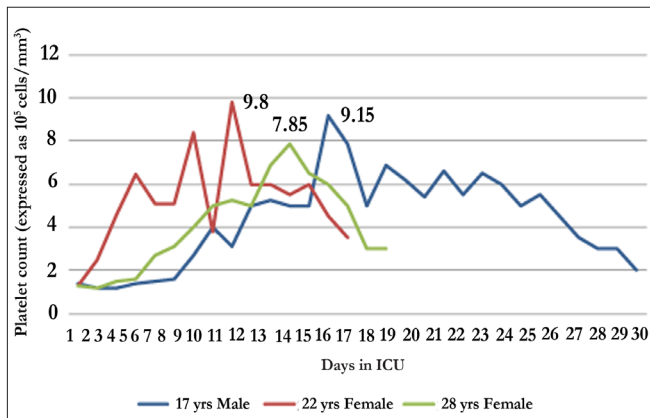


Figure 1: Reactive thrombocytosis in H1N1 (+) patients

immune reaction with highly elevated levels of both pro-inflammatory cytokines and anti-inflammatory cytokines.^[2] The precise reason for this is not entirely understood, but it is the systemic expression of a healthy and vigorous immune system as seen in young age group (15-50 years). Cytokine storms have been reported in 1918 influenza pandemic during the SARS epidemic in 2003^[3] and recently among healthy young adults in the 2009 swine flu outbreak. RT seen in our patients could be a manifestation of "cytokine storm".

The role of increased platelet count in the pathophysiology of thrombotic process after coronary bypass surgery is highlighted in a previous study.^[4] Significantly higher ($P < 0.001$) incidence of postoperative myocardial infarction and late symptomatic vein graft occlusion (7-60 days) was reported in patients with RT in comparison to those with normal platelet counts. Thus, RT secondary to H1N1 infection can predispose patients admitted in ICU to life threatening complications secondary to deep vein thrombosis and pulmonary embolism. Previous studies conducted in trauma patients do not support the role of antiplatelet agents in treatment of extreme thrombocytosis.^[5] Thus, low-molecular-weight heparin and vascular compression stockings are advised in such patients. This case series highlights the occurrence and clinical significance of RT in H1N1 positive patients. Small number of patients studied is a limitation of our case series and thus further research is needed.

T Samra, M Pawar

Department of Anesthesia,
Dr. Ram Manohar Lohia Hospital, Connaught Place,
New Delhi, India

Address for correspondence: Dr. Tanvir Samra,
E-mail: drtanvirsamra@yahoo.in

REFERENCES

1. Vora AJ, Lilleyman JS. Secondary thrombocytosis. Arch Dis Child 1993;68:88-90.
2. Kobasa D, Jones SM, Shinya K, Kash JC, Copps J, Ebihara H, *et al.* Aberrant innate immune response in lethal infection of macaques with the 1918 influenza virus. Nature 2007;445:319-23.
3. Huang KJ, Su IJ, Theron M, Wu YC, Lai SK, Liu CC, *et al.* An interferon-gamma-related cytokine storm in SARS patients. J Med Virol 2005;75:185-94.
4. Schmuziger M, Christenson JT, Maurice J, Simonet F, Velebit V. Reactive thrombocytosis after coronary bypass surgery. An important risk factor. Eur J Cardiothorac Surg 1995;9:393 -7.
5. Saadi Z, Inaba K, Barmparas G, Salim A, Talving P, Plurad D, *et al.* Extreme thrombocytosis in trauma patients: are antiplatelet agents the answer? Am Surg 2009;75:1020-4.

Access this article online	
Quick Response Code: 	Website: www.jlponline.org
	DOI: 10.4103/0974-2727.86852