

Treatment and follow-up of a case of bleeding duodenal varix

Viveksandeep Thoguluva Chandrasekar, Gokul Bollu Janakan, Rajesh Venkatachalam, Chandrasekar Thoguluva Seshadri

Department of Gastroenterology, MedIndia Institute of Medical Specialities, Chennai, Tamil Nadu, India

Abstract

Duodenal varices (DV) are rare in patients with portal hypertension secondary to liver disease. Their tendency to bleed is less common than in gastroesophageal varices, but can sometimes produce a life-threatening bleed. They are often difficult to diagnose and treat. We present a case of a 35-year-old man with parenchymal liver disease admitted with complaints of hematemesis and melena. Upper gastrointestinal endoscopy was performed and a duodenal varix, with stigmata of a recent bleed, was noted in the second part of the duodenum. Five milliliters of N-butyl-2-cyanoacrylate glue was injected into the varix leading to obliteration. A follow-up study with an endoscopic ultrasound and repeat endoscopy showed near total obturation of the varix and success of the therapy. This report concludes that glue injection can effectively be used as a first-line treatment for bleeding duodenal varices.

Key words

Duodenal varices, endoultrasound, endoscopic ultrasound, gastrointestinal bleed, glue injection, portal hypertension

Introduction

Duodenal varices are an uncommon cause of upper gastrointestinal (UGI) bleeding. They are ectopic varices that occur due to portosystemic collaterals. Such ectopic varices are also found in the fundus, body, and antrum of the stomach, small bowel, extra and intrahepatic biliary tract, intraperitoneum, colon, anorectum, bladder, vagina, and adjacent to a surgically created stoma.^[1] We report the case of a bleeding duodenal varix in a case of cirrhosis, treated successfully with N-butyl-2-cyanoacrylate glue injection, followed up with an endoscopic ultrasound (EUS).

Case Report

A 35-year-old gentleman, a chronic alcoholic, presented

to our hospital with a history of hematemesis and melena. On examination the pulse rate was 94 per minute and blood pressure was 100/60 mm Hg. He had pallor, mild icterus, and ascites. His laboratory values showed: Hemoglobin - 6.4 g/dl, hematocrit - 19%, blood urea - 46 mg/dl, serum creatinine - 1.0 mg/dl, total bilirubin - 2.7 mg/dl, total protein - 4.4 g/dl, albumin - 2.1 g/dl, A/G ratio - 0.91, AST - 53 IU/L, ALT - 45 IU/L, ALP - 120 U/L, prothrombin time - 26.3 (control-14 seconds), and INR - 2.2. The serological markers for Hepatitis B and C were negative. An ultrasound of the abdomen showed features of chronic parenchymal liver disease, moderate ascites, and a dilated portal vein without thrombosis. After correcting the coagulopathy, an upper gastrointestinal (UGI) endoscopy revealed a column of grade 1 esophageal varix and congestive gastropathy without active bleeding. A large, tortuous and bluish varix was noted in the second part of the duodenum, with stigmata of a recent bleed. Five milliliters of N-butyl-2-cyanoacrylate (GESIKA, New Medicon Pharma, India) tissue adhesive glue was injected at five different sites into the varix, not exceeding 1 ml at each site [Figure 1]. During glue injection, demonstration of the catheter pull sign was positive and that of the red catheter sign was negative. These signs predicted an immediate puncture site bleed on withdrawal of the needle catheter during glue injection for fundal varices^[2] and possibly

Access this article online

Website: www.jdeonline.in	Quick Response Code 
DOI: 10.4103/0976-5042.132428	

Address for correspondence:

Dr. Chandrasekar Thoguluva Seshadri, 83, Valluvar Kottam High Road, Nungambakkam, Chennai - 600 034, Tamil Nadu, India. E-mail: tscmedindia@yahoo.com

for duodenal varices too. There was no active bleeding on withdrawal of the needle catheter and the whole procedure was uneventful. As the diagnosis of varix was obvious endoscopically, diagnostic EUS was not performed before endotherapy. Follow-up endoscopy done on the fifth day after the treatment showed no active bleeding [Figure 2]. EUS with Doppler mode examination on the same day showed a 3×3.5 cm varix in the second part of the duodenum with few internal echoes indicating near total obturation of the varix and thus a success of endotherapy [Figure 3]. The hemoglobin improved to 10.6 g/dl and the patient was discharged.

Discussion

Duodenal varices as a source of UGI bleed were first reported in the literature by Alberti, in 1931. They usually have afferents from the superior or inferior pancreaticoduodenal veins or superior mesenteric vein (SMV) forming a retroperitoneal plexus and drain via the veins of Retzius into the Inferior Vena Cava.^[3] The exact prevalence of duodenal varices is not known, as 40% of the patients with portal hypertension have duodenal varices on angiography, while only 0.4% have endoscopic incidence on a nine-year follow-up of patients with portal hypertension.^[4,5] This is because of the submucosal and serosal location of the varices,^[6] which sometimes make them difficult to diagnose by endoscopy. Duodenal varices are more common in extra-hepatic portal hypertension due to thrombosis of the splenic vein, SMV, and portal vein, accounting for 70% of the cases, according to the review by Amin *et al.*^[6] However, liver cirrhosis as intrahepatic etiology is the single leading cause of duodenal varices accounting for 30% of the cases.^[5,6] The varices are most commonly found in the duodenal bulb (48%), with their incidence decreasing distally.^[6] About 50% of the duodenal varices are associated with esophageal varices according to Khoqueer *et al.*^[7]

Ectopic varices contribute to 1-5% of variceal bleeding, with the duodenum accounting for 17% of them.^[4] Bleeding from duodenal varices occurs when they expand submucosally and is associated with 40% mortality after the initial bleeding episode.^[7] Before the advent of EUS, various modalities like barium studies, upper GI endoscopy, capsule endoscopy, angiography, splenoportography, 3D multi-slice detector computed tomography (CT) scan, CT angiography, and laparotomy have been used for the diagnosis of varices. In recent years, EUS has taken a lead role in the diagnosis and for assessing the effectiveness of endoscopic intervention of the varices. They can be used to check the blood flow within the collaterals and also to see the residual flow after endotherapy.

According to the literature, initially surgical techniques like variceal ligation via duodenotomy, excision of varices, splenorenal shunting, and duodenectomy were performed, but with a postsurgical mortality rate up to 30%.^[7] However,

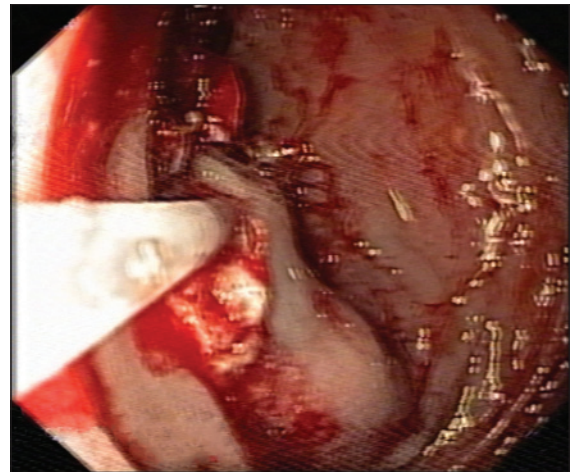


Figure 1: Glue injection into the bleeding duodenal varix

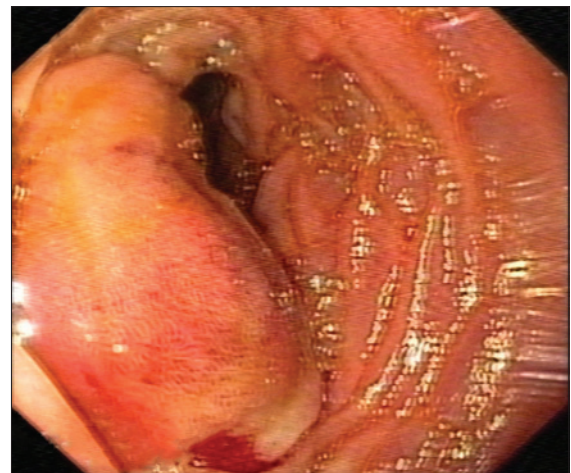


Figure 2: Post glue injection status of the duodenal varix

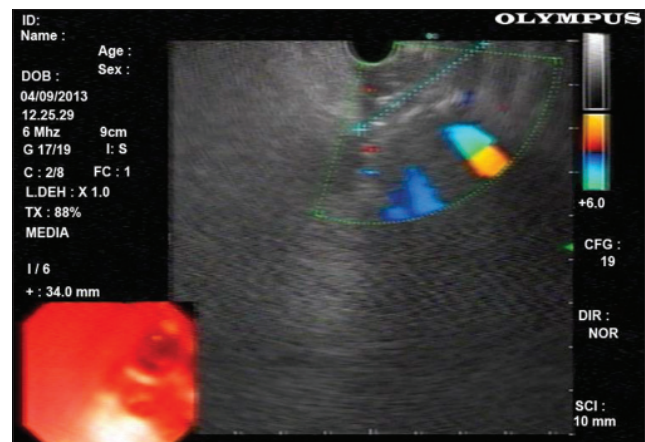


Figure 3: EUS examination of the duodenal varix after glue injection, showing few internal echoes indicating near total obturation of the varix

with the advent of endoscopy, techniques such as endoscopic band ligation, hemoclips, and sclerotherapy, with agents like histoacryl and N-butyl-2-cyanoacrylate have been used.^[8] Endoscopic intervention remains, to date, the most frequently performed therapy, because it is easier,

faster, less invasive, and the most effective treatment for varices. Endoscopic sclerotherapy with glue polymerizes on contact with blood and causes obliteration of the varix.^[9] N-butyl-2-cyanoacrylate causes less tissue damage than other agents. The duodenal wall is relatively thinner than in other parts of the upper GI tract, which puts it at a higher risk of perforation during endotherapy.^[8] Despite the theoretical risk of complications like embolism, portal vein thrombosis, tissue injury, and perforation, glue injection has been safely practiced as an effective first-line treatment for varices. When endoscopic methods fail, radiological interventions such as Balloon occluded retrograde transvenous obliteration (BRTO), transjugular intrahepatic portosystemic shunt, transileocolic vein obliteration and surgical procedures like portocaval shunts have been performed.^[10]

Conclusion

Duodenal varices as a source of upper GI bleeding should be considered in cases of portal hypertension, particularly when there are no gastroesophageal varices or if these patients have been previously treated for varices with sclerotherapy. EUS appears to be a promising modality in assessing the response to endotherapy for DV. Tissue adhesive glue injection remains one of the first-line treatments for duodenal varices, with excellent results, as demonstrated in our case.

References

1. Helmy A, Al Kahtani K, Al Fadda M. Updates in the pathogenesis, diagnosis and management of ectopic varices. *Hepatol Int* 2008;2:322-34.
2. Chandrasekar TS, Menachery J, Gokul BJ, Muruges M, Vivek Sandeep TC. Novel predictors for immediate puncture site bleed during endoscopic glue injection for gastric varices without using lipiodol. *Indian J Gastroenterol* 2013;32:200-3.
3. Itzhak Y, Glickman MG. Duodenal varices in extrahepatic portal obstruction. *Radiology* 1977;124:619-24.
4. Norton ID, Andrews JC, Kamath PS. Management of ectopic varices. *Hepatology* 1998;28:1154-8.
5. Hashizume M, Tanoue K, Ohta M, Ueno K, Sugimachi K, Kashiwagi M, et al. Vascular anatomy of duodenal varices: Angiographic and histopathological assessments. *Am J Gastroenterol* 1993;88:1942-5.
6. Amin R, Alexis R, Korzis J. Fatal ruptured duodenal varix: A case report and review of literature. *Am J Gastroenterol* 1985;80:13-8.
7. Khouqeer F, Morrow C, Jordan P. Duodenal varices as a cause of massive upper gastrointestinal bleeding. *Surgery* 1987;102:548-52.
8. Desai RK, Tagliabue JR, Wegryn SA, Einstein DM. CT evaluation of wall thickening in the alimentary tract. *Radiographics* 1991;11:771-84.
9. Malik A, Junglee N, Khan A, Sutton J, Gasem J, Ahmed W. Duodenal varices successfully treated with cyanoacrylate injection therapy. *BMJ Case Rep* 2011;2011.
10. Attila T, Kolbeck KJ, Bland ZM, Wang A, Rodriguez SA. Duodenal variceal bleeding successfully treated with transjugular intrahepatic portosystemic shunt: A case report and review of the literature. *Turk J Gastroenterol* 2008;19:284-90.

How to cite this article: Chandrasekar VT, Janakan GB, Venkatachalam R, Seshadri CT. Treatment and follow-up of a case of bleeding duodenal varix. *J Dig Endosc* 2013;4:128-30.

Source of Support: Nil, **Conflict of Interest:** None declared.

Announcement

Android App



A free application to browse and search the journal's content is now available for Android based mobiles and devices. The application provides "Table of Contents" of the latest issues, which are stored on the device for future offline browsing. Internet connection is required to access the back issues and search facility. The application is compatible with all the versions of Android. The application can be downloaded from <https://market.android.com/details?id=comm.app.medknow>. For suggestions and comments do write back to us.