

Case Report

Bannayan-Rilay-Ruvalcaba syndrome presenting with recurrent lower gastrointestinal bleed: A case report and a review of the literature

Jaswinder Singh Sodhi, Abid Shoukat, Zaffar Ali Wani, Rayees Ahmed, Shaheen Nazir, Zaffar Iqbal Kawoosa

Department of Gastroenterology, Sher-i-Kashmir Institute of Medical Sciences, Srinagar, Jammu and Kashmir, India

Abstract

Bannayan-Rilay-Ruvalcaba syndrome (BRRS) is a rare congenital disorder, characterized by macrocephaly, hamartomas, lipomas, and genital lentiginosis with or without *PTEN* gene mutations. We report a case of BRRS in a 12-year-old male child with recurrent bleeding per rectum with hamartomatous intestinal polyposis involving whole colon and few polyps in stomach and first part of duodenum; small subcutaneous lipomas over left lumbar area. In addition patient had macrocephaly, cutaneous hyperpigmentation with lentiginosis, and pigmented freckles on the external genitalia. Bleeding polyps were removed with snare polypectomy. Patient was put on iron supplements and is on regular follow-up.

Key words

Bannayan-Rilay-Ruvalcaba syndrome, hamartomatous intestinal polyposis, lipomas, lower gastrointestinal bleed, macrocephaly, penile lentiginosis

Introduction

Bannayan-Rilay-Ruvalcaba Syndrome (BRRS) is a rare congenital, autosomal dominant disorder, characterized by macrocephaly, hamartomas, lipomas, intestinal polyposis (hamartomatous) and genital lentiginosis. The prevalence of BRRS is unknown. Several dozen cases have been reported however the disorder is under-diagnosed as its signs and symptoms vary and some of them are subtle. The disorder may be associated with mutation in tumour suppression gene (*PTEN*) in about half of cases which leads to an increased risk of developing certain cancers. The presentation varies according to age and site of involvement of organs. Cancer surveillance is recommended in case of *PTEN* gene mutation.^[1-3] We report this rare syndrome in a 12 year old

male child with symptoms of recurrent lower gastro intestinal bleed due to colonic polyposis.

Case Report

A 12-year-old male child was admitted with history of intermittent bleeding per rectum for the last 6 years. Bleeding was intermittent, small in amount, painless, bright red drops of blood after defecation. Patient denied any history of pain, while defecation, rectal prolapse, abdominal pain, distension, constipation, loose motions, fever, rash, abnormal bleeding tendency, visual disturbances, or headache. Patient had earlier consulted various physicians and was put on iron tablets without any further investigations. Patient was a product of nonconsanguineous marriage with full-term normal delivery and had achieved normal developmental milestones. He had three sisters and one brother who were reported as normal. General physical examination revealed moderate pallor, normal oral cavity. There was no jaundice, cyanosis, edema, thyromegaly, lymphadenopathy, clubbing, or scoliosis. His pulse was 78 beats/min, blood pressure (BP) 100/70 mmHg, and respiratory rate 20/min. Skin on the arm and chest revealed patch of increased pigmentation. Dermatologist's opinion was sought and reported it as cutaneous hyperpigmentation

Access this article online

| | |
|---|---|
| Website: www.jdeonline.in | Quick Response Code  |
| DOI: 10.4103/0976-5042.132436 | |

Address for correspondence:

Dr. Jaswinder Singh Sodhi, Department of Gastroenterology, Sher-i-Kashmir Institute of Medical Sciences, Srinagar - 190 011, Jammu and Kashmir, India.
E-mail: Jassi_win@rediffmail.com

with lentiginosis [Figure 1]. Left lumbar area revealed small subcutaneous swellings. Aspiration cytology of these swellings revealed lipoma. External genitalia revealed freckle-like spots (pigmented macules) on the penis [Figure 2]. There were no bony abnormalities or any abnormality affecting the muscles. Chest, cardiovascular, and central nervous systems were normal with normal optic fundus.

Anthropometric examination revealed macrocephaly with head circumference of 60 cm (>97 percentile), height 140 cm, weight 39 kg (expected weight 32 kg), and arm span 138 cm. Lab investigations revealed hypochromic microcytic anemia with hemoglobin (Hb) 9.1 g/dl and mean cell volume (MCV) 76, coagulogram revealed prothrombin time 13.7, international normalized ratio (INR) 1.3, and activated partial thromboplastin time (aPTT) 24.4. Colonoscopy revealed whole colon studded with polyps of varying size (polyposis coli) with intervening normal mucosa [Figure 3]. There were three large polyps more than 2.5 cm; two in the rectum and one in the descending colon. One of the polyps in rectum was oozing blood near head region. These three polyps were removed by polypectomy snare and one of them retrieved for histopathology. Upper gastrointestinal (GI) endoscopy done under general anesthesia revealed scattered polyps in the stomach and multiple polyps in first and second parts of duodenum. One polyp was removed with snare polypectomy. Histopathology of colonic and gastric

polyps revealed mucosa and submucosa with dilated glands and chronic inflammation, features were consistent with hamartomatous polyp with inflammation [Figure 4a and b]. Small bowel evaluation by 64-slice CT enterography revealed few polyps in first and second part of duodenum, while rest of small bowel appeared normal. In family screening, patient had three sisters and one brother who were called and examined and were found as normal. On the basis of clinical features of macrocephaly, penile lentiginosis, lipomas, and intestinal hamartomatous polyposis; a diagnosis of Bannayan-Rilay-Ruvalcaba Syndrome (BRRS) was made. *PTEN* gene mutation analysis could not be done. Presently, patient is on iron therapy for anemia and is on regular follow-up.

Discussion

BRRS is the combination of previous three recognized syndromes that is Bannayan-Zonana syndrome, Ruvalcaba-Myhre-Smith syndrome, and Riley-Smith syndrome.^[1] DiLiberti, et al. suggested that Ruvalcaba-Myhre-Smith syndrome and Bannayan-Zonana syndrome represent phenotypic variability resulting from mutation at a single genetic locus and later proposed a new nomenclature, reflecting the unification of multiple syndromes that are now known to be caused by mutations in the *PTEN* gene. He proposed that

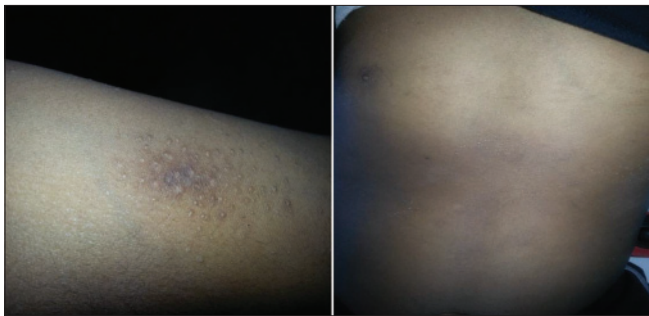

Figure 1: Right arm and front of the chest revealing skin lentiginosis and hyperpigmentation

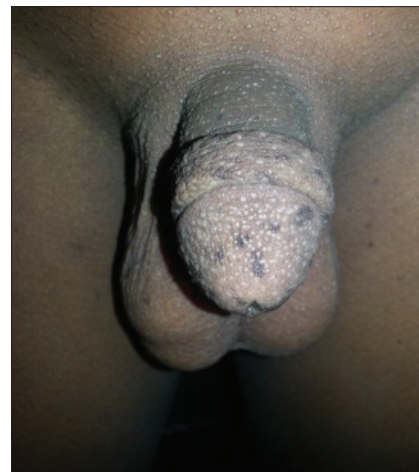

Figure 2: Penile area showing lentiginosis and freckles and hyperpigmentation

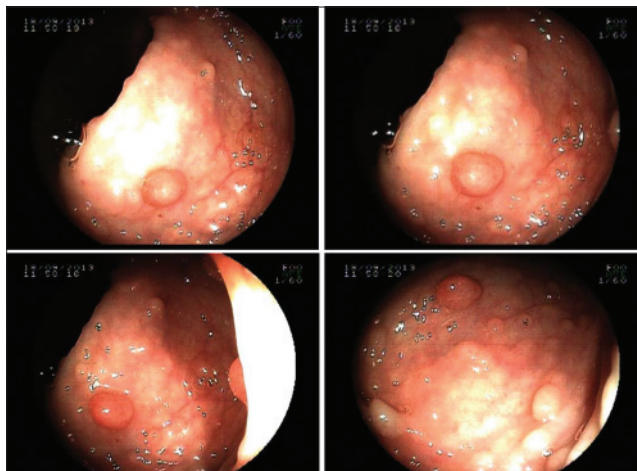


Figure 3: Colonoscopy revealing multiple polyps

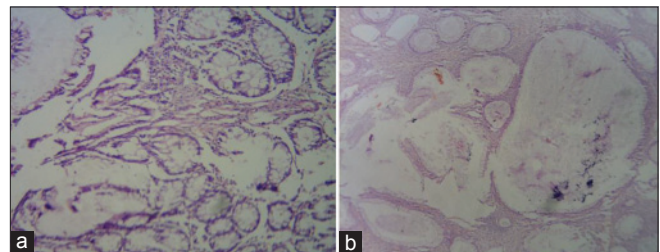


Figure 4: Histopathology of colonic polyp showing mucosa and submucosa with excessive proliferation of glands (a) which are cystic at places (b) and associated with chronic inflammation (hamartomatous polyp)

it be called the PTEN-MATCHS (Macrocephaly, Autosomal dominant, Thyroid disease, Cancer, Hamartomata, Skin abnormalities) syndrome; MATCHS was derived from macrocephaly, autosomal dominance, thyroid disease, cancer, hamartomas, and skin abnormalities.^[2] Marsh suggested that the spectrum of disorders be referred to as PTEN hamartoma tumor syndrome (PHTS).^[3]

BRRS is a rare genetic, autosomal dominant disorder characterized by macrocephaly, multiple hamartomas, lipomas, and dark freckles on the external genitalia, especially glans penis or vulva in females.^[4,5] BRRS is one of the PHTS, a spectrum of disorders caused by mutations in a gene called *PTEN* which includes Cowden syndrome, *PTEN*-related Proteus syndrome, Proteus-like syndrome. Patient can be symptomatic at birth or present late in childhood and presentation may vary from person to person. Treatment depends on symptoms. Due to increased risk of developing cancer in people with the PHTS, cancer surveillance is recommended.^[6]

PTEN gene is a tumor suppressor gene and mutation or deletion in this gene occurs in 60% of cases of BRRS. This gene is located on the long arm (q) of chromosome 10 (10q23.3). The *PTEN* gene regulates the production of an enzyme, protein tyrosine phosphatase, which is thought to mediate cell arrest and apoptosis. *PTEN* mutation leads to uncontrolled cell division with subsequent formation of cancerous and noncancerous tumors. The cancerous tumors include intracranial, thyroid, and testicular tumors. When this syndrome is not associated with mutations or deletions of the *PTEN* gene, the cause of the condition is unknown. In some cases, an affected person inherits the mutation from one affected parent. Other cases result from new mutations in the gene and occur in people with no history of the disorder in their family.^[7,8]

The disorder is very rare with only 50 cases reported in the medical literature. Males are affected more often than females. Majority of infants have increased birth weight and length and about half of affected infants have macrocephaly without enlargement of ventricles. Some patients may have intracranial arteriovenous malformations which can bleed. Growth usually slows during childhood, so affected adults are of normal height and body size. There may be a delay in developmental milestones like speech, sitting, crawling, walking, and low intelligence quotient. Other reported abnormalities include ocular abnormalities like strabismus, widely spaced eyes, and deviation of one eye away from other (exotropia), abnormal elevation of optic disc which appears edematous (pseudopapilloedema) and visual impairment (amblyopia). About a quarter of patients have seizures.^[9-11]

Skin abnormalities include skin pigmentation that looks marbled (cutis marmorata or presence of freckle-like pigmented macules on the penis in males or vulva in females). Some

patients may have coffee-colored spots on the skin (café-au-lait spots) or telangiectasias. In some cases, patients may have musculoskeletal abnormalities like hypotonia, myopathy, hyperextensibility of joints, scoliosis, pectus excavatum, and high arched palate. Myopathy is thought to be due to abnormal accumulation of lipids within the muscles (lipid storage myopathy).^[12,13]

Majority of patients (75-80%) develop benign tumors like growth (hamartomas), which consists of excessive proliferation of mature cells, glands, and tissues that are normally found in the affected area. Other lesions include lipomas and angioliomas that are seen underneath the skin. Some affected individuals also develop hemangiomas and lymphangiomas. Symptoms develop depending upon the size and location of these lesions. Multiple hamartomatous polyps develop in intestines (intestinal polyposis) in about 45% of patients of BRRS and in rare cases over the back of pharynx and or tonsils. Intestinal polyps may cause bleeding, intussusception, or may prolapse via rectum.^[14,15]

There are no definite diagnostic criteria for BRRS, but are based on the presence of the cardinal features of macrocephaly, hamartomatous intestinal polyposis, lipomas, and pigmented macules (lentiginosis) of the glans penis.^[9] Other supportive diagnostic procedures employed includes computed tomography (CT) of brain to reveal normal-sized ventricles, retinoscopy to look for pseudopapilledema, electromyography for myopathy, and molecular genetic testing to look for *PTEN* mutation. Endoscopy and biopsy to look for hamartomatous polyps involving the GI tract. The treatment is directed toward the specific symptoms that are apparent in each individual. Treatment may require multidisciplinary approach which includes pediatricians, surgeons, speech therapists, orthopedician, ophthalmologist, physical therapists, and some others. Hamartomas that cause serious complication (bleeding, obstruction, and intussusception) may require surgical removal or endoscopic management. In cases of *PTEN* gene mutation, a yearly skin check and thyroid ultrasound is recommended. A colonoscopy and biannual renal imaging should begin between the age of 35 and 40 years. Women should perform monthly breast self-examinations and yearly breast screenings as well as transvaginal ultrasounds or endometrial biopsies beginning at the age of 30. Genetic counseling will be of benefit for affected individuals and their families. Family members of affected individuals should also receive periodic clinical evaluations to detect any symptoms and physical characteristics that may be potentially associated with BRRS.

References

1. Hannigan S. National Information Centre for Metabolic Diseases. Inherited Metabolic Diseases: A Guide to 100 Conditions. Radcliffe Publishing; 2007. p. 101.
2. DiLiberti JH, Weleber RG, Budden S. Ruvalcaba-Myre-Smith syndrome:

- A case with probable autosomal dominant inheritance and additional manifestations. *Am J Med Genet* 1983;15:491-5.
3. Marsh DJ, Kum JB, Lunetta KL, Bennett MJ, Gorlin RJ, Ahmed SF, *et al.* Mutation spectrum and genotype phenotype analysis in Cowdens disease and Bannayan-Zonana syndrome, two hamartoma syndromes with germline PTEN mutation. *Hum Mol Genet* 1998;7:507-15.
 4. Buisson P, Leclair MD, Jacquemont S, Podevin G, Camby C, David A, *et al.* Cutaneous lipoma in children: 5 cases with Bannayan-Riley-Ruvalcaba syndrome. *J Pediatr Surg* 2006;41:1601-3.
 5. Gujrati M, Thomas C, Zelby A, Jensen E, Lee JM. Bannayan-Zonana syndrome: A rare autosomal dominant syndrome with multiple lipomas and hemangiomas: A case report and review of literature. *Surg Neurol* 1998;50:164-8.
 6. Eng C. PTEN Hamartoma Tumor Syndrome (PHTS). In: Pagon RA, Adam MP, Bird TD, Dolan CR, Fong CT, Stephens K, editors. Seattle (WA): University of Washington, Seattle; 1993 - 2013. 2001 Nov 29 [Last accessed on 2012 Apr 19].
 7. Zigman AF, Lavine JE, Jones MC, Boland CR, Carethers JM. Localization of the Bannayan-Riley-Ruvalcaba syndrome to chromosome 10q 23. *Gastroenterology* 1997;113:1433-7.
 8. Arch EM, Goodman BK, Van Wesep RA, Liaw D, Clarke K, Parsons R, *et al.* Deletion of PTEN in a patient with Bannayan-Relay-Ruvalcaba syndrome suggests allelism with Cowden disease. *Am J Med Genet* 1997;71:489-93.
 9. Gorlin RJ, Cohen MM Jr, Condon LM, Burke BA. Bannayan-Relay-Ruvalcaba syndrome. *Am J Med Genet* 1992;44:307-14.
 10. Palencia R, Ardura J. Bannayan syndrome with intracranial arteriovenous malformations. *An Esp Pediatr* 1986;25:462-6.
 11. Dvir M, Beer S, Aladjem M. Heredofamilial syndrome of mesodermal hamartomas, macrocephaly and pseudopapilledema. *Pediatrics* 1988;81:287-90.
 12. Powell BR, Budden SS, Buist NR. Dominantly inherited megacephaly, muscle weakness and myoliposis: A carnitine deficient myopathy within the spectrum of the Ruvalcaba-Myhre-Smith syndrome. *J Pediatr* 1993;123:70-5.
 13. Fargnoli MC, Orlow SJ, Semel-Concepcion J, Bologna JL. Clinicopathologic findings in the Bannayan-Riley-Ruvalcaba syndrome. *Arch Dermatol* 1996;132:1214-8.
 14. Klein JA, Barr RJ. Bannayan-Zonana syndrome associated with lymphangiomyomatous lesions. *Pediatr Dermatol* 1990;7:48-53.
 15. Hayashi Y, Ohi R, Tomita Y, Chiba T, Matsumoto Y, Chiba T. Bannayan-Zonana syndrome associated with lipomas, hemangiomas, and lymphangiomas. *J Pediatr Surg* 1992;27:722-3.

How to cite this article: Sodhi JS, Shoukat A, Wani ZA, Ahmed R, Nazir S, Kawoosa ZI. Bannayan-Riley-Ruvalcaba syndrome presenting with recurrent lower gastrointestinal bleed: A Case Report and a review of the literature. *J Dig Endosc* 2013;4:131-4.

Source of Support: Nil, **Conflict of Interest:** None declared.

Announcement

iPhone App



Download
iPhone, iPad
application

FREE

A free application to browse and search the journal's content is now available for iPhone/iPad. The application provides "Table of Contents" of the latest issues, which are stored on the device for future offline browsing. Internet connection is required to access the back issues and search facility. The application is Compatible with iPhone, iPod touch, and iPad and Requires iOS 3.1 or later. The application can be downloaded from <http://itunes.apple.com/us/app/medknow-journals/id458064375?ls=1&mt=8>. For suggestions and comments do write back to us.