

Case Report

Double gastric dieulafoy's lesion treated with endoscopic band ligation

Achanta S. Chalapathi Rao, Surinder S. Rana, Sreekanth Appasani, Deepak K. Bhasin, Kartar Singh

Department of Gastroenterology, Postgraduate Institute of Medical Education and Research, Chandigarh, India

Abstract

Dieulafoy's lesion is an uncommon cause of non-variceal upper gastrointestinal (GI) bleed. They are commonly seen in stomach and are usually single. Rarely, multiple DLs may cause clinically significant GI bleed. We report a rare case of upper GI bleed due to two DL along the lesser curvature of the stomach. Hemostasis was achieved by endoscopic band ligation. Patient did not have further recurrences and was asymptomatic after 2 years.

Key words

Band ligation, dieulafoy's lesion, endoscopy, hematemesis

Introduction

Dieulafoy's lesion (DL) is an uncommon but life threatening cause of gastrointestinal bleed.^[1] Various endoscopic therapeutic techniques like injection therapy, thermal probes, laser therapy, endoscopic band ligation and hemoclippping have decreased the mortality from bleeding DLs.^[1-3] Multiple DLs have been rarely reported^[4,5] and we report a double DLs in stomach that was successfully treated with endoscopic band ligation.

Case Report

A 45-year-old male presented to our emergency services with history of painless massive hematemesis accompanied with melena. There was no history of dyspepsia nor was the patient on non-steroidal anti-inflammatory drugs (NSAID). The patient was a chronic smoker. There were no other co-morbidities. His clinical examination was non-contributory except for presence of pallor. The hematological examination revealed hemoglobin of


4 g/dl with normal platelet count and coagulation profile. The renal function, liver function tests and ultrasound of the abdomen were normal. The patient was resuscitated and blood transfused.

Upper GI endoscopy revealed fresh blood in stomach and duodenum and after washing the stomach, a small elevated protruding vessel with no surrounding ulcer suggestive of a DL was seen at the lesser curvature of the stomach. This lesion was banded with two elastic bands [Figure 1]. Immediate hemostasis was achieved, however, 24 hours later patients rebled with hemodynamic compromise and a repeat endoscopy was performed. The repeat endoscopy revealed that there was no bleed from the banded lesion. However, another DL was seen distal to the previously banded lesion and there was ooze of fresh blood from this lesion [Figure 2]. This lesion was also banded with elastic bands and thereafter there were no further episodes of GI bleed. A repeat endoscopy performed 5 days after last band application, revealed an ulcer with clean base at the site of banding [Figure 3]. The patient is asymptomatic with no recurrence of GI bleed at 2 years of follow-up.

Discussion

DL belongs to an arterial type of vascular abnormality in which submucosal end arteries are abnormally large (caliber-persistent artery). The diameter of the artery at the muscularis mucosae level may be 1-3 mm and is much larger than the diameter of normal arteries at that level. It

Access this article online

Website: www.jdeonline.in	Quick Response Code 
DOI: 10.4103/0976-5042.132440	

Address for correspondence:

Dr. Surinder Singh Rana, Department of Gastroenterology, Postgraduate Institute of Medical Education and Research, Chandigarh - 160 012, India.
E-mail: drsurinderrana@yahoo.co.in

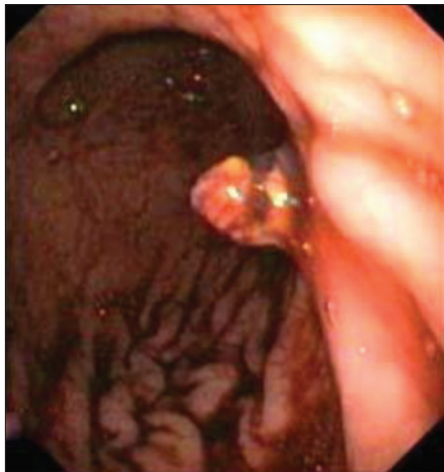


Figure 1: Dieulafoy lesion after endoscopic band ligation

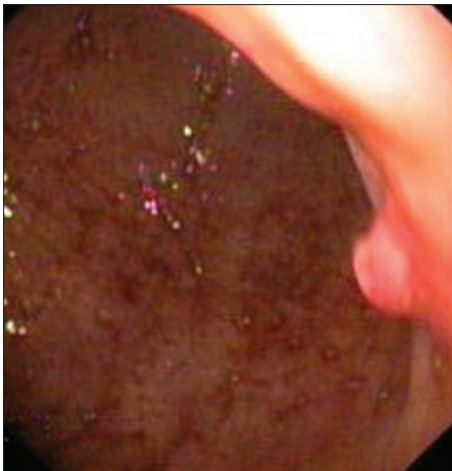


Figure 2: Another dieulafoy lesion distal to the previously banded lesion

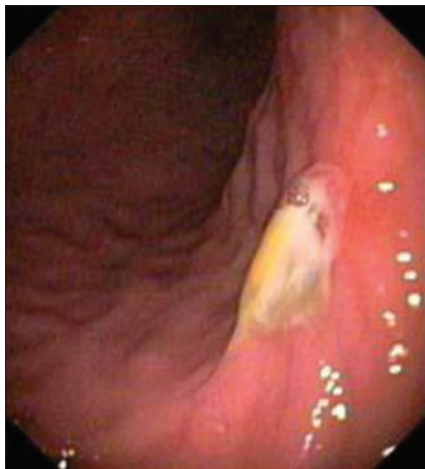

Figure 3: Endoscopy revealing an ulcer at the site of banding

may cause massive bleeding leading to death, and is located in the upper stomach about 5-7 cm below the gastro-esophageal junction in the majority of cases.^[6] Other locations include, esophagus,^[6] distal stomach, duodenum, peri-ampullary region^[7] and large bowel.

These large submucosal arteries may seem to protrude from the mucosa, and the bleeding is caused by tiny erosion overlying the artery. In contrast to peptic ulcer disease, there is no inflammation at the edge of the mucosal defect. Elderly men have an increased incidence of DL in most published series. Comorbidities-particularly cardiovascular disease, hypertension, chronic renal failure, diabetes, and excessive use of alcohol have been described in almost 90% of the patients.^[8]

Endoscopy reveals a reddish-brown protruding spot with small erosion and no ulcer. DL is more easily identified when pulsating or oozing blood. Elective endosonography to examine spots suspected to be DLs is helpful in confirming the diagnosis and, most importantly, guiding the endoscopic treatment.^[9,10] In difficult cases, angiography may be useful when endoscopy fails to identify the lesion, especially in non-gastric sites.

Different therapies for DL were compared in various clinical trials. Chung *et al.*^[11] and Park *et al.*^[12] studied injection method (a mixture of 9 mL 3% NaCl plus 1 mL 1:1000 epinephrine) vs. a mechanical method (clipping or band ligation). Recurrence of bleeding was significantly higher with the injection method (33%) than with banding or clipping (8%). Eventually, no patients of the banding/clipping group were operated upon, while among those treated with the injection method (16.7%) underwent surgery. These studies clearly indicate that mechanical methods (clipping or banding) are significantly better than injection methods alone. Panagiotis Katsinelos *et al.* showed that clip placement was more effective than injection methods in controlling bleeding from DL.^[13]

Several studies have shown that combined therapy using injection of different solutions including epinephrine (1:10,000) or 5% ethanolamine oleate solution followed by thermal coagulation with a heat probe seems to work better, in both the short and long term, than injection therapy alone.^[3,14] The combination of hemoclip hemostasis with ethoxysklerol injection was proven in a recent study to be the most effective method for GI bleeding due to DL.^[15] Angiographic selective embolization of the feeding vessel has been tried, with contradictory results. Surgery is still necessary in some patients in whom severe bleeding cannot be stopped using endoscopy. Wedge resection and not over-sewing of the vessel are recommended. The long-term prognosis of DL is excellent even when treated with endoscopic therapy alone.^[2]

Double DLs are rarely described in the literature. To the best of our knowledge, only two cases of double DLs have been reported in the literature. Katsinelos P *et al.*^[4] have described double DL in stomach, which was successfully treated with hemoclip placement. Park *et al.*^[5] have recently reported a double DL in stomach in a patient with chronic renal failure. Both these lesions were successfully treated with band ligation. We report similar case of double DL in the lesser curvature

of stomach in a middle-aged male, which were successfully treated with band ligation.

Conclusion

DL is an important but rare cause of upper GI bleed. It is commonly seen in stomach along the lesser curvature. Though most of them are single, rarely multiple DL may be seen on careful endoscopic examination. Hemostasis can be effectively achieved through endoscopic band ligation. Recurrence of bleed after an endoscopic hemostasis warrants repeat endoscopic examination to rule out a double DL as in our case.

References

1. Lee YT, Walmsley RS, Leong RW, Sung JJ. Dieulafoy's lesion. *Gastrointest Endosc* 2003;58:236-43.
2. Romaozinho JM, Pontes JM, Lérias C, Ferreira M, Freitas D. Dieulafoy's lesion: Management and long-term outcome. *Endoscopy* 2004;36:416-20.
3. Schmulewitz N, Baillie J. Dieulafoy lesions: A review of 6 years of experience at a tertiary referral center. *Am J Gastroenterol* 2001;96:1688-94.
4. Katsinelos P, Paroutoglou G, Pilpilidis I, Tsolkas P, Papagiannis A, Kapelidis P, *et al.* Double Dieulafoy-like lesion in the stomach. *Surg Endosc* 2003;17:1324.
5. Park EH, Jung YS, Moon W, Park SJ, Rim H. Double Dieulafoy's lesions of the stomach in a patient with chronic renal failure on long-term hemodialysis. *Turk J Gastroenterol* 2010;21:293-6.
6. Abraham P, Mukerji SS, Desai DC, Joshi AG. Dieulafoy lesion in mid-esophagus with esophageal varices. *Indian J Gastroenterol* 2004;23:220-1.
7. Rana SS, Bhasin DK, Gupta R, Yadav TD, Gupta V, Singh K. Periampullary Dieulafoy's lesion: An unusual cause of gastrointestinal bleeding. *JOP* 2010;11:266-9.
8. Norton ID, Petersen BT, Sorbi D, Balm RK, Alexander GL, Gostout CJ. Management of long-term prognosis of Dieulafoy lesion. *Gastrointest Endosc* 1999;50:762-7.
9. Fockens P, Meenan J, van Dullemen HM, Bolwerk CJ, Tytgat GN. Dieulafoy's disease: Endosonographic detection and endosonography-guided treatment. *Gastrointest Endosc* 1996;44:437-42.
10. Folvik G, Nesje LB, Berstad A, Odegaard S. Endosonography-guided endoscopic band ligation of Dieulafoy's malformation: A case report. *Endoscopy* 2001;33:636-8.
11. Chung IK, Kim EJ, Lee MS, Kim HS, Park SH, Lee MH, *et al.* Bleeding Dieulafoy's lesions and the choice of endoscopic method: Comparing the hemostatic efficacy of mechanical and injection methods. *Gastrointest Endosc* 2000;52:721-4.
12. Park CH, Sohn YH, Lee WS, Joo YE, Choi SK, Rew JS, *et al.* The usefulness of endoscopic hemoclippping for bleeding Dieulafoy lesions. *Endoscopy* 2003;35:388-92.
13. Katsinelos P, Paroutoglou G, Mimidis K, Beltsis A, Papaziogas B, Gelas G, *et al.* Endoscopic treatment and follow-up of gastrointestinal Dieulafoy's lesions. *World J Gastroenterol* 2005;11:6022-6.
14. Kasapidis P, Georgopoulos P, Delis V, Balatsos V, Konstantinidis A, Skandalis N. Endoscopic management and long-term follow-up of Dieulafoy's lesions in the upper GI tract. *Gastrointest Endosc* 2002;55:527-31.
15. Cui J, Huang LY, Liu YX, Song B, Yi LZ, Xu N, *et al.* Efficacy of endoscopic therapy for gastrointestinal bleeding from Dieulafoy's lesion. *World J Gastroenterol* 2011;17:1368-72.

How to cite this article: S. A. Rana SS, Appasani S, Bhasin DK, Singh K. Double gastric dieulafoy's lesion treated with endoscopic band ligation. *J Dig Endosc* 2013;4:135-7.

Source of Support: Nil, **Conflict of Interest:** None declared.

New features on the journal's website

Optimized content for mobile and hand-held devices

HTML pages have been optimized of mobile and other hand-held devices (such as iPad, Kindle, iPod) for faster browsing speed.

Click on **[Mobile Full text]** from Table of Contents page.

This is simple HTML version for faster download on mobiles (if viewed on desktop, it will be automatically redirected to full HTML version)

E-Pub for hand-held devices

EPUB is an open e-book standard recommended by The International Digital Publishing Forum which is designed for reflowable content i.e. the text display can be optimized for a particular display device.


Click on **[EPub]** from Table of Contents page.

There are various e-Pub readers such as for Windows: Digital Editions, OS X: Calibre/Bookworm, iPhone/iPod Touch/iPad: Stanza, and Linux: Calibre/Bookworm.

E-Book for desktop

One can also see the entire issue as printed here in a 'flip book' version on desktops.

Links are available from Current Issue as well as Archives pages.

Click on  View as eBook