

## Case Report

# An unusual case of hematemesis: Spontaneous reno-duodenal fistula

Vincenzo De Francesco, Franca Castellucci<sup>1</sup>, Silverio Balzano<sup>1</sup>, Angelo Zullo<sup>2</sup>

Departments of Gastroenterology and Digestive Endoscopy and <sup>1</sup>Radiology, Riuniti Hospitals, Foggia, <sup>2</sup>Department of Gastroenterology and Digestive Endoscopy, Nuovo Regina Margherita Hospital, Rome, Italy

## Abstract

Different diseases may cause gastrointestinal bleeding. A fistula infrequently manifest with severe intestinal bleeding, when excluding those directly involving vascular structures. We described a case of upper digestive bleeding by a spontaneous renal-duodenal fistula in the patient with kidney cancer. Bleeding was successfully stopped by transarterial embolization.

## Key words

Fistula, kidney cancer, treatment, upper gastrointestinal bleeding

## Introduction

Hematemesis is an alarm symptom requiring a prompt upper endoscopy. Different lesions of the esophagus, stomach and duodenum may manifest with such a symptom. The most frequent causes include gastro-esophageal varices rupture, Mallory–Weiss lesions, bleeding peptic ulcers or erosions, Dieulafoy lesions, and tumors.<sup>[1]</sup> By excluding those involving vascular structures,<sup>[2]</sup> a fistula infrequently causes a severe gastrointestinal bleeding.<sup>[3]</sup> Abdominal fistulas generally develop in Crohn's disease patients, following abdominal surgery and more rarely, in patients with cancer. Fistulization between a renal cancer and upper digestive tract may develop following either a percutaneous ablation<sup>[4]</sup> or a biological treatment (i.e., bevacizumab, sunitib).<sup>[5]</sup> Spontaneous reno-duodenal fistula is a very rare complication of either chronic inflammatory diseases of the kidney or peptic ulcer disease.<sup>[3,6]</sup> We report a rare case of a severe hematemesis due to a spontaneous reno-duodenal fistula in a patient with kidney cancer.

## Case Report

A 78-year-old man was admitted in the emergency department

because of sudden episodes of hematemesis. At entry, blood pressure values of 95/50 mm Hg, tachycardia and severe anemia (hemoglobin: 5.2 g/dL) were detected suggesting a hemorrhagic shock. The patient underwent resuscitation procedures, with fluid and blood transfusions, reaching vital stability. An upper gastrointestinal endoscopy was performed revealing an active arterial bleeding in the second portion of the duodenum originating from a fistula [Figure 1]. The month before, the patient was hospitalized because of a 6-month history of right-sided abdominal pain. Computed tomography (CT) revealed a tumoral mass in the right kidney, 15 cm in diameter, infiltrating the right ureter, the inferior cava vein, iliopsoas muscle, and with close adherence to the duodenal wall. Necrotic areas, inflammatory changes, and foci of air in tumoral mass were also present [Figure 2a]. This finding suggested a fistula between the small bowel and the tumoral mass, which was confirmed by oral contrast (gastrographin) concentration in renal mass [Figure 2b]. He was still performing oncologic evaluation, and no treatment was started yet.

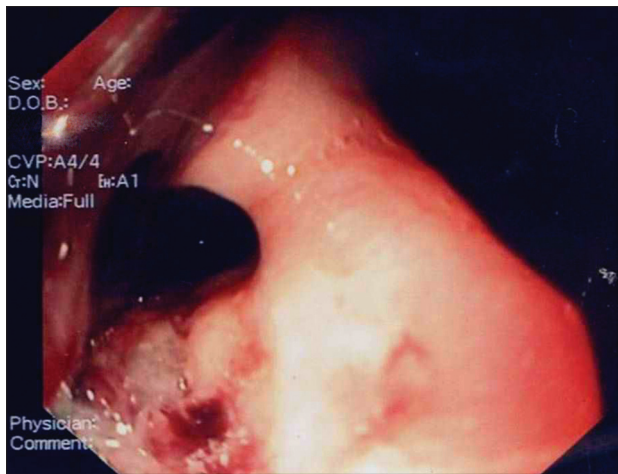
Based on the endoscopic finding and the previous CT feature, we decided for a radiological approach. The angiographic procedure confirmed the renal mass with necrotic areas and irregular vascular pattern. An active bleeding originating from a branch of gastroduodenal arteria in close contact to reno-duodenal fistula was observed [Figure 2c], so that an embolization by Contour was performed [Figure 2d]. In addition, the embolization by Contour and spiral stent was extended to the main branch of right renal arteria, aiming to treat the kidney neoplasm. Hemostasis was successfully achieved, and the patient was discharged 7 days later.

### Access this article online

<b>Website:</b> <a href="http://www.jdeonline.in">www.jdeonline.in</a>	<b>Quick Response Code</b> 
<b>DOI:</b> 10.4103/0976-5042.141936	

### Address for correspondence:

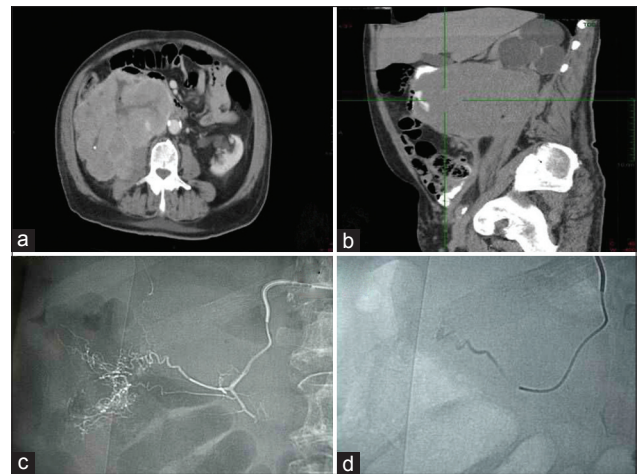
Dr. Vincenzo De Francesco, AOU Ospedali Riuniti, Viale Pinto, 71100 Foggia, Italy. E-mail: [vdefrancesco@alice.it](mailto:vdefrancesco@alice.it)



**Figure 1:** Duodenal fistula with active bleeding in the second portion of duodenum

## Discussion

Hematemesis in an elderly patient may be caused by different diseases, including gastro-esophageal varices rupture, peptic ulcer disease, vascular abnormalities, and cancer.<sup>[1]</sup> When excluding that fistula directly involving vascular structures, such as aneurisms,<sup>[2]</sup> upper or lower intestinal bleeding infrequently depends on such a cause. Particularly, intestinal bleeding from a renal-digestive fistula has been rarely reported, generally following a percutaneous ablative procedures for renal neoplasms. Indeed, two cases of hematochezia from colon-renal fistula were reported, occurring after percutaneous cryoablation or radio-frequency-ablation for renal cell carcinoma.<sup>[3]</sup> To our knowledge, only one case of upper gastrointestinal tract bleeding in a patient with reno-duodenal fistula was reported.<sup>[7]</sup> However, in this patient an esophageal ulcer was detected at upper endoscopy as a potential cause of bleeding, whilst the reno-duodenal fistula in the third portion of the duodenum was detected only at the successive radiographic gastrointestinal series. Therefore, our report seems to be the first one describing a spontaneous, massive gastrointestinal bleeding from reno-duodenal fistula in the patient with kidney cancer. A fistula between upper digestive tract and the right kidney appear to be more frequent due to the strict anatomic contact with the duodenum. Transarterial embolization is suggested an effective approach to managing patients with hemorrhagic urological emergencies, especially those with high surgical risk.<sup>[8]</sup> Such a therapeutic approach was successfully performed in our patient, confirming that transarterial embolization is a safe and effective therapeutic option to treat a bleeding reno-duodenal fistula. Since, a fistulizing effect of antiangiogenesis targeted/biological



**Figure 2:** Tumoral mass of right kidney with necrotic areas and foci of air (a). Oral contrast enhancement (gastrografin) from the second duodenal portion to renal mass trough a fistula (b). Selective angiography of the gastroduodenal arteria branch in close association to reno-duodenal fistula (c). Coil embolization with bleeding arrest (d)

therapy in renal carcinoma patients has been recently described,<sup>[5]</sup> it could be foreseeable that similar cases will be encountered in the future.

## References

1. Feinman M, Haut ER. Upper gastrointestinal bleeding. *Surg Clin North Am* 2014;94:43-53.
2. Millar A, Rostom A, Rasuli P, Saloojee N. Upper gastrointestinal bleeding secondary to an aberrant right subclavian artery-esophageal fistula: A case report and review of the literature. *Can J Gastroenterol* 2007;21:389-92.
3. Wysocki JD, Joshi V, Eiser JW, Gil N. Colo-renal fistula: An unusual cause of hematochezia. *World J Gastrointest Pathophysiol* 2010;1:106-8.
4. de Arruda HO, Goldman S, Andreoni C, Maia RS, Szejnfeld J, Ortiz V. Renoduodenal fistula after renal tumor ablation with radiofrequency. *Surg Laparosc Endosc Percutan Tech* 2006;16:342-3.
5. Chow H, Jung A, Talbott J, Lin AM, Daud AI, Coakley FV. Tumor fistulization associated with targeted therapy: Computed tomographic findings and clinical consequences. *J Comput Assist Tomogr* 2011;35:86-90.
6. Atalla MA, Tajkarimi K, Vinh D, Guarnaccia SP. Pyeloduodenal fistula. *J Urol* 2009;181:2733-4.
7. Chen CH, Cheng HL, Tong YC, Pan CC. Spontaneous pyeloduodenal fistula: An unusual presentation in advanced renal transitional cell carcinoma. *Urology* 2002;60:345.
8. Krüger K, Siakavara E. Coil embolization for treatment of vascular complications after nephron-sparing surgery. *Acta Radiol* 2012;53:551-5.

**How to cite this article:** Francesco VD, Castellucci F, Balzano S, Zullo A. An unusual case of hematemesis: Spontaneous reno-duodenal fistula. *J Dig Endosc* 2014;5:37-8.

**Source of Support:** Nil, **Conflict of Interest:** None declared.