

# Malignant duodeno-colic fistula

Debasis Misra, Girish Kumar Pati, Bijay Misra, Ayaskanta Singh, Sanjib Kar, Manas Kumar Panigrahi, Shivaram Prasad Singh, Omprakash Agrawal<sup>1</sup>, Chudamani Meher<sup>1</sup>

Department of Gastroenterology, S.C.B. Medical College, <sup>1</sup>Beam Diagnostics Centre, Cuttack, Odisha, India

## Abstract

Colo-duodenal fistula is a rare complication of gastro-intestinal malignancy and inflammatory bowel disease. The fistula often results in diarrhea and vomiting with dramatic weight loss. Vomiting may be feculent or truly fecal associated with foul smelling eructation. We present an unusual case of colonic carcinoma, where a 61-year-old female patient presented with pain abdomen and vomiting secondary to a malignant colo-duodenal fistula near the hepatic flexure. Ultrasonography showed a mass in the hepatic flexure area, and invasive adenocarcinoma was confirmed on histology from biopsy obtained during colonoscopy. Coloduodenal fistulae from colonic primaries are rare, but early diagnosis may allow curative surgery.

## Key words

Adenocarcinoma colon, coloduodenal fistula, gastrointestinal fistula

## Introduction

Patients with colorectal cancer usually present in the sixth to eight decade with symptoms such as change of bowel habit, bleeding per annum, passage of mucus and abdominal discomfort. Anorexia and weight loss may occur if the tumor mass is large or if it becomes disseminated.<sup>[1]</sup> We present an unusual case of colorectal carcinoma, where the patient presented with pain abdomen and vomiting secondary to a malignant colo-duodenal fistula near the hepatic flexure.

## Case Report

A 61-year-old female presented to the hospital with 10 days history of pain in peri umbilical area that aggravated postprandially and was associated with vomiting. Vomiting consisted of partially digested food but occasionally it was feculent and associated with foul smelling eructations. There was no diarrhea or symptoms and signs of gastrointestinal

blood loss. She also complained of anorexia. She was pale with a hemoglobin level of 6.0 g%. Her upper gastrointestinal endoscopy showed a deformed pyloroduodenal complex with a fistulous opening seen in the posterior wall of 1<sup>st</sup> part of the duodenum. Biopsy was taken from the lesion. Ultrasonography revealed a hypoechoic mass of diameter 5.5 cm in the hepatic flexure and proximal transverse colon region. There was no enlarged abdominal node or hepatic metastasis. Colonoscopy showed a concentric friable nodular growth around the hepatic flexure with considerable narrowing of lumen. Histopathology of endoscopic biopsy revealed moderately differentiated invasive adenocarcinoma of the colon. She was thereafter referred for surgery. However the patient was reluctant for surgery and lost to follow-up.

## Discussion

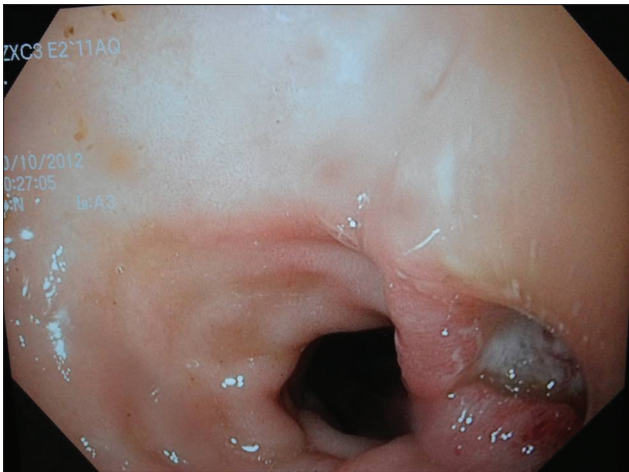Despite the anatomic proximity of the duodenum and colon, fistula formation is quite rare. One of the first reports of a duodenocolic fistula was by Haldane in 1862.<sup>[2]</sup> In a report of 1,400 cases of right colon cancer way back in 1947 there were only two cases of malignant duodenocolic fistulae.<sup>[3]</sup> Benign lesions causing fistula are even more rarely found. The first fully documented case of benign duodenocolic fistula was reported by Sanderson in 1863 that was due to ruptured duodenal diverticulum.<sup>[4]</sup> Benign causes reported include benign duodenal ulceration,<sup>[5]</sup> Crohn's disease,<sup>[6]</sup> gallstones,<sup>[7]</sup> a pancreatic pseudocyst rupture<sup>[8]</sup> and stent migration.<sup>[9]</sup> Other causes are tuberculous disease, typhoid ulceration

### Access this article online

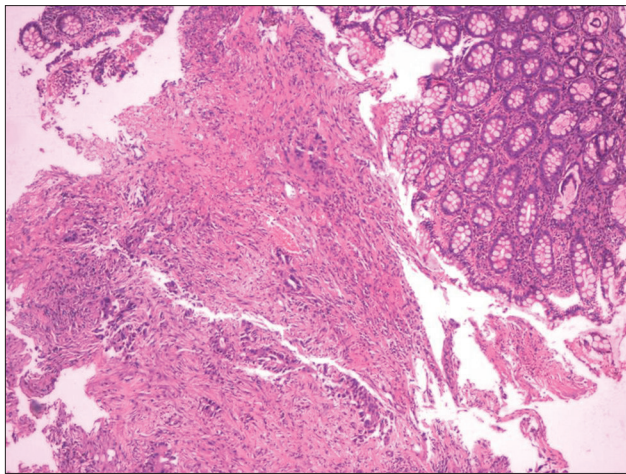
<b>Website:</b> www.jdeonline.in	<b>Quick Response Code</b> 
<b>DOI:</b> 10.4103/0976-5042.144833	

### Address for correspondence:

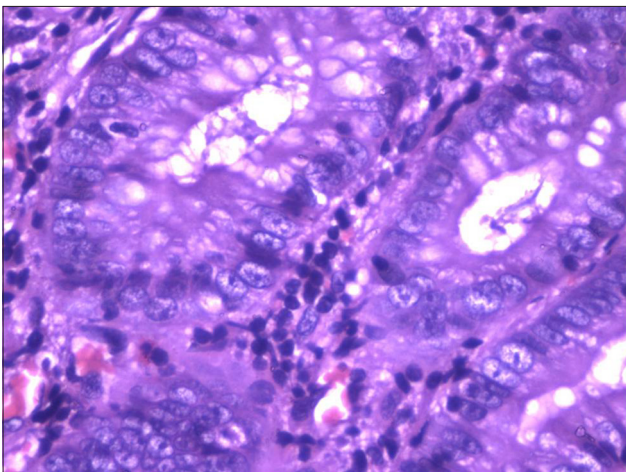
Dr. Shivaram Prasad Singh, Plot No: 1362/B, Sector 6, Markat Nagar, Abhinava Bidanasi, Cuttack - 753 014, Odisha, India. E-mail: sudhasingh@sify.com



**Figure 1:** Endoscopic picture of duodenocolic fistula



**Figure 2:** Low power histopathology slide of colonic adenocarcinoma



**Figure 3:** High power view of colonic adenocarcinoma(HP slide)

and nonspecific inflammatory lesions. Spontaneous colo-duodenal fistulae have also been reported.<sup>[10]</sup>

Malignant causes other than colonic carcinoma, include carcinoma of the gall bladder,<sup>[11]</sup> duodenum<sup>[12]</sup> and even of the

esophagus.<sup>[13]</sup> In most instances of duodeno-colic fistula, the second part of the duodenum is involved.<sup>[13]</sup> The regions just proximal and distal to the hepatic flexure are the usual sites of large bowel fistula.

Patients with malignant duodenal fistulae can present with symptoms due to the primary lesion or the fistula or from metastatic disease. The fistula often results in diarrhea and vomiting with dramatic weight loss. Upper abdominal pain is usually present. The diarrhea relates to colonic bacterial contamination of the upper intestines<sup>[14]</sup> and to the irritating effects on the colonic mucosa by duodenal bile salts,<sup>[15]</sup> rarely it can be due to mechanical short bowel. Vomiting may be feculent or truly fecal and eructation foul smelling.

Radiology is useful to delineate the fistula. Most reports suggest barium enema is more likely to delineate the fistula than a barium meal study.<sup>[16]</sup> Computed tomography scan is of great value in assessing metastatic spread as well as the extent of local invasion by the primary neoplasm. Treatment consists of resection of the tumor and the fistula en bloc. Earlier the two-stage procedure consisting of defunctionalization of the fistula by gastrojejunostomy and ileotransverse colostomy as the first stage, followed by tumor resection and pancreaticoduodenectomy was done.<sup>[17]</sup> Now-a-days, the one-stage procedure of right hemicolectomy with partial duodenectomy and primary closure of the duodenal wall defect is more commonly adopted, because of advances in perioperative intensive care and availability of total parenteral nutrition.<sup>[18]</sup> Results comparing between one-stage and two-stage procedure were similar.<sup>[19,20]</sup> In the review of Izumi *et al.*, the highest 1-year survival was achieved by colectomy with the pancreatoduodenectomy (Whipple procedure) due to as adequate regional lymph node dissection.<sup>[21]</sup> The survival of patients with malignant colo-duodenal fistula is usually <12 months when treated with palliative operations such as ileotransverse colostomy with gastrojejunostomy [Figures 1-3].<sup>[3,22]</sup>

## Conclusion

Colo-duodenal fistulae from primary colonic neoplasms are rare, but it is important to identify these preoperatively as en bloc resection with curative intent may well necessitate a pancreaticoduodenectomy.

## References

1. Mortensen NJ, Nicholls RJ, Northover JM, Williams NS. The colon, rectum and anus. In: Burnand KG, Young AE, editors. Companion of Surgical Studies. 2<sup>nd</sup> ed. London: Churchill Livingstone; 1999. p. 813-76.
2. Haldane DR. Case of cancer of the caecum, accompanied by with caecoduodenal and caecocolic fistulae. *Edinb Med J* 1862; 7:624-9.
3. Calmenson M, Black BM. Surgical management of carcinoma of the right portion of the colon with secondary involvement of the duodenum, including duodenocolic fistula; data on eight cases. *Surgery* 1947;21:476-81.

4. Sanderson F. Duodenocolic fistula. *Trans Path Soc Lond* 1863;14:173-5.
5. Guzzetti A. A case of duodenocolic fistula caused by duodenal ulcer. *Chir Ital* 1981;33:934-7.
6. Pichney LS, Fantry GT, Graham SM. Gastrocolic and duodenocolic fistulas in Crohn's disease. *J Clin Gastroenterol* 1992;15:205-11.
7. Edmunds PK, Havard C. Duodeno-colic fistula due to gall-stones. *Br J Surg* 1961;49:253-5.
8. Urakami A, Tsunoda T, Hayashi J, Oka Y, Mizuno M. Spontaneous fistulization of a pancreatic pseudocyst into the colon and duodenum. *Gastrointest Endosc* 2002;55:949-51.
9. Pathak KA, de Souza LJ. Duodenocolic fistula: An unusual sequela of stent migration. *Endoscopy* 2001;33:731.
10. Torrance B, Jones C. Three cases of spontaneous duodeno-colic fistula. *Gut* 1972;13:627-30.
11. Calvert DG, Medhurst GA. Fistula formation between the duodenum and colon. A report of three cases and a review of the condition. *Br J Surg* 1960;48:136-9.
12. Ergin MA, Alfonso A, Auda SP, Waxman M. Primary carcinoma of the duodenum producing a malignant duodenocolic fistula. *Dis Colon Rectum* 1978;21:408-12.
13. Reissman P, Steinhagen RM, Enright PF. Duodenocolic fistula: An unusual presentation of esophageal squamous cell carcinoma. *Mt Sinai J Med* 1992;59:75-8.
14. Hershenson LM, Kirsner JB. Duodenocolic fistula. *Gastroenterology* 1951;19:864-73.
15. Xenos ES, Halverson JD. Duodenocolic fistula: Case report and review of the literature. *J Postgrad Med* 1999;45:87-9.
16. Soulsby R, Leung E, Williams N. Malignant colo-duodenal fistula; case report and review of the literature. *World J Surg Oncol* 2006;4:86.
17. Janes RM, Mills JR. Malignant duodenocolic fistula-report of a case treated successfully by mass resection. *Can J Surg* 1959;3:91-2.
18. Steer ML, Glotzer DJ. Colonic exclusion bypass principle: Its use in the palliative treatment of malignant duodenocolic and gastrocolic fistulas. *Arch Surg* 1980;115:87-9.
19. Ellis H, Morgan MN, Wastell C. Curative surgery in carcinoma of the colon involving duodenum. A report of 6 cases. *Br J Surg* 1972;59:932-5.
20. Chang AE, Rhoads JE. Malignant duodenocolic fistulas: A case report and review of the literature. *J Surg Oncol* 1982;21:33-6.
21. Izumi Y, Ueki T, Naritomi G, Akashi Y, Miyoshi A, Fukuda T. Malignant duodenocolic fistula. Report of a case and considerations for operative management. *Surg Today* 1993;23:920-5.
22. Welch JP, Warshaw AL. Malignant duodenocolic fistulas. *Am J Surg* 1977;133:658-61.

**How to cite this article:** Misra D, Pati GK, Misra B, Singh A, Kar S, Panigrahi MK, Singh SP, Agrawal O, Meher C. Malignant duodeno-colic fistula. *J Dig Endosc* 2014;5:75-7.

**Source of Support:** Nil, **Conflict of Interest:** None declared.