Published online: 2019-09-26

Case Report

A hairy intruder into colon

Umesh Jalihal, Prithvipriyadarshini Shivalingaiah, Dheena Shurane, Kiran Reddyvari

Department of Gastroenterology, M. S. Ramaiah Memorial Hospital, Bengaluru, Karnataka, India

Abstract

Ovarian dermoid cysts are benign tumors, which develop from totipotent germ cells and grow into mature tissue types consisting of hair, teeth, fat and neural tissue. Ovarian dermoid cyst fistulizing to the sigmoid is rare and presenting with bleeding per rectum is extremely rare. We present a case of middle-aged woman with bleeding per rectum who had the right adnexal tumor fistulating to sigmoid.

Key words

Bleeding per rectum, colonoscopy, ovarian dermoid cyst, sigmoid colon

Introduction

The word "teratoma," is derived from the Greek word "teraton" meaning monster. The term "teratoma" was used by Virchow in 1863 and later the term "dermoid cyst" was coined by Leblanc in 1831. Both are used interchangeably.[1]

Arising from totipotential cells, these tumors are either in midline or paraxial. After sacrococcygeal teratomas (57%), gonads (29%) are the second most common site. Mature cystic teratomas comprise 10–20% of all ovarian neoplasms and they mostly occur in patients less than 20 years of age.[1]

Ovarian dermoid cysts develop from totipotent germ cells and grow into mature tissue types consisting of hair, teeth, fat and neural tissue.[2] Although mostly asymptomatic, complications such as torsion, rupture, malignant transformation and perforation into peritoneum or hollow viscous such as bowel and bladder occur in about 2% of the cases, Bowel penetration or fistulation may involve ileum, sigmoid and rectum.[2-4] We present a case of middle aged women with bleeding per rectum who had a right adnexal tumor fistulising to sigmoid.

Access this article online	
Website: www.jdeonline.in	**Quick Response Code**
DOI: 10.4103/0976-5042.150667	

Case Report

A 44-year-old nonpregnant woman underwent a colonoscopy to evaluate the cause of bleeding per rectum of 3 months duration. A 2 cm irregular polyp appearing as a grayish blue lesion with tufts of long hair on the surface was noted in the sigmoid colon [Figure 1]. It dipped into a pseudo diverticular cavity, indicating a possible exophytic component.

Computed tomography of abdomen and pelvis showed a large mass measuring 8.3 cm × 7.0 cm in the right adnexa. It was composed of fat and areas of calcification with small air pockets around the mass, and appeared to communicate with a pseudocavity in the right lateral aspect of sigmoid colon [Figure 2].

Patient underwent hysterectomy, bilateral salphingooopherectomy, adnexectomy, wedge resection of sigmoid and wound closure. Postoperative period was uneventful.

Gross and histopathology examination of right adnexal mass confirmed presence of a dermoid cyst presumably arising from the ovary.

On cut section, yellow pad of fat inside the tumor was conspicuous [Figure 3].

On Histopathological examination, squamous, columnar and respiratory ciliated epithelium, fat, cartilage and bone marrow elements were noted [Figures 4-6].

Address for correspondence:
Dr. Umesh Jalihal, Department of Gastroenterology, M. S. Ramaiah Memorial Hospital, Bengaluru - 560 054, Karnataka, India. E-mail: drumeshj@yahoo.com

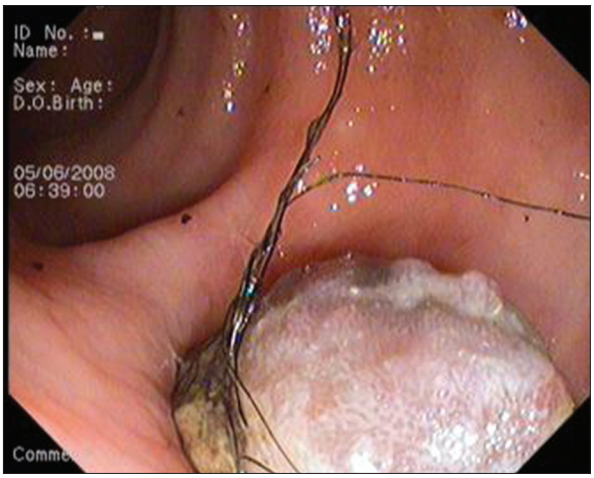

Figure 1: Colonoscopic view showing a single, greyish-blue, irregular polyp with tufts of long hair in sigmoid colon

Figure 2: Computed tomography pelvis showing a large mass measuring 8.3 cm × 7 cm in right adnexa communicating with pseudo cavity in right lateral aspect of sigmoid colon

Figure 3: Gross appearance of resected dermoid cyst on cut section showing yellow pad of fat

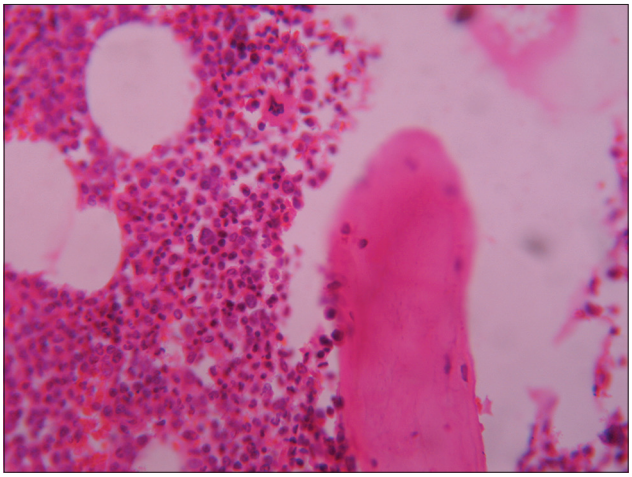

Figure 4: Histopathological examination: Microscpic view of cut section of dermoid cyst showing ciliated columnar epithelium

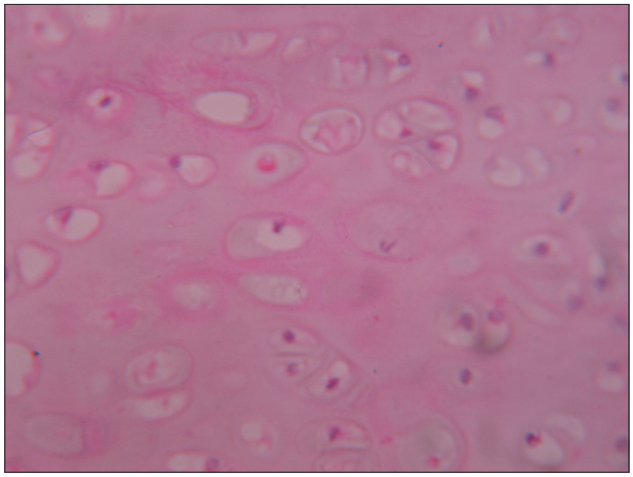

Figure 5: Microscopic view showing cartilage on histopathological examination of dermoid cyst

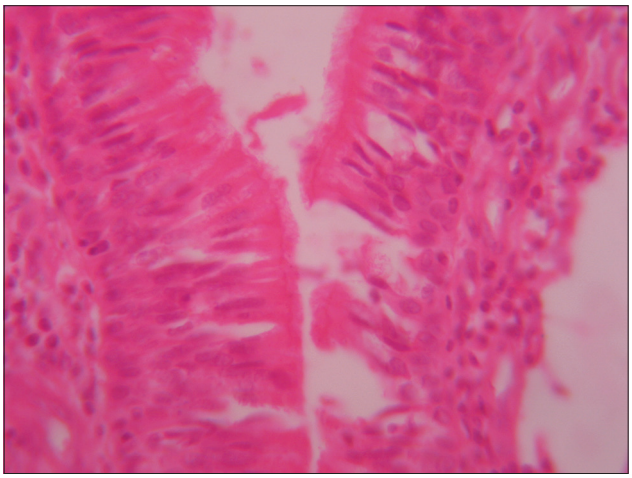

Figure 6: Histopathological examination of dermoid cyst showing bone and marrow components

Discussion

Primary colonic dermoid cysts are not reported and are a result of fistulation from ovary.[2-4] Silent fistulation and later on presenting as bleeding per rectum as reported in this case is rare. Ovarian dermoids complicated by bowel involvement reported in the literature usually have presented with bleeding per

vagina,[5] pain abdomen and rarely with passage of hair[4,6] and blood in stools.[7]

Subsequently, dermoid tumors are picked up either on evaluation with imaging or during surgery. On plain X-ray or barium studies presence of teeth and bony structures should raise the suspicion of these tumors.[5,8] In this case, there were no primary gynecological symptoms. Bleeding per rectum was the leading symptom. Clear demarcation of tumor from rest of the mucosa, greyish blue color and presence of hair noted on colonoscopy, prompted us to think of dermoid cystic lesion. Otherwise, it would have been difficult to diagnose preoperatively. Instead of catastrophic rupture and contamination of the peritoneum from cyst and bowel contents, slow contained fistulation of sigmoid is rather surprising. It is hypothesized that cyst wall coming in contact with bowel results in inflammation, leakage of cyst fluid, adhesions and necrosis, later resulting in fistulation.[2-4]

Conclusion

This case should alert the clinician to be cautious and aware of such a lesion while performing colonoscopic evaluation. If carefully looked for, preoperative diagnosis of recto-ovarian dermoid cyst though rare, may be possible as shown in this case.

References

1. Comerci JT Jr, Licciardi F, Bergh PA, Gregori C, Breen JL. Mature cystic teratoma: A clinicopathologic evaluation of 517 cases and review of the literature. Obstet Gynecol 1994;84:22-8.
2. Wakelin SJ, Monaghan H, Kelly D, Browning G. An unusual case of small bowel obstruction. Internet J Gastroenterol 2007;6.
3. Cebesoy FB, Baskonus I, Mete A, Kutlar I, Aybasti N. Benign ovarian dermoid cyst complicated with rectal fistula formation: An unusual case. Arch Gynecol Obstet 2009;279:179-81.
4. Sasaki H, Nagasako K, Harada M, Kobayashi S, Uetake K. Benign cystic teratoma of the ovary with rupture into the rectum: Report of a unique rectal tumor. Dis Colon Rectum 1979;22:248-51.
5. Fujita K, Akiyama N, Ishizaki M, Tanaka S, Ohsawa K, Sugiyama H, *et al.* Dermoid cyst of the colon. Dig Surg 2001;18:335-7.
6. Goldenberg NJ. Dermoid perforation of the colon. Gastrointest Radiol 1978;3:221-2.
7. Landmann DD, Lewis RW. Benign cystic ovarian teratoma with colorectal involvement. Report of a case and review of the literature. Dis Colon Rectum 1988;31:808-13.
8. Mitui AH, Fujita R, Sugata F, Kienebuchi M, Suzuki K, Sagawa F. A case of ovarian dermoid cyst with malignant transformation perforated into the rectosigmoid colon and small intestine. Endoscopy 1983;15:331-3.

How to cite this article: Jalihal U, Shivalingaiah P, Shurane D, Reddyvari K. A hairy intruder into colon. J Dig Endosc 2014;5:159-61.

Source of Support: Nil, **Conflict of Interest:** None declared.

Author Help: Reference checking facility

The manuscript system (www.journalonweb.com) allows the authors to check and verify the accuracy and style of references. The tool checks the references with PubMed as per a predefined style. Authors are encouraged to use this facility, before submitting articles to the journal.

- The style as well as bibliographic elements should be 100% accurate, to help get the references verified from the system. Even a single spelling error or addition of issue number/month of publication will lead to an error when verifying the reference.
- Example of a correct style
  Sheahan P, O'leary G, Lee G, Fitzgibbon J. Cystic cervical metastases: Incidence and diagnosis using fine needle aspiration biopsy. Otolaryngol Head Neck Surg 2002;127:294-8.
- Only the references from journals indexed in PubMed will be checked.
- Enter each reference in new line, without a serial number.
- Add up to a maximum of 15 references at a time.
- If the reference is correct for its bibliographic elements and punctuations, it will be shown as CORRECT and a link to the correct article in PubMed will be given.
- If any of the bibliographic elements are missing, incorrect or extra (such as issue number), it will be shown as INCORRECT and link to possible articles in PubMed will be given.